

humerus; diaphseal

♂ 59 yo pilot

1st referral: 11.05.2011

HPI:

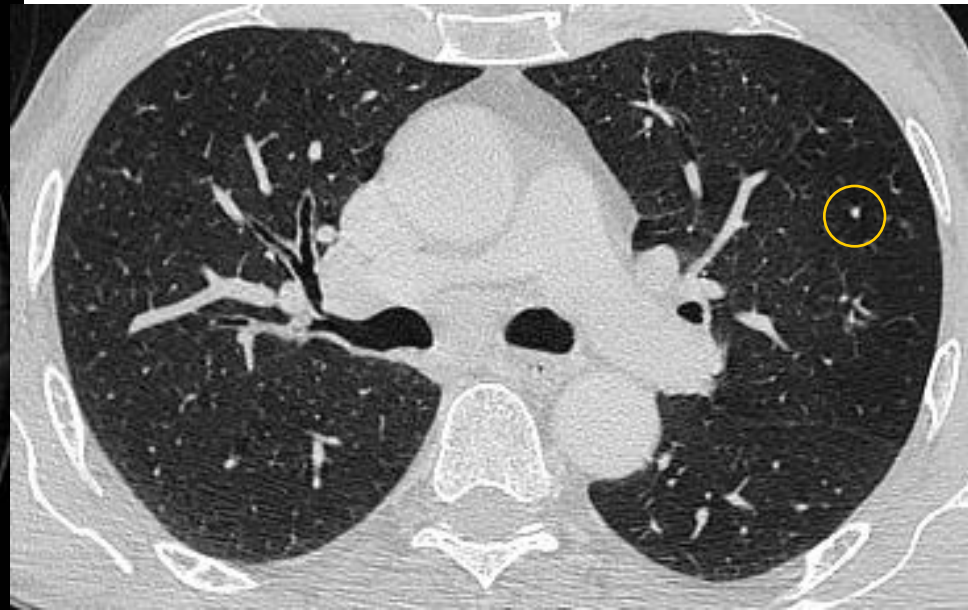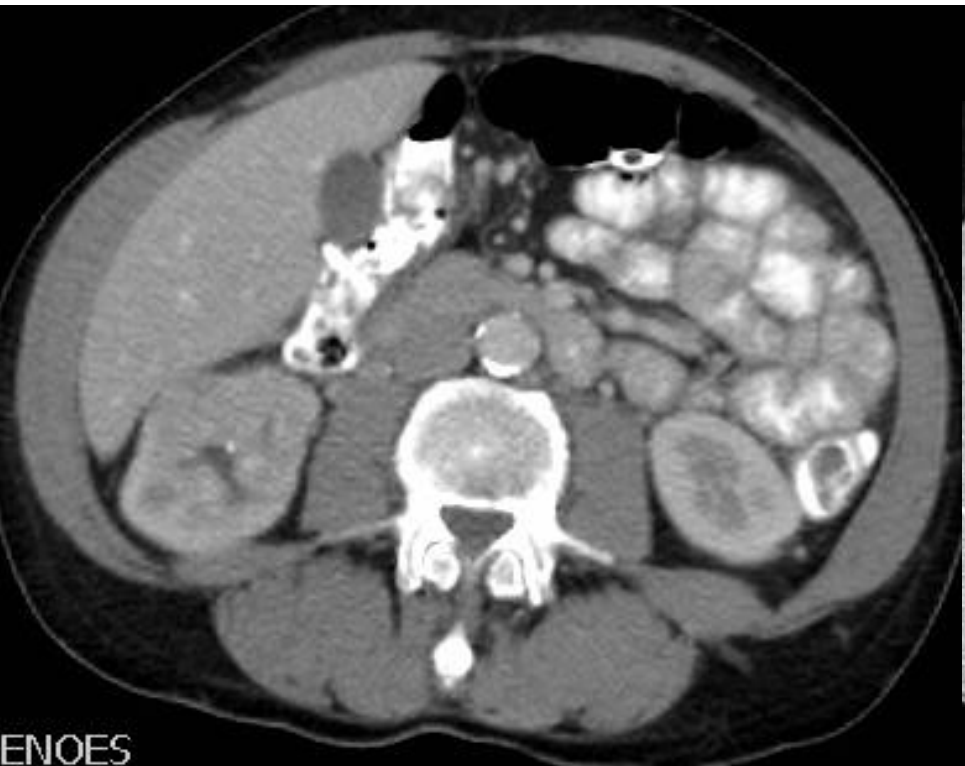- Since January 2011 slight pain right femur and left upper arm
- Humerus shaft fracture (04.03.2011) while sledding
- retrograd nailing (05.03.2011) in Reutte Hospital (no histology)
- no nephrectomy till now
- radiotherapy of femur and humerus

PMH:

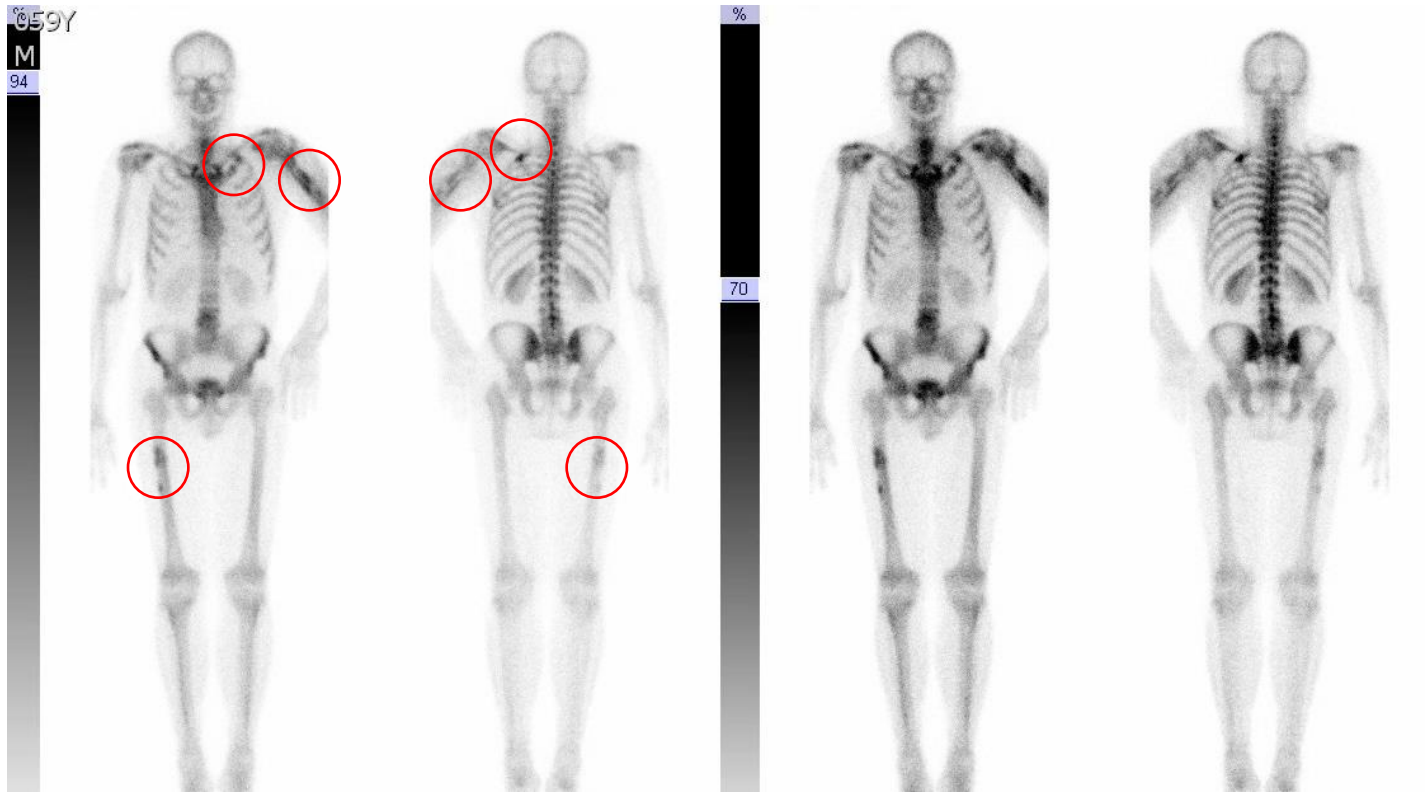
-none

humerus; diaphyseal

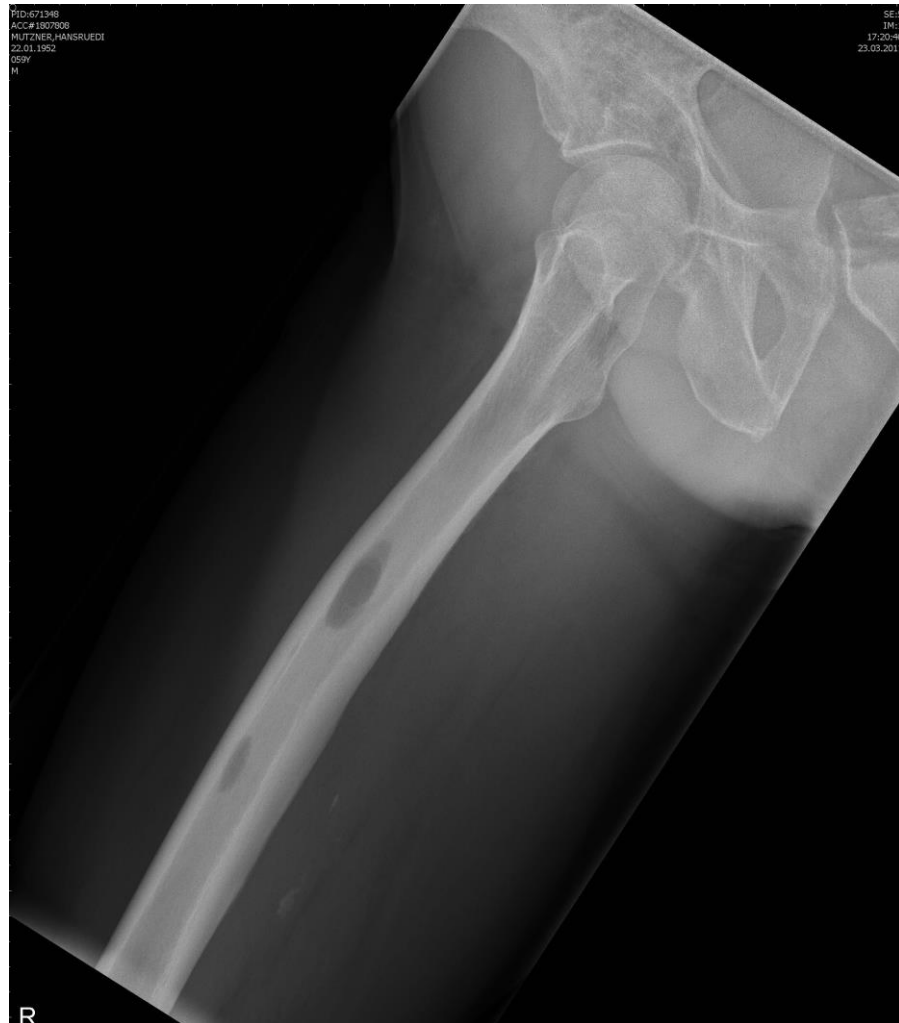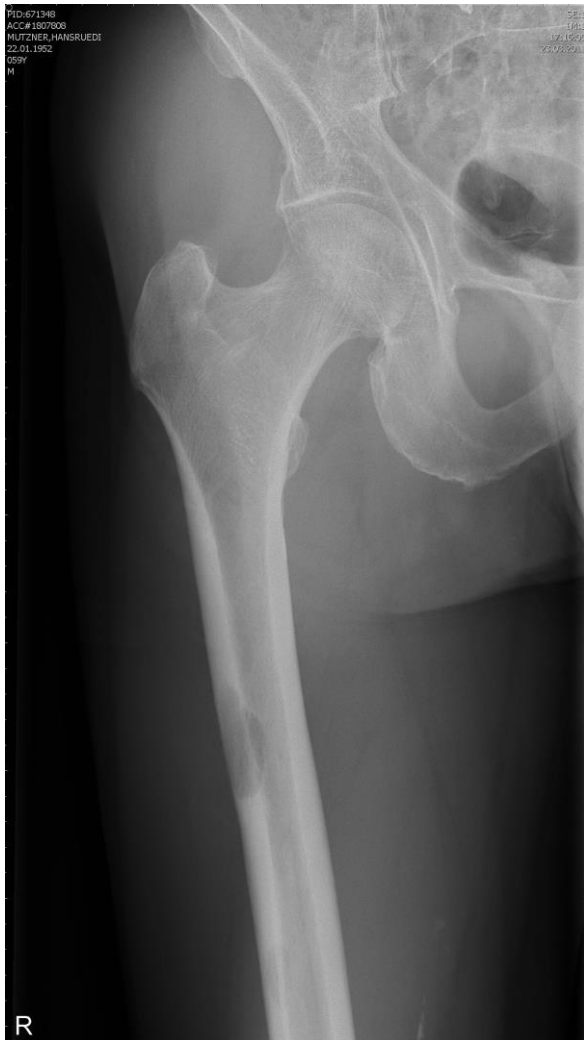thoraco- abdominal CT scan, March 10, 2011



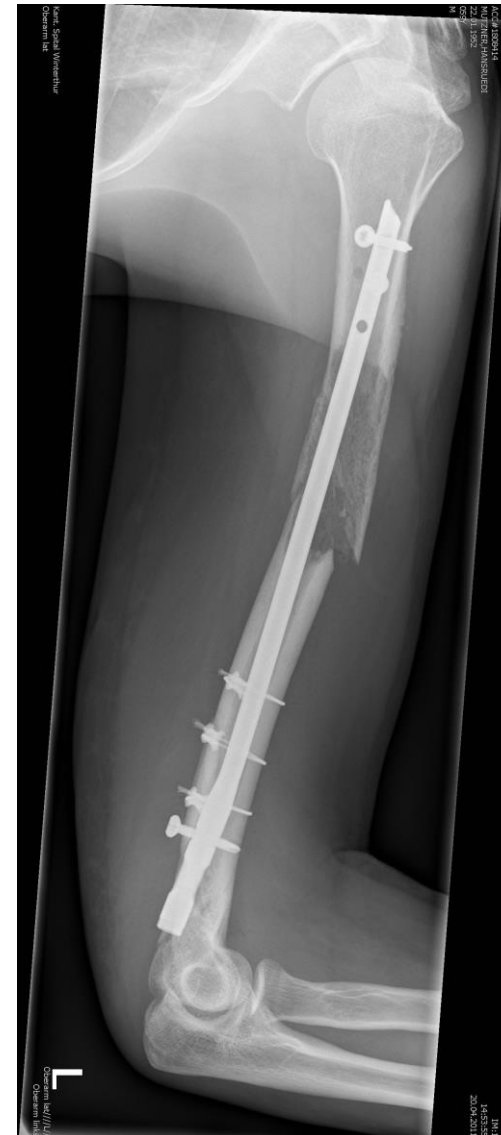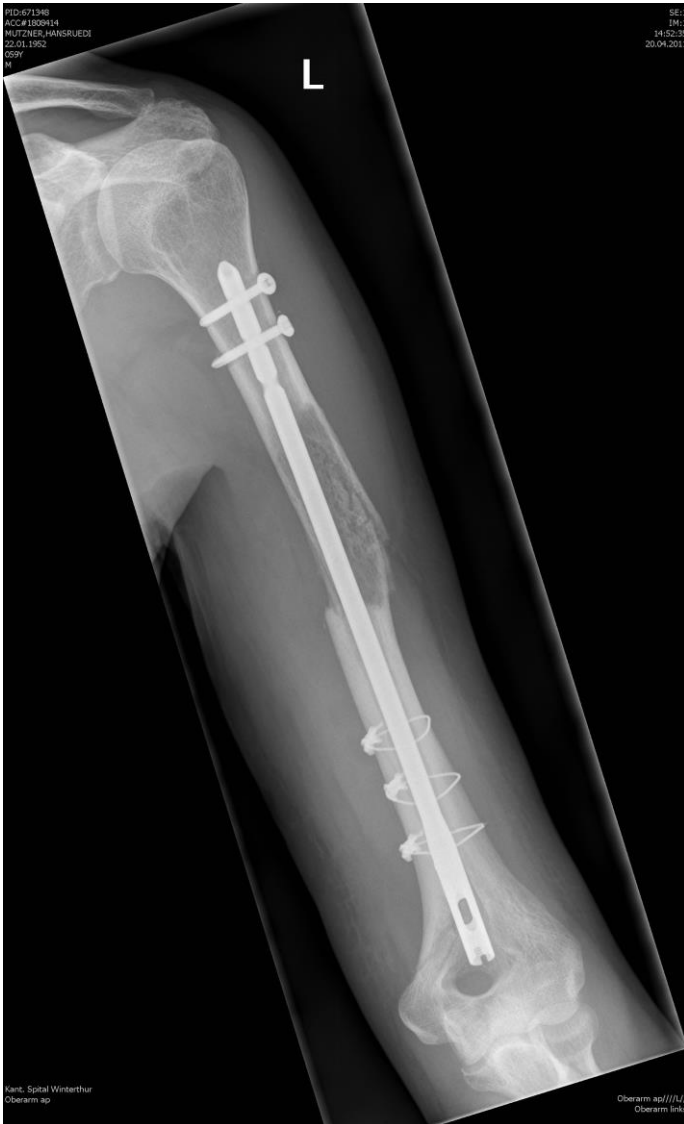humerus; diaphyseal szintigraphy external, March 10, 2011



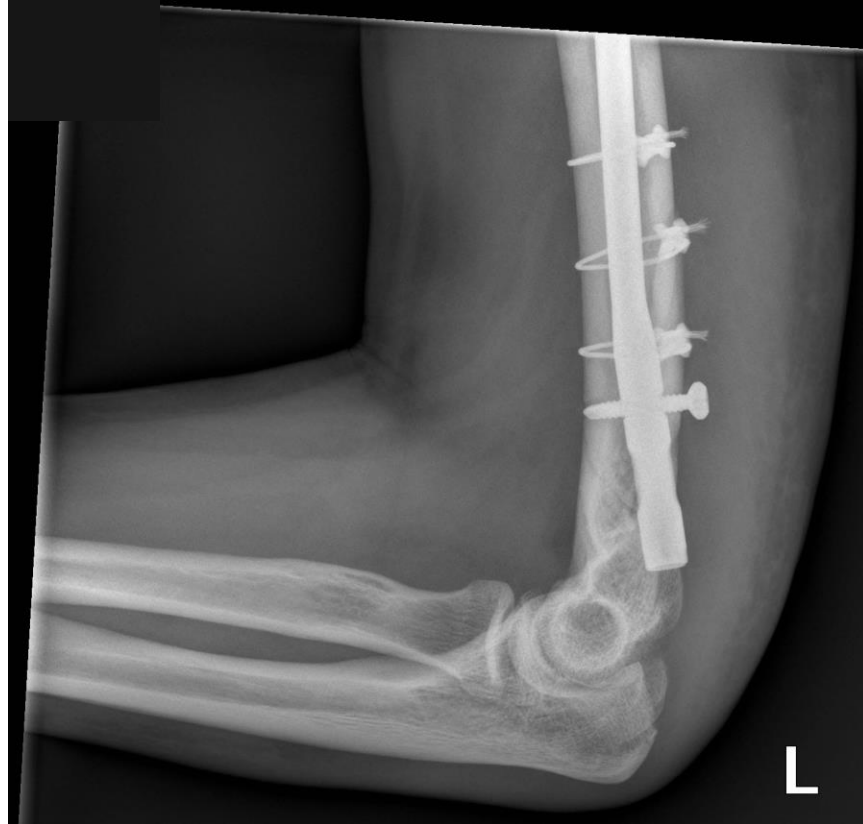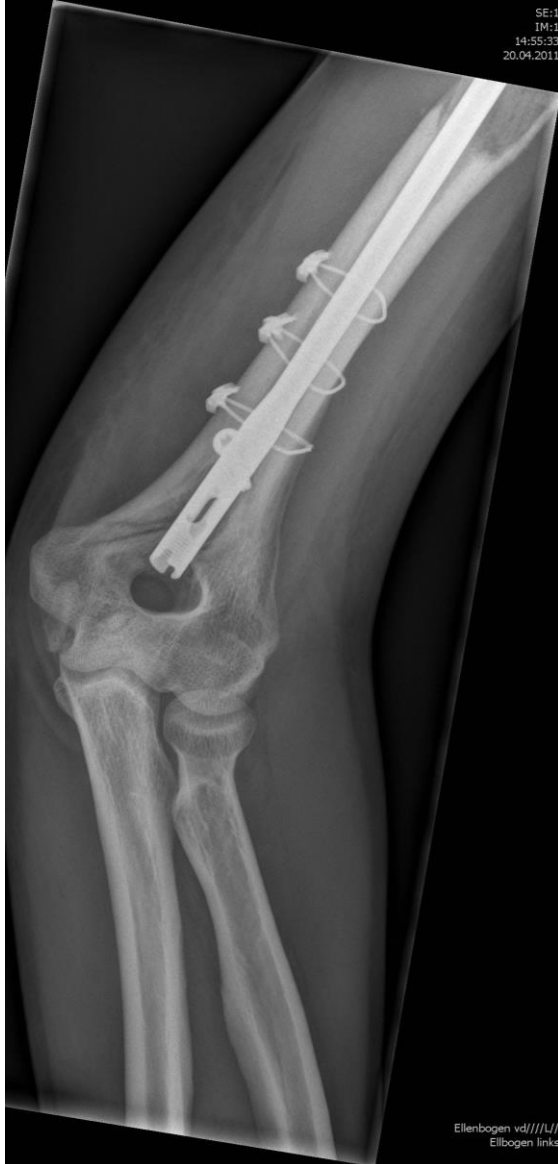humerus; diaphyseal x-ray external, March 23, 2011



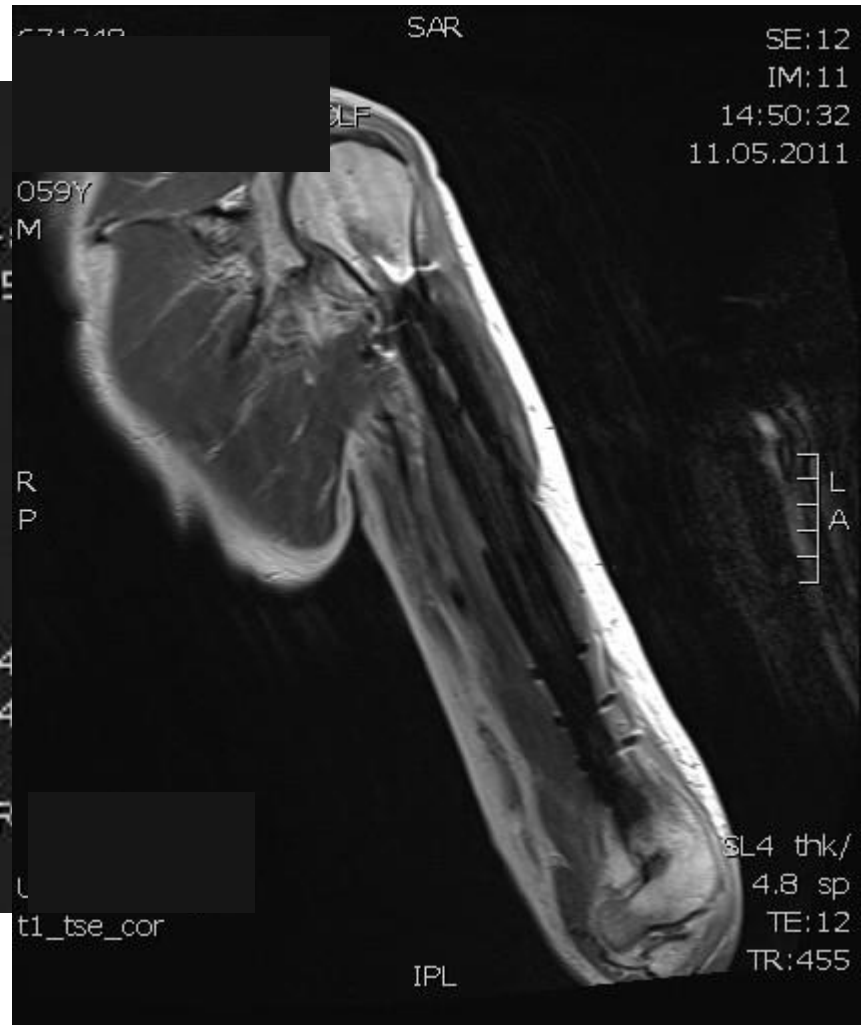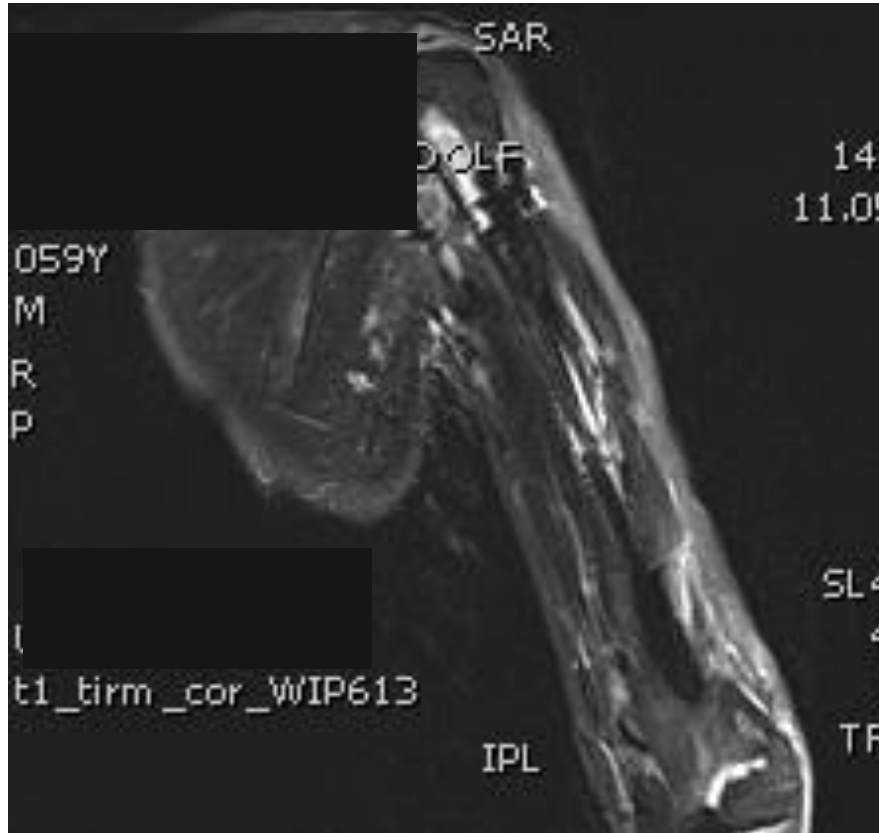
humerus; diaphyseal x-ray , Apr 20, 2011



humerus; diaphyseal x-ray , Apr 20, 2011



humerus; diaphyseal MRI , May 11, 2011

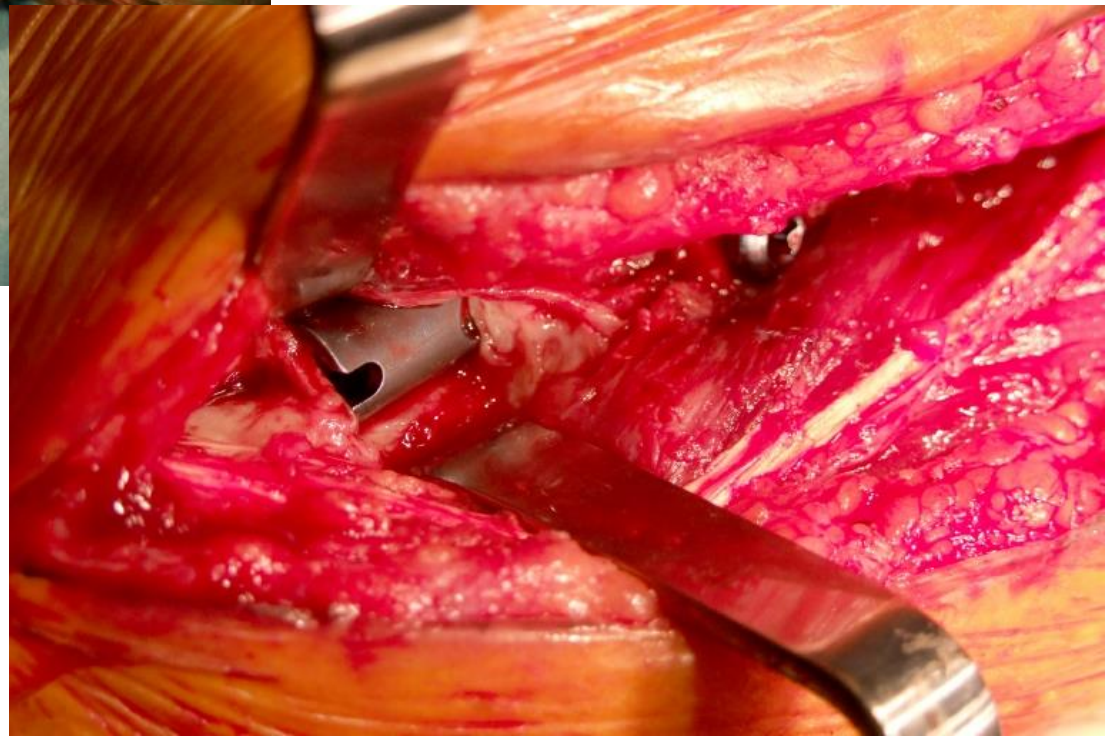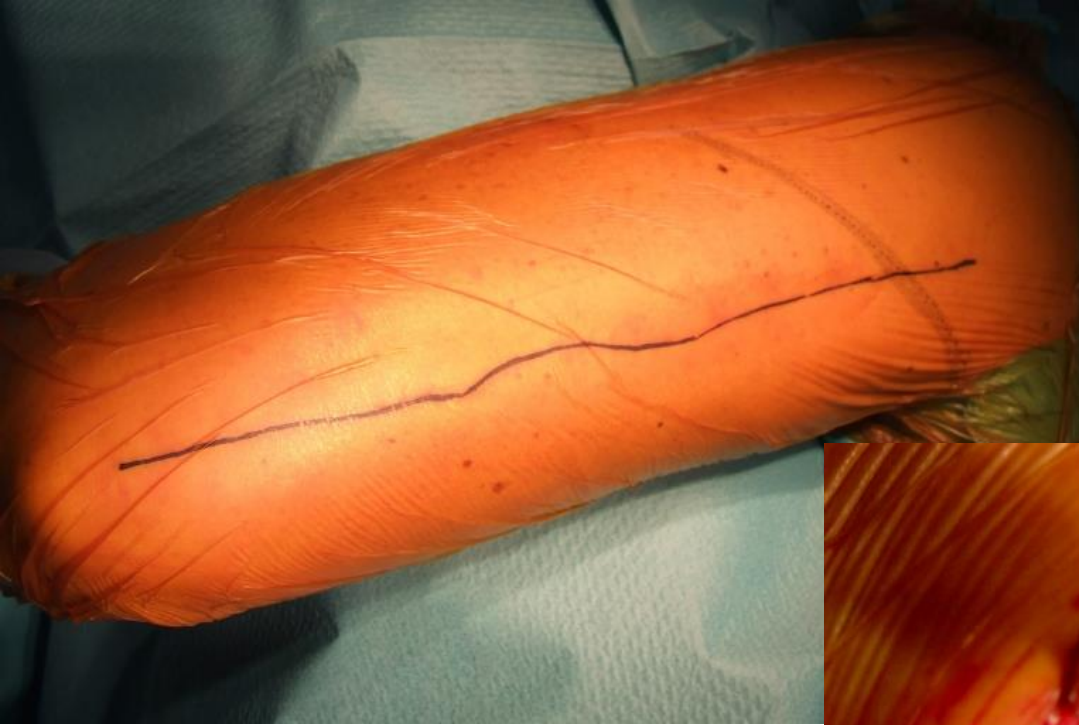


humerus; diaphseal

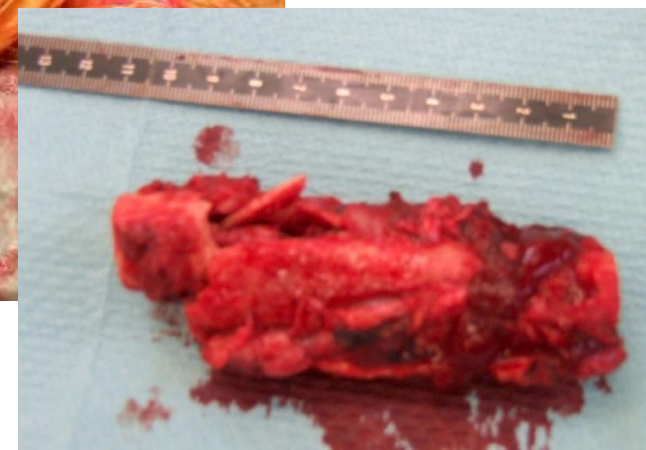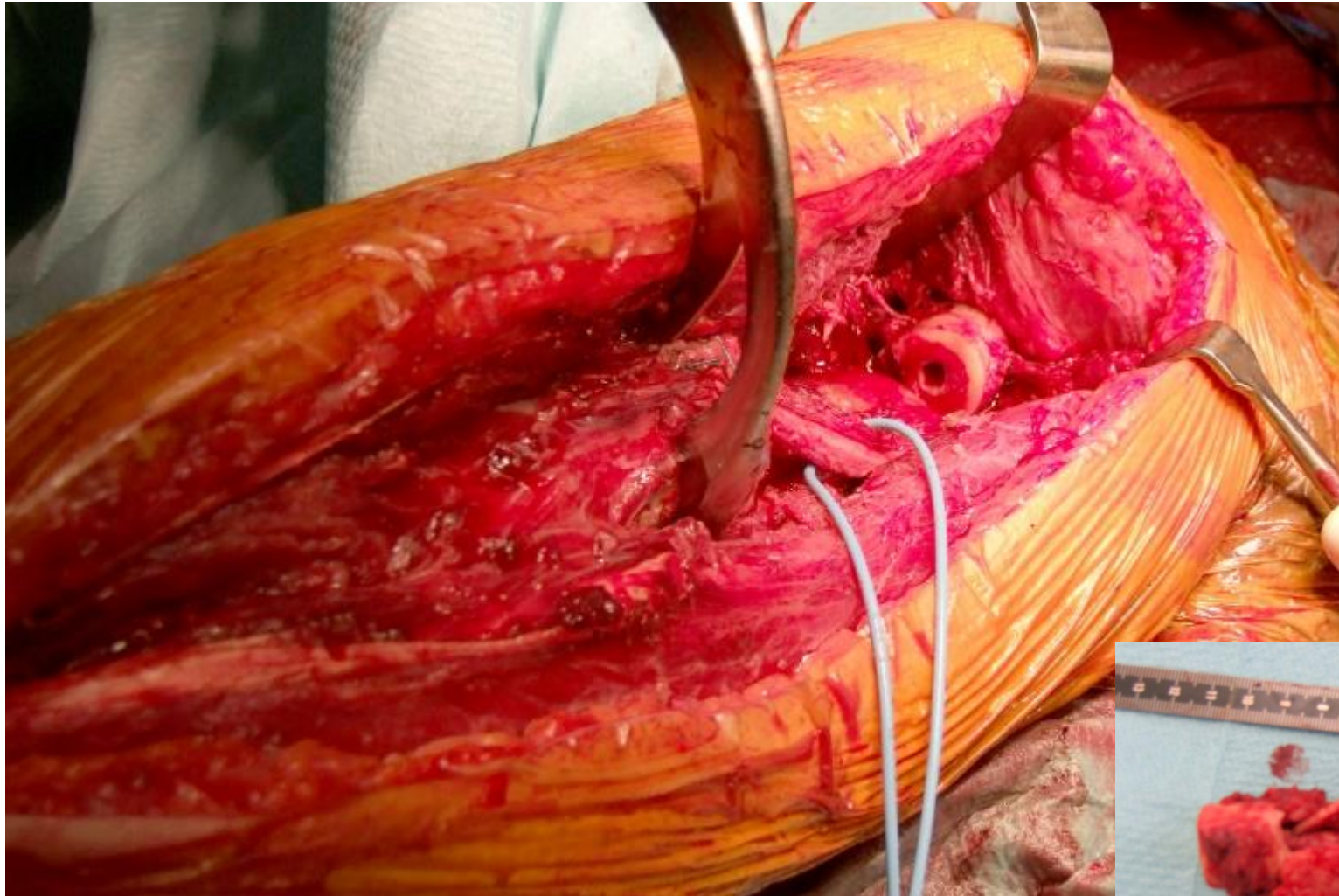
Palliative Tyrosinkinase-Inhibitor-Therapy with Votrient (Pazopanib) since 24.03.2011 , after percutaneous Radiotherapy (60 Gray) Humerus left and Femur right

→ continued/increasing instability / functionless

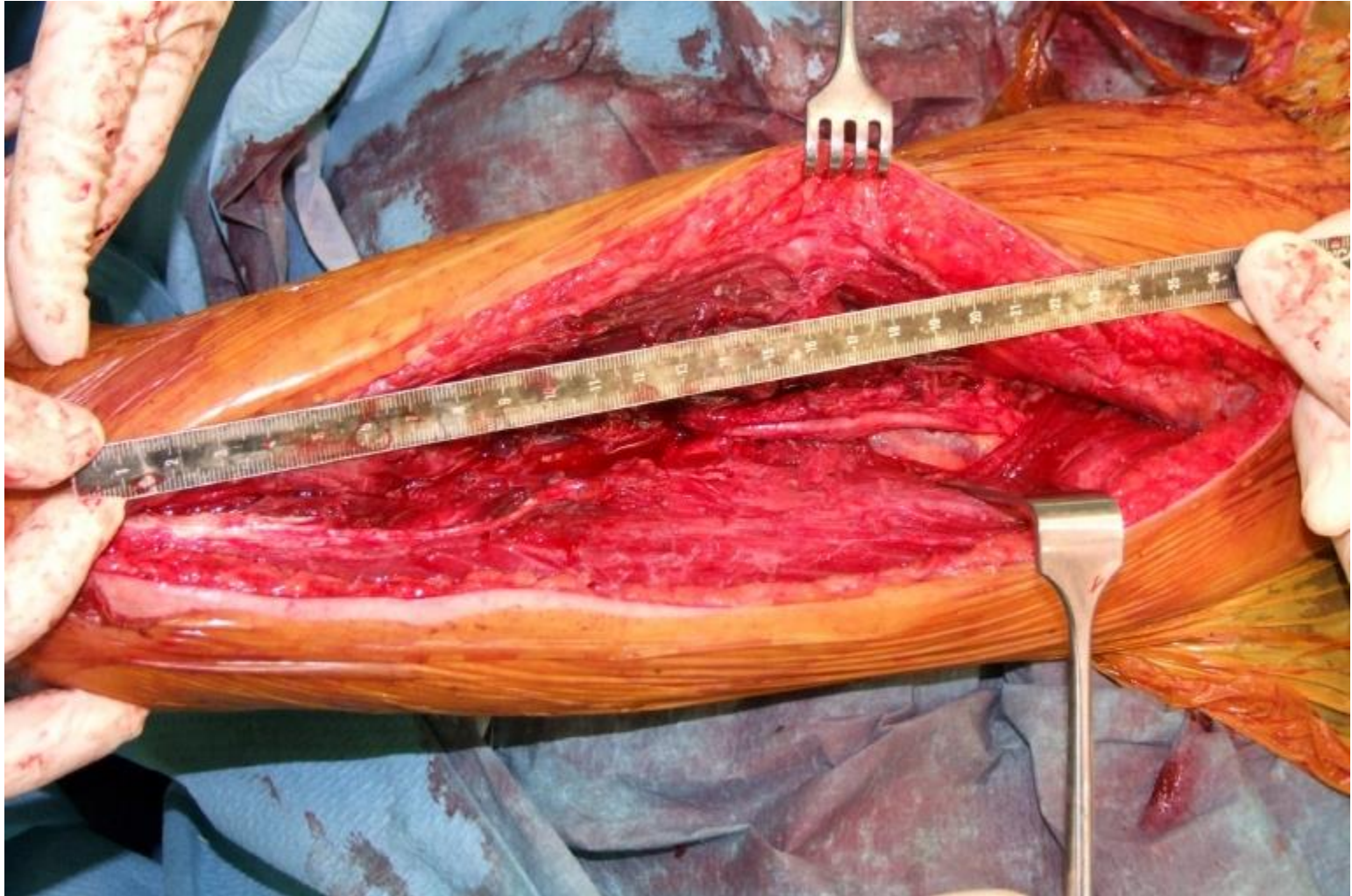
humerus; diaphyseal Surgery: May 31, 2011



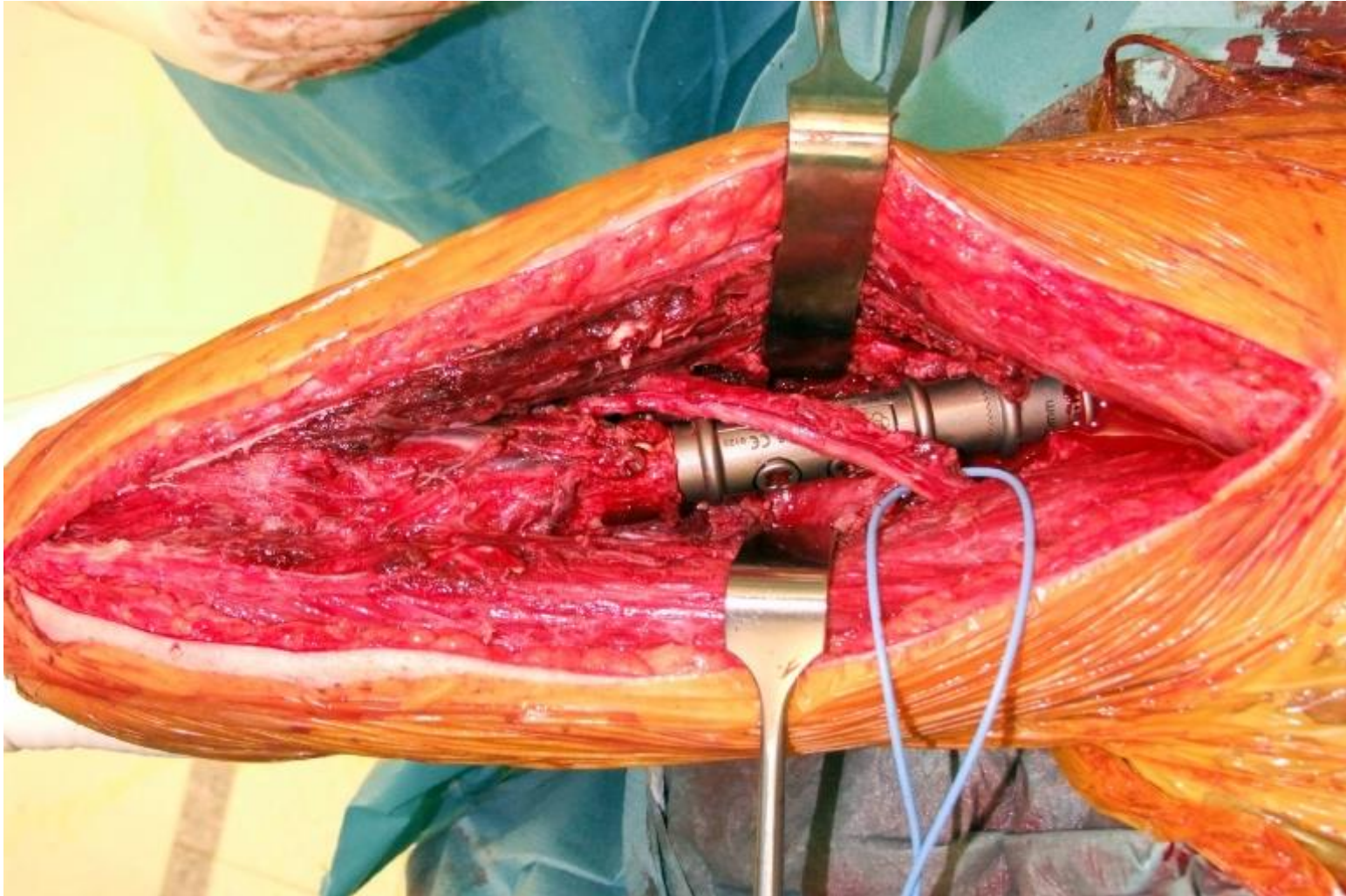humerus; diaphyseal Surgery: May 31, 2011



humerus; diaphyseal Surgery: May 31, 2011

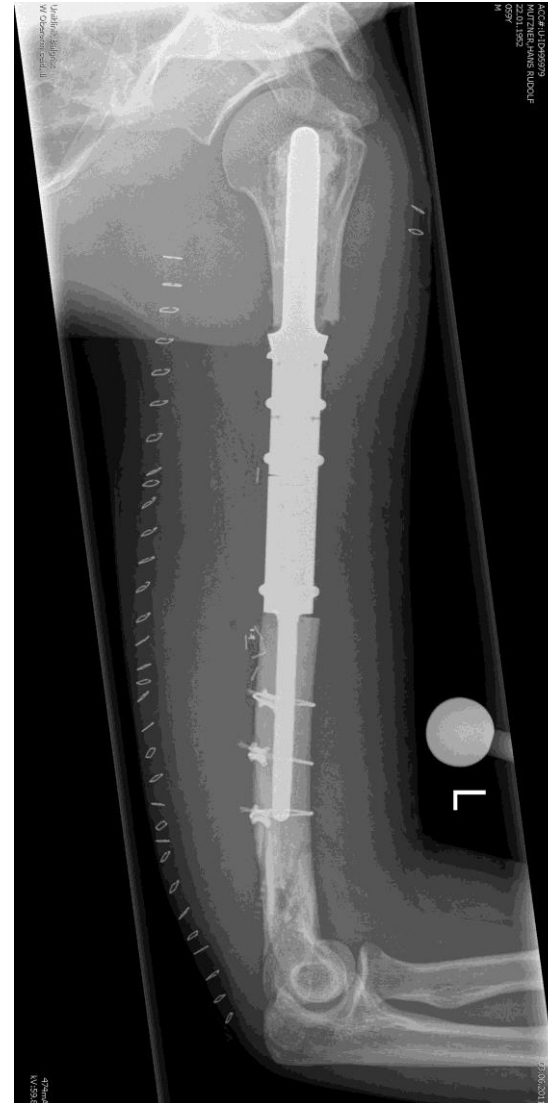
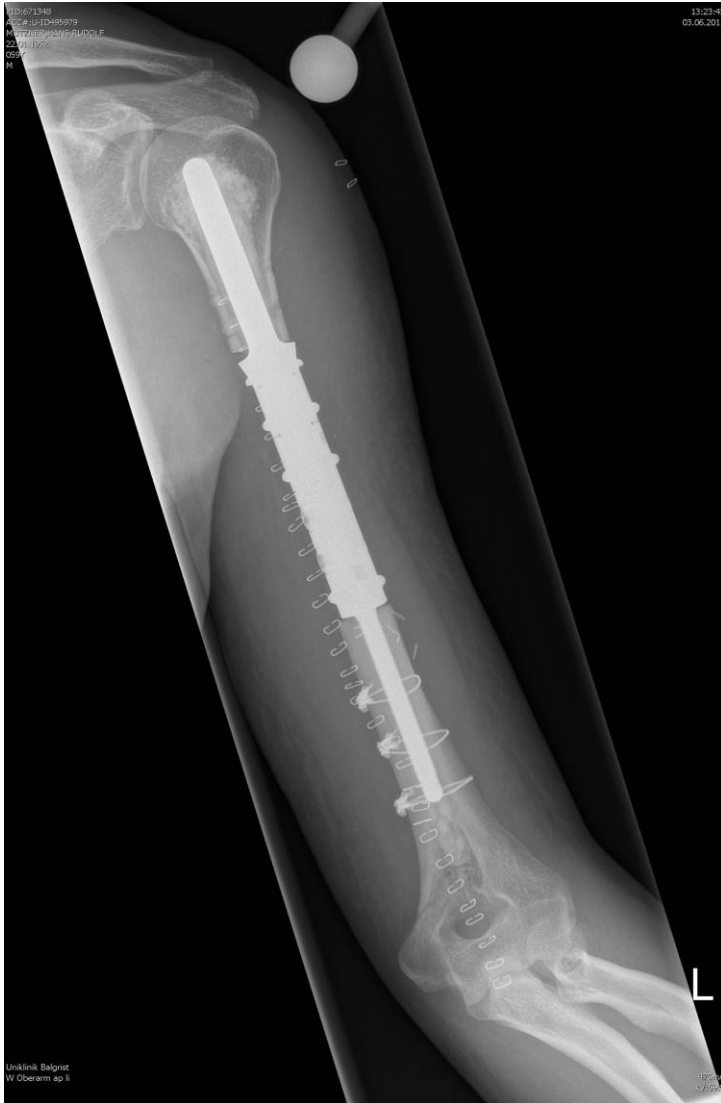

humerus; diaphyseal Surgery: May 31, 2011



humerus; diaphyseal

X-ray postoperative , June 03, 2011



humerus; diaphseal

Result Surgery: May 31, 2011

Eingang: 01.06.2011

Klinische Angaben

Pathologische Fraktur bei metastasierendem Nierenzellkarzinom. Tumor?

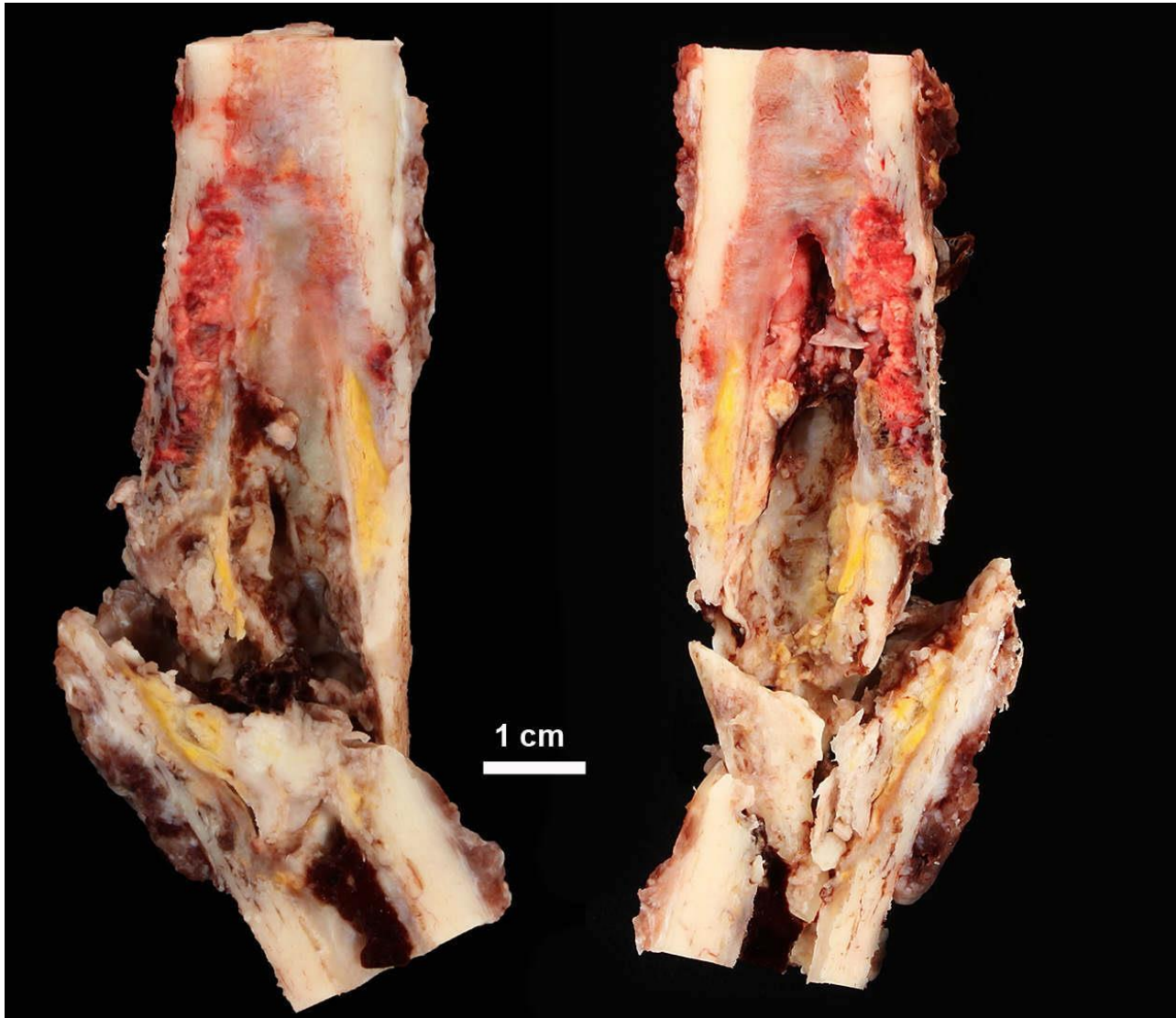
Angaben zur Probe

B 2011.26781: Humerusschaft Segment links

B 2011.26782: Spongiose Humerus kaud.

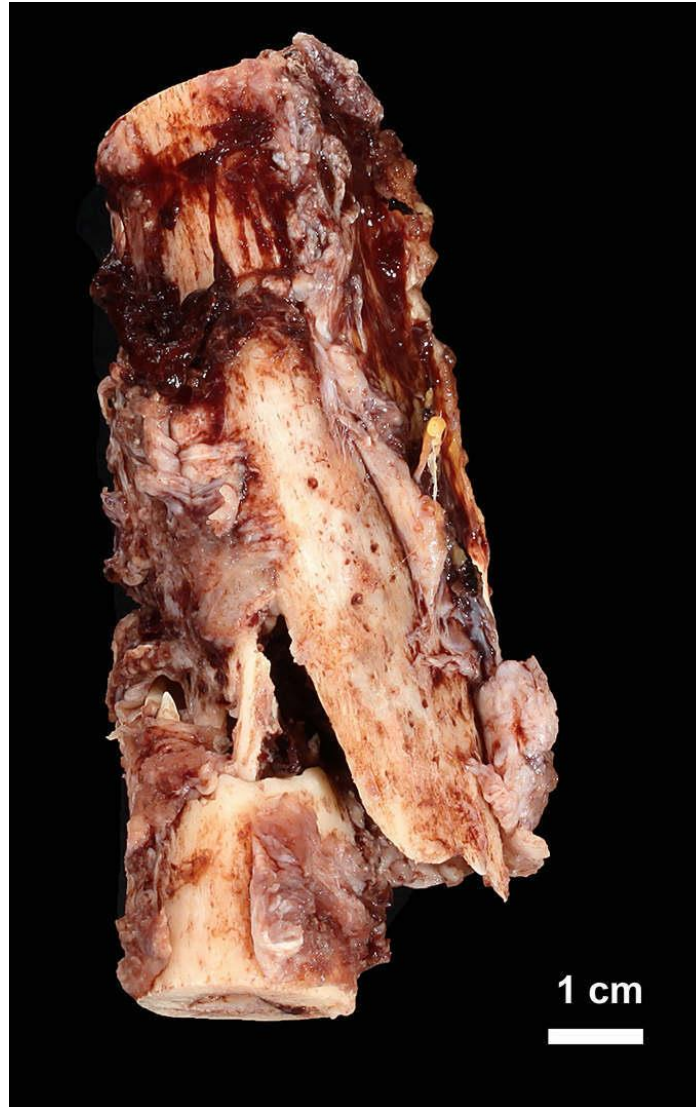humerus; diaphyseal

Result Surgery: May 31, 2011

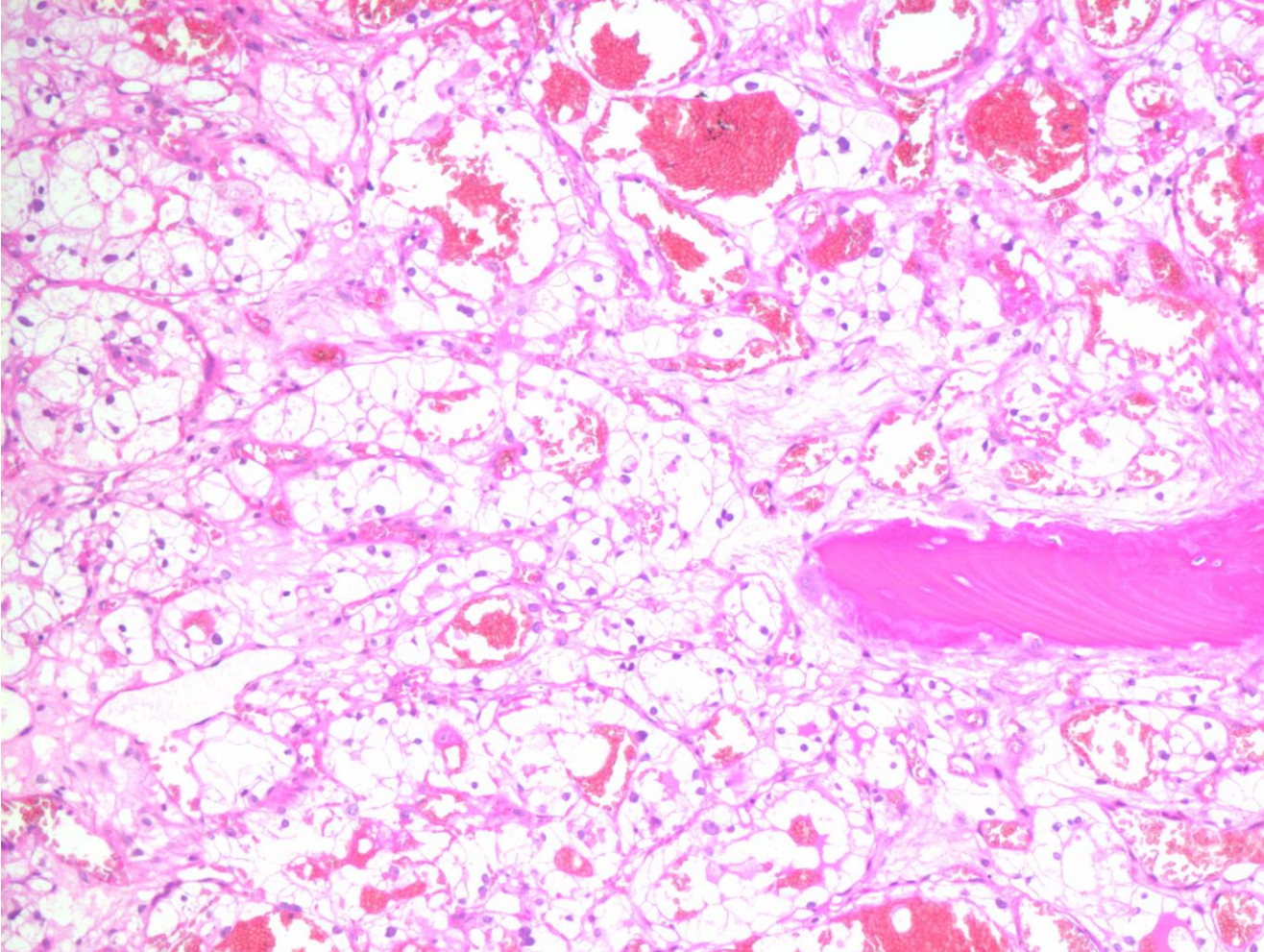


humerus; diaphyseal

Result Surgery: May 31, 2011



humerus; diaphyseal path report: May 31, 2011



humerus; diaphyseal path report: May 31, 2011

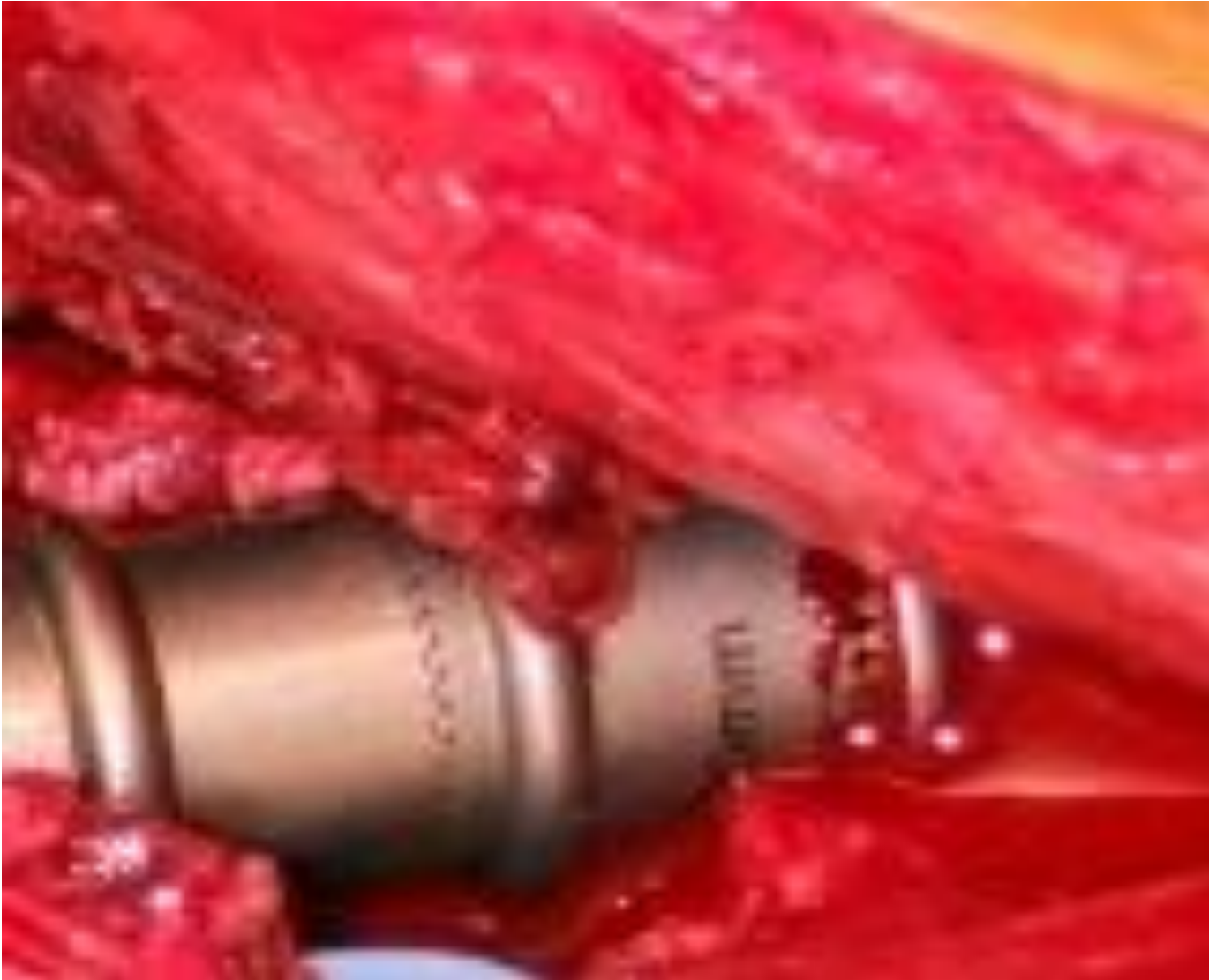Eingang: 01.06.2011

Diagnose

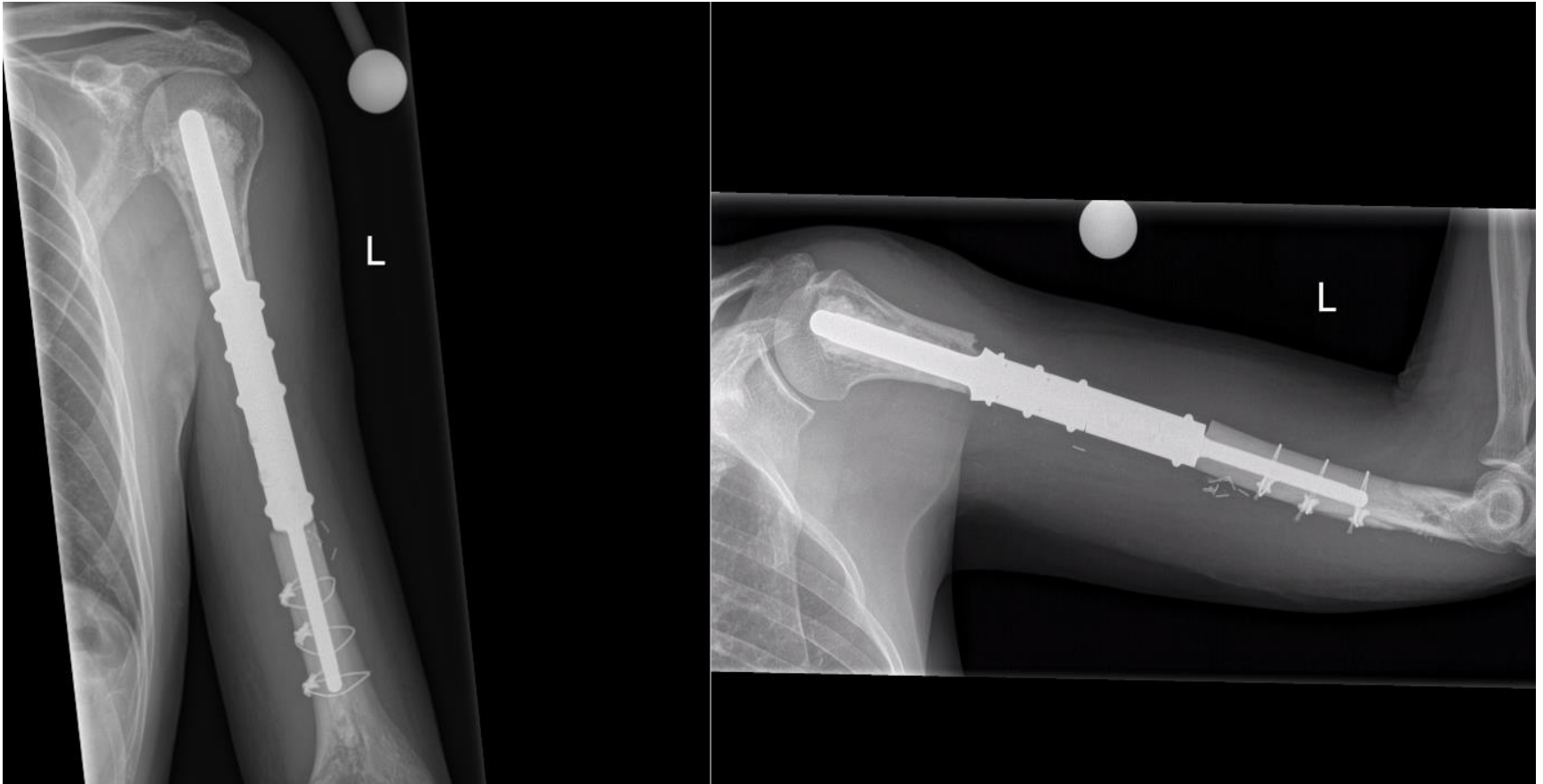B 2011.26781: Humerusschaft-Teilresektat (links) mit pathologischer Fraktur im Bereich einer grossenteils nekrotischen Metastase eines hellzelligen Nierenzellkarzinoms. Kein Nachweis von Tumorgewebe in ossären Resektionsrändern (vgl. Kommentar).

B 2011.26782: Fragmentiertes umgebautes Knochengewebe neben Fibrinmassen und fibrosiertem Markraumgewebe mit Blutungsresiduen (Spongiosa Humerus kaudal). Kein Nachweis von Karzinomgewebe.

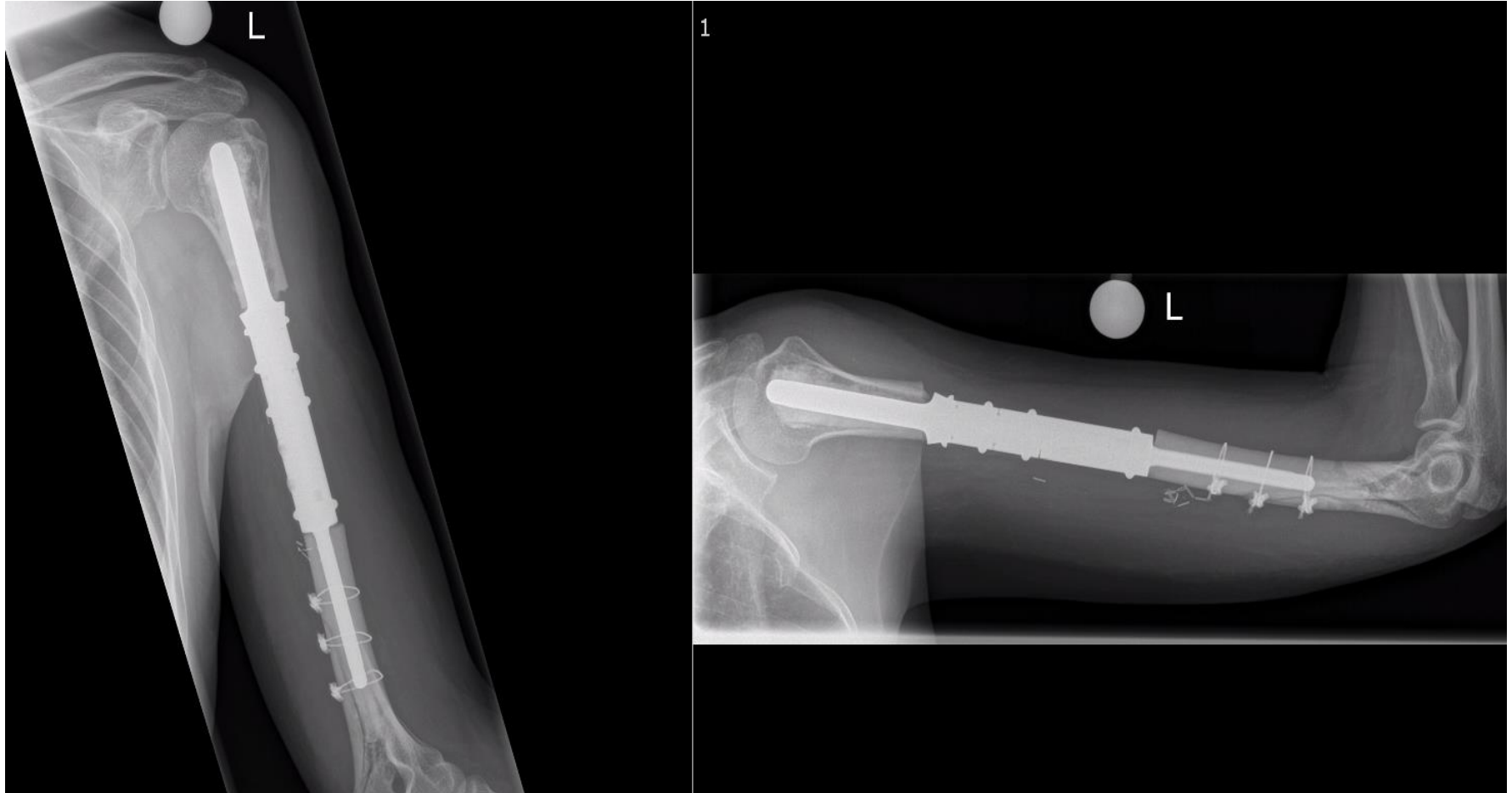humerus; diaphyseal Surgery: May 31, 2011



humerus; diaphyseal X-ray, Jul 13, 2011

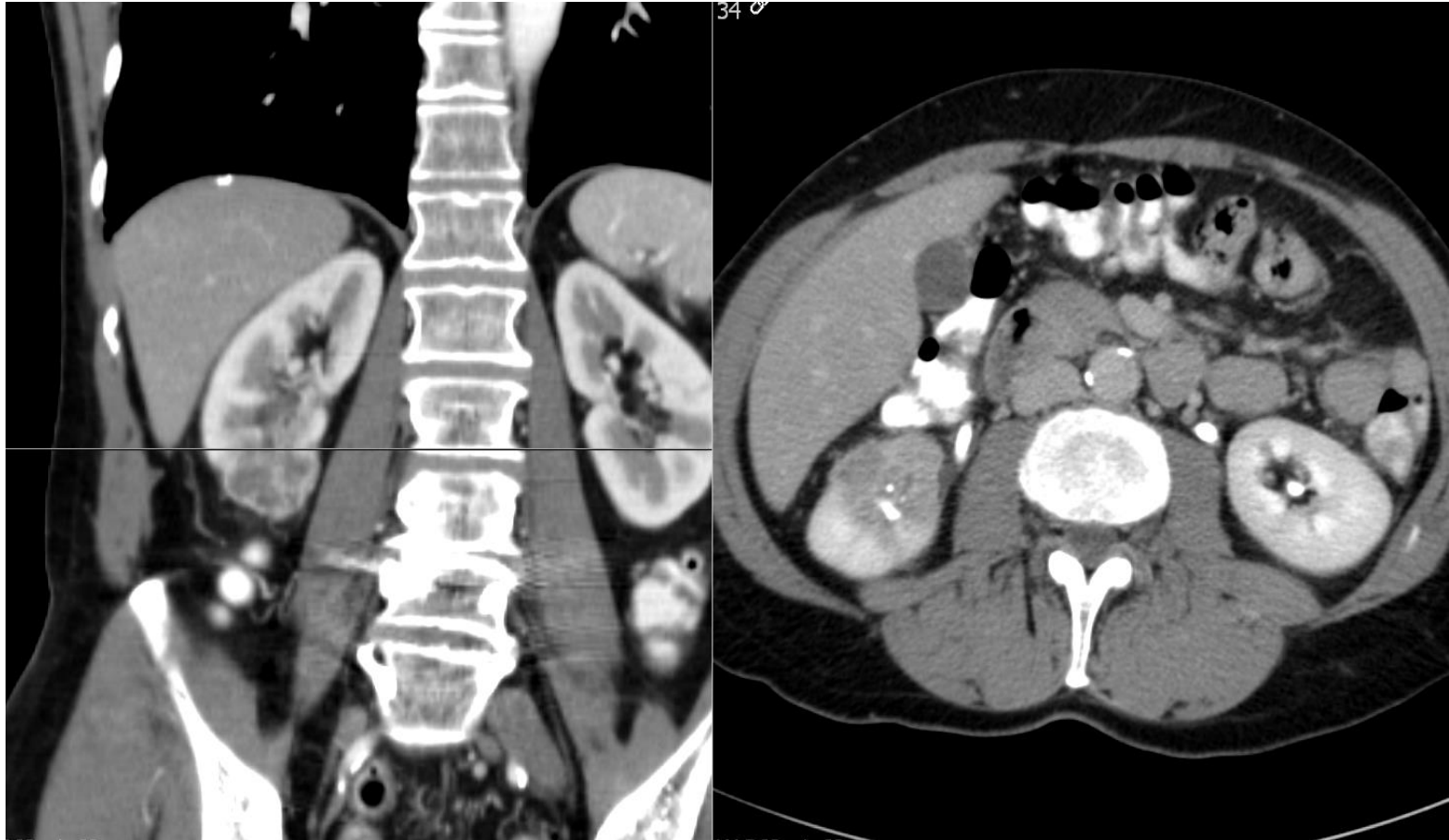


humerus; diaphyseal X-ray, Aug 8, 2011



humerus; diaphyseal

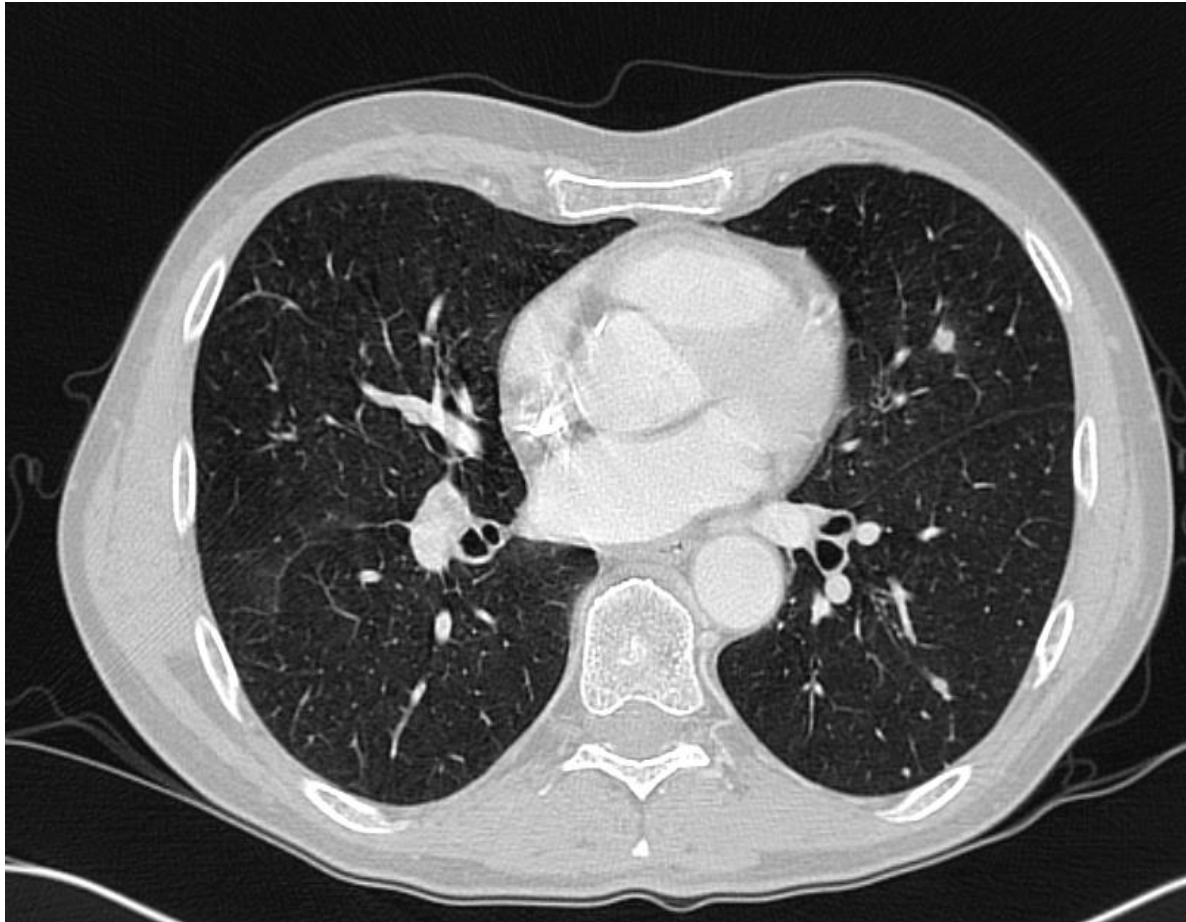
CT Thorax /Abd, Aug 16, 2011



Decreasing size of prim tumor

humerus; diaphyseal

CT Thorax /Abd, Aug 16, 2011

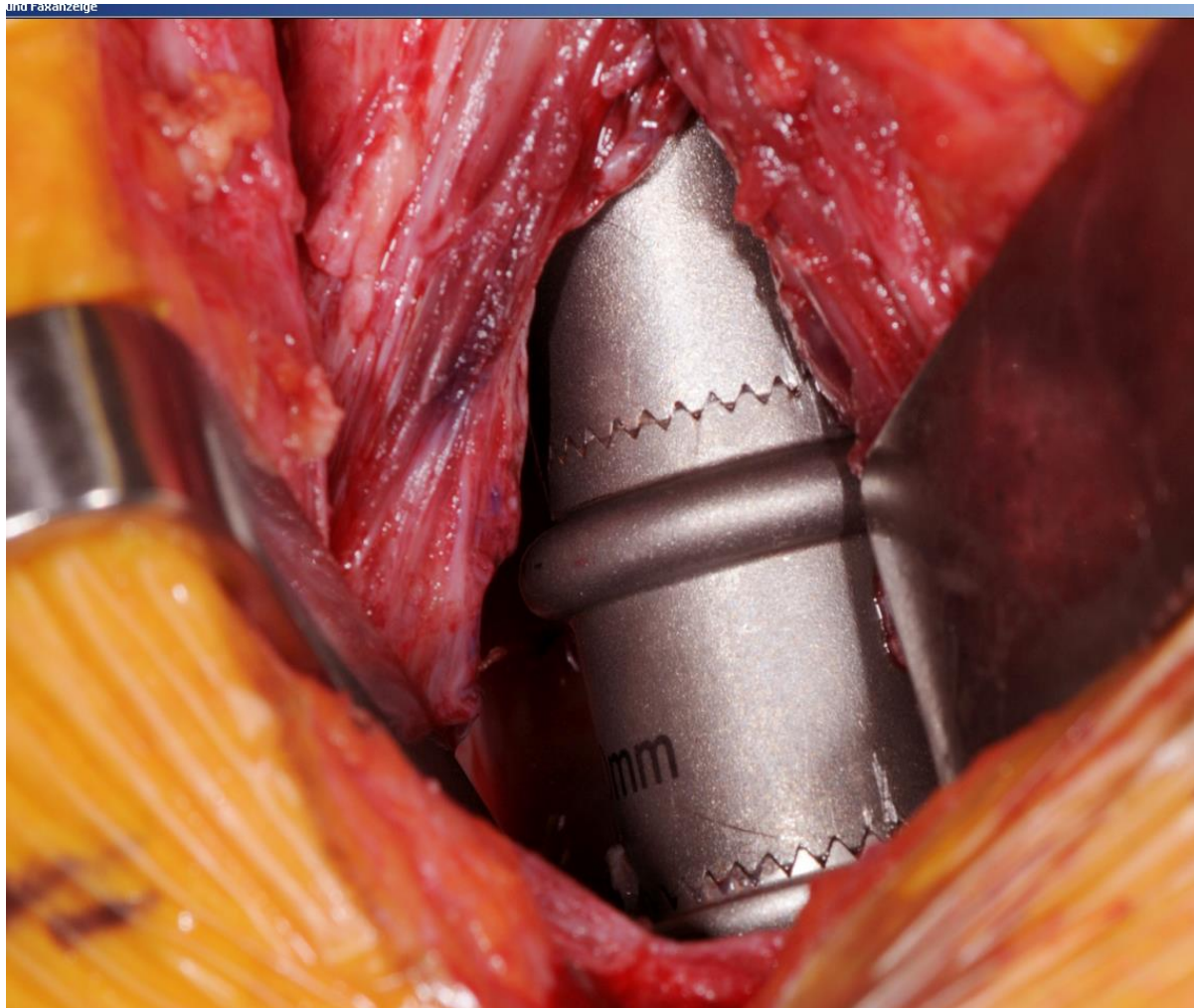


Stationary metastases

humerus; diaphyseal

Aug. 23, 2011:

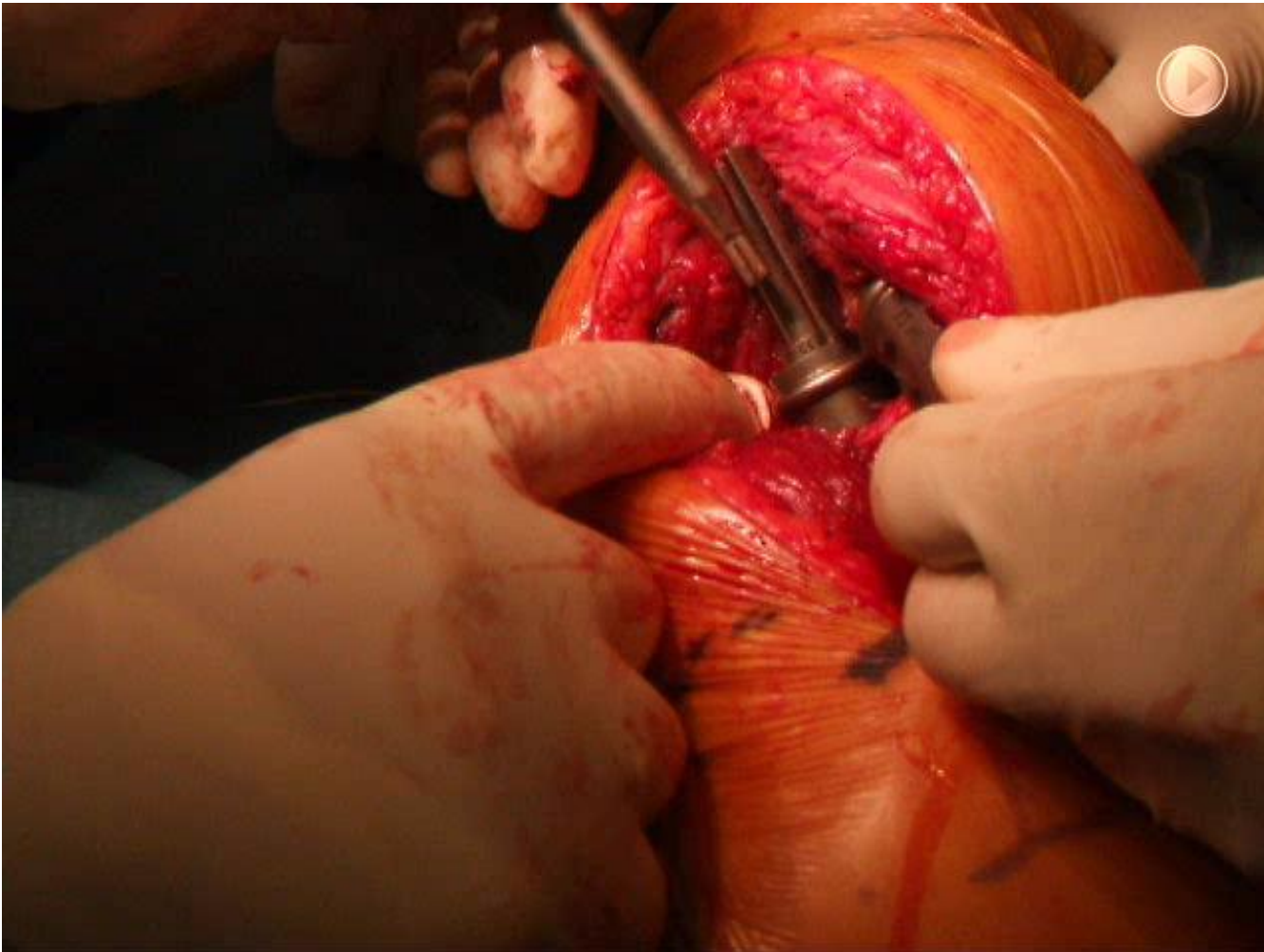
Surgical Revision of rotational instability



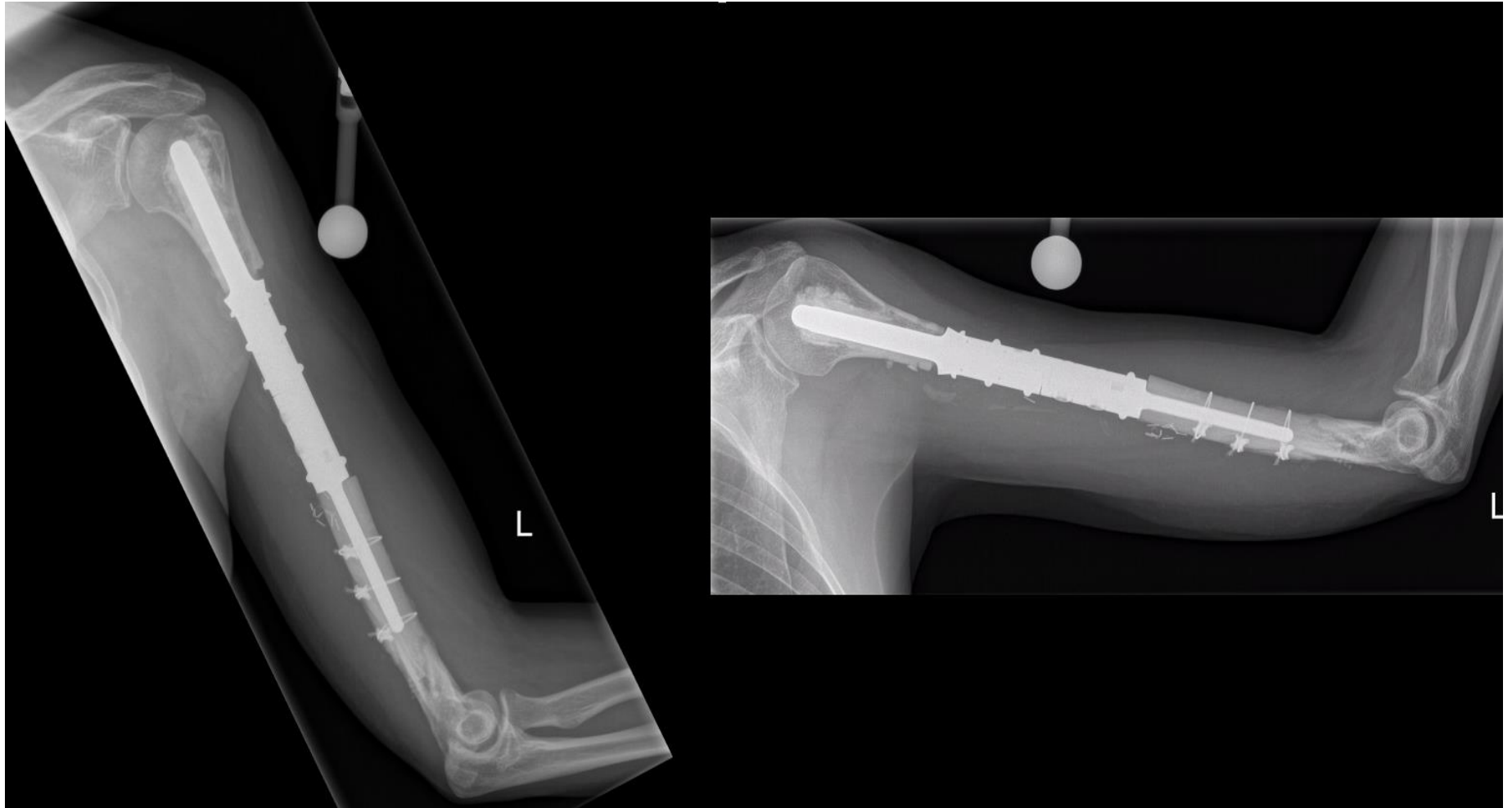humerus; diaphyseal

Aug. 23, 2011:

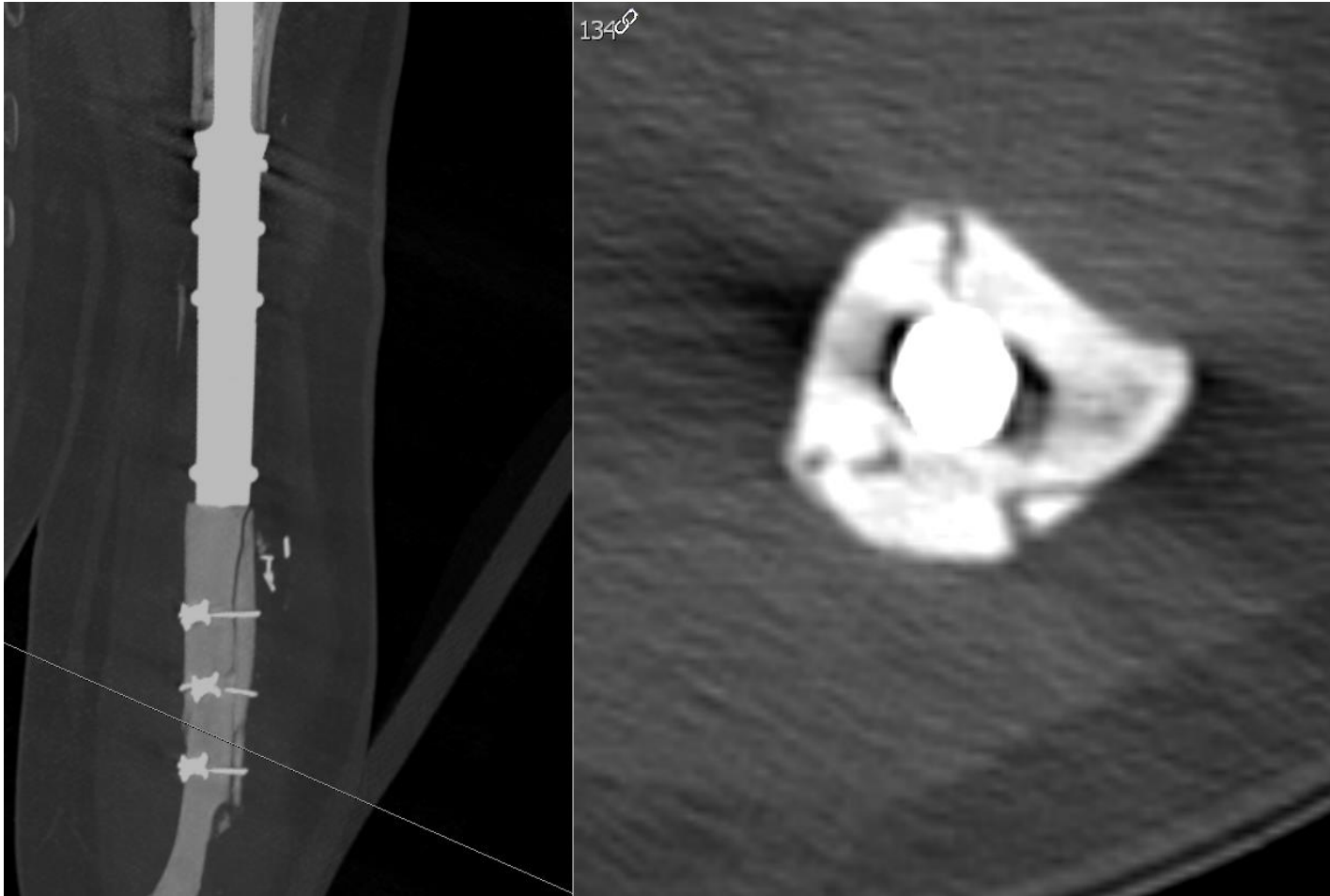
Surgical Revision of rotational instability



humerus; diaphyseal X-ray, Nov. 2, 2011



humerus; diaphyseal CT, Nov. 3, 2011

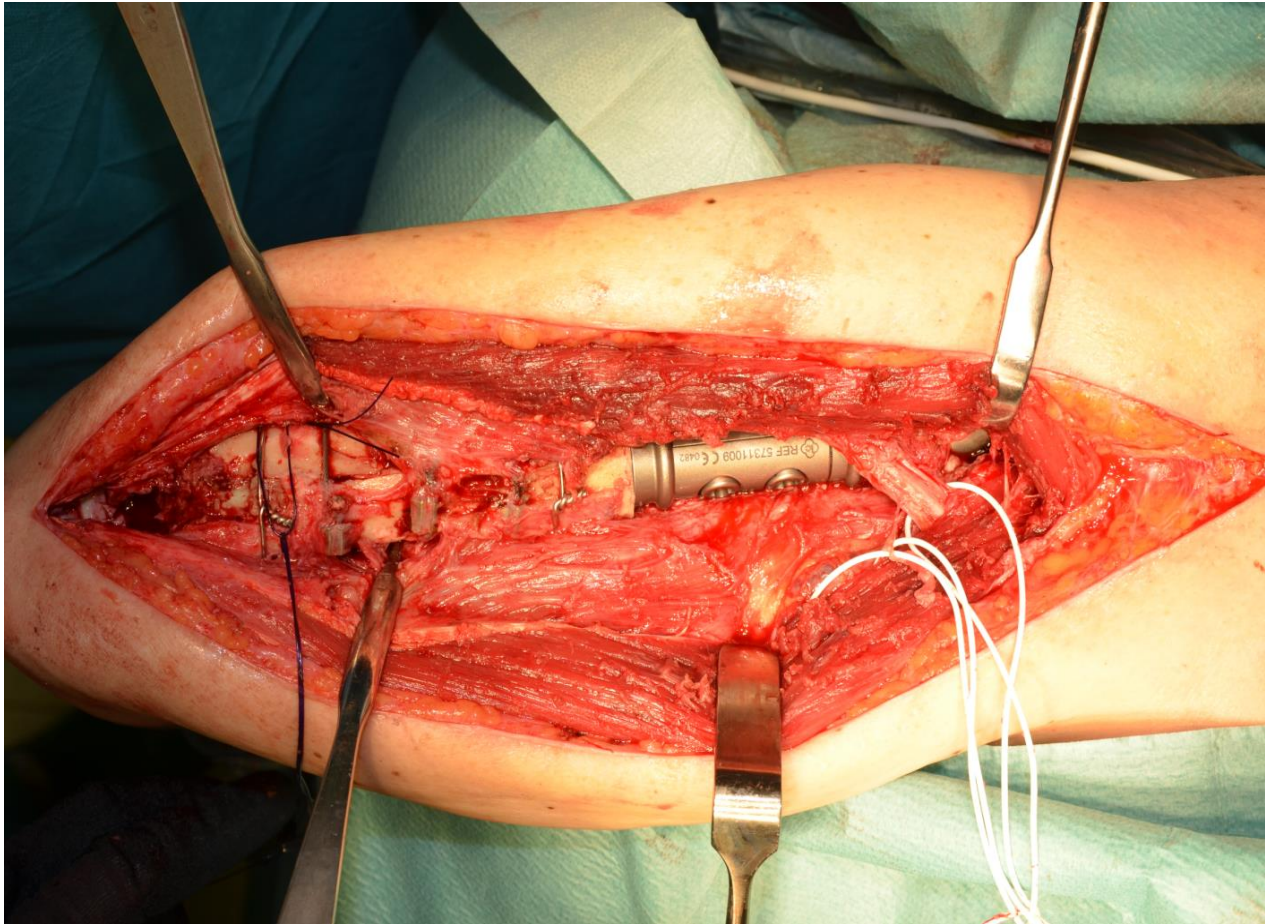


**Distal rotational instability due to
periprosthetic fracture**

humerus; diaphyseal

Jan 12; 2012:

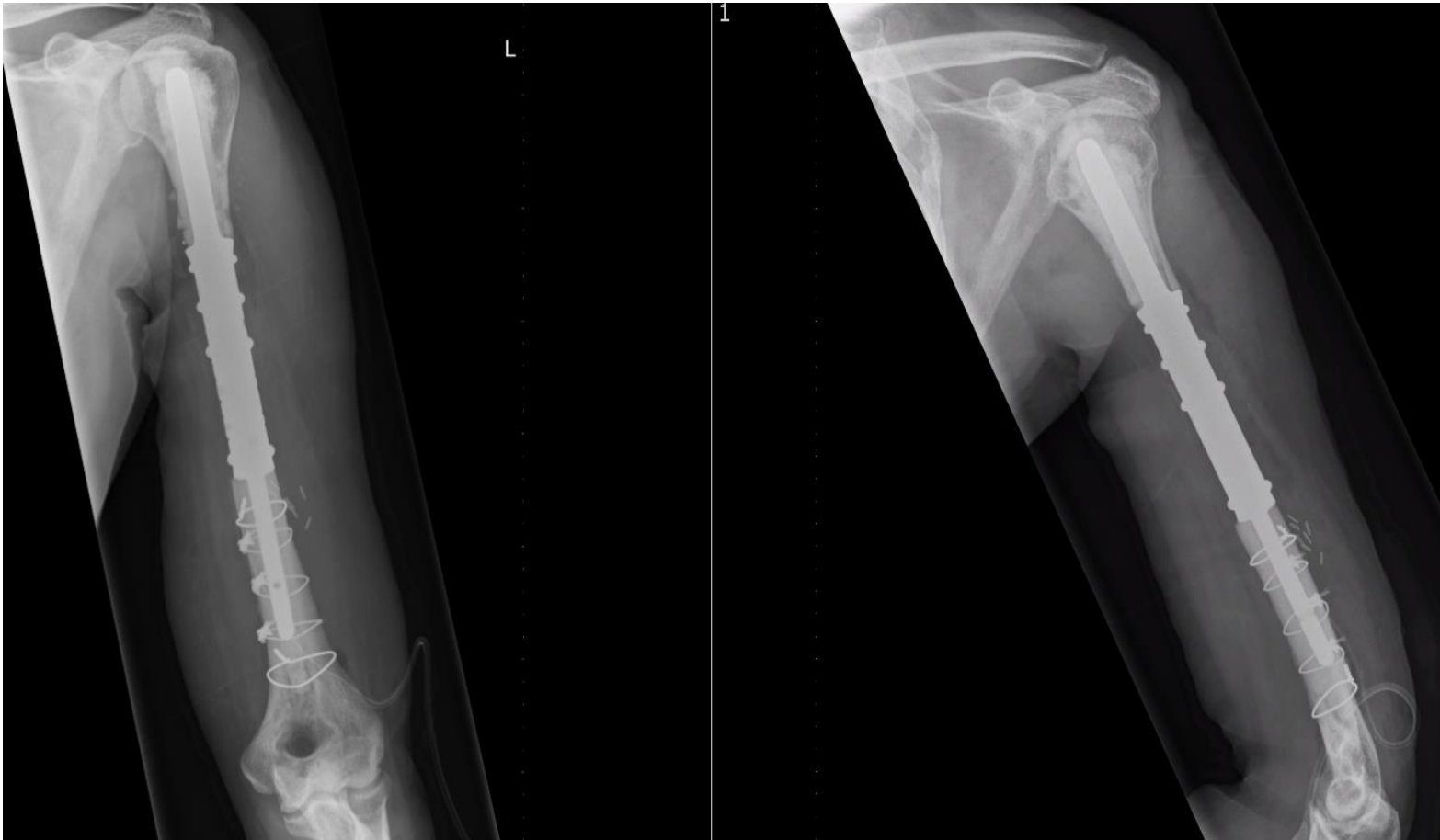
Surgical Revision of rotational instability



humerus; diaphyseal

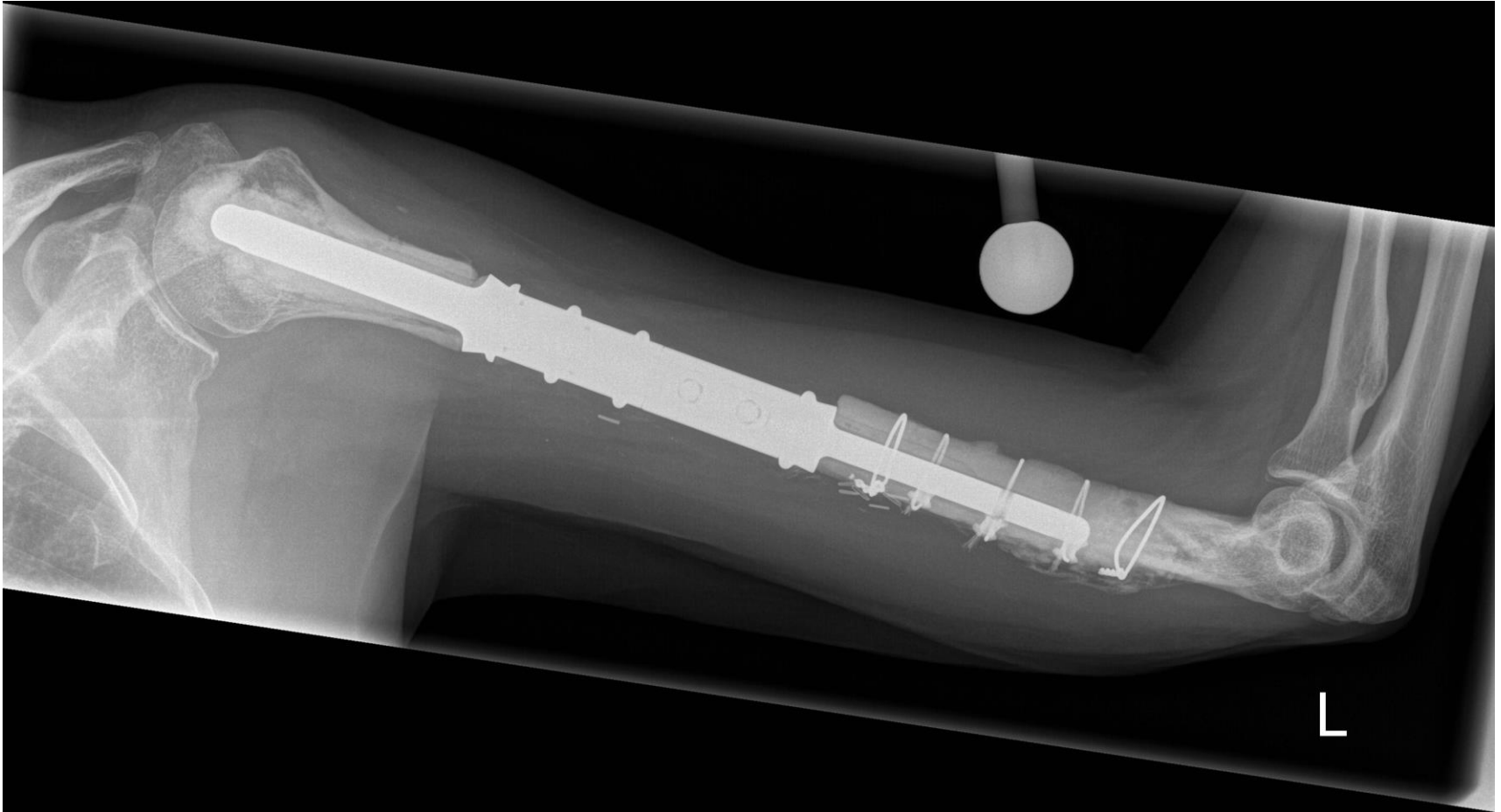
Jan 12; 2012:

Surgical Revision of rotational instability



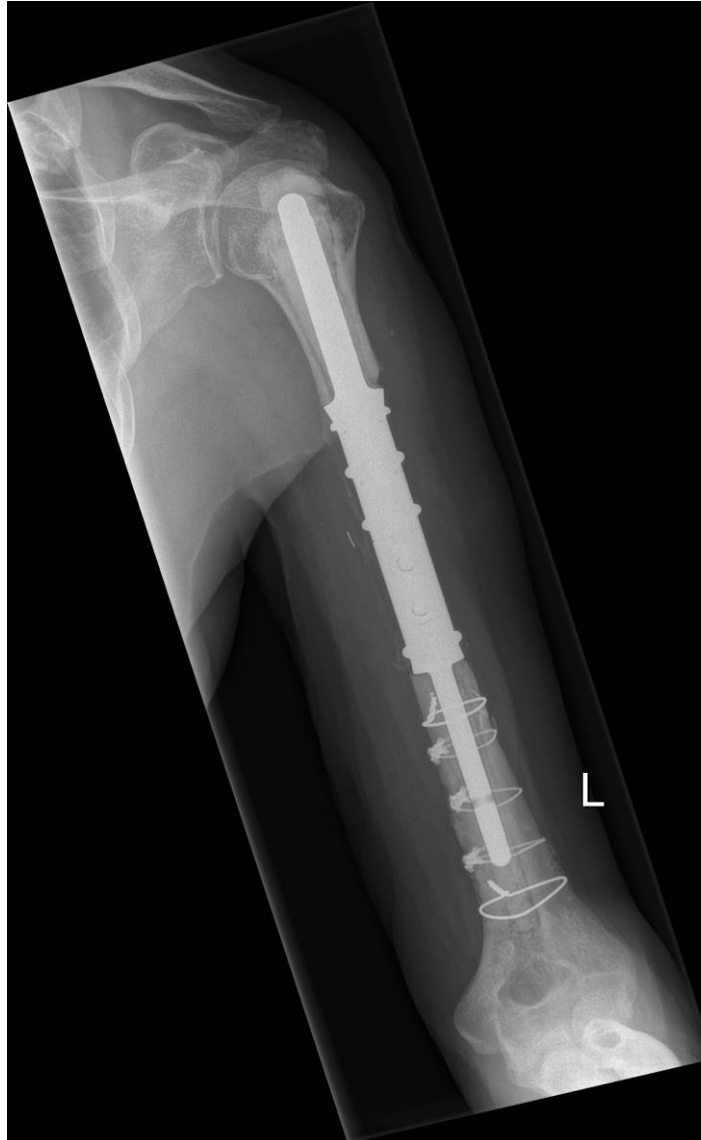humerus; diaphyseal

X-Ray: February 13, 2013



humerus; diaphyseal

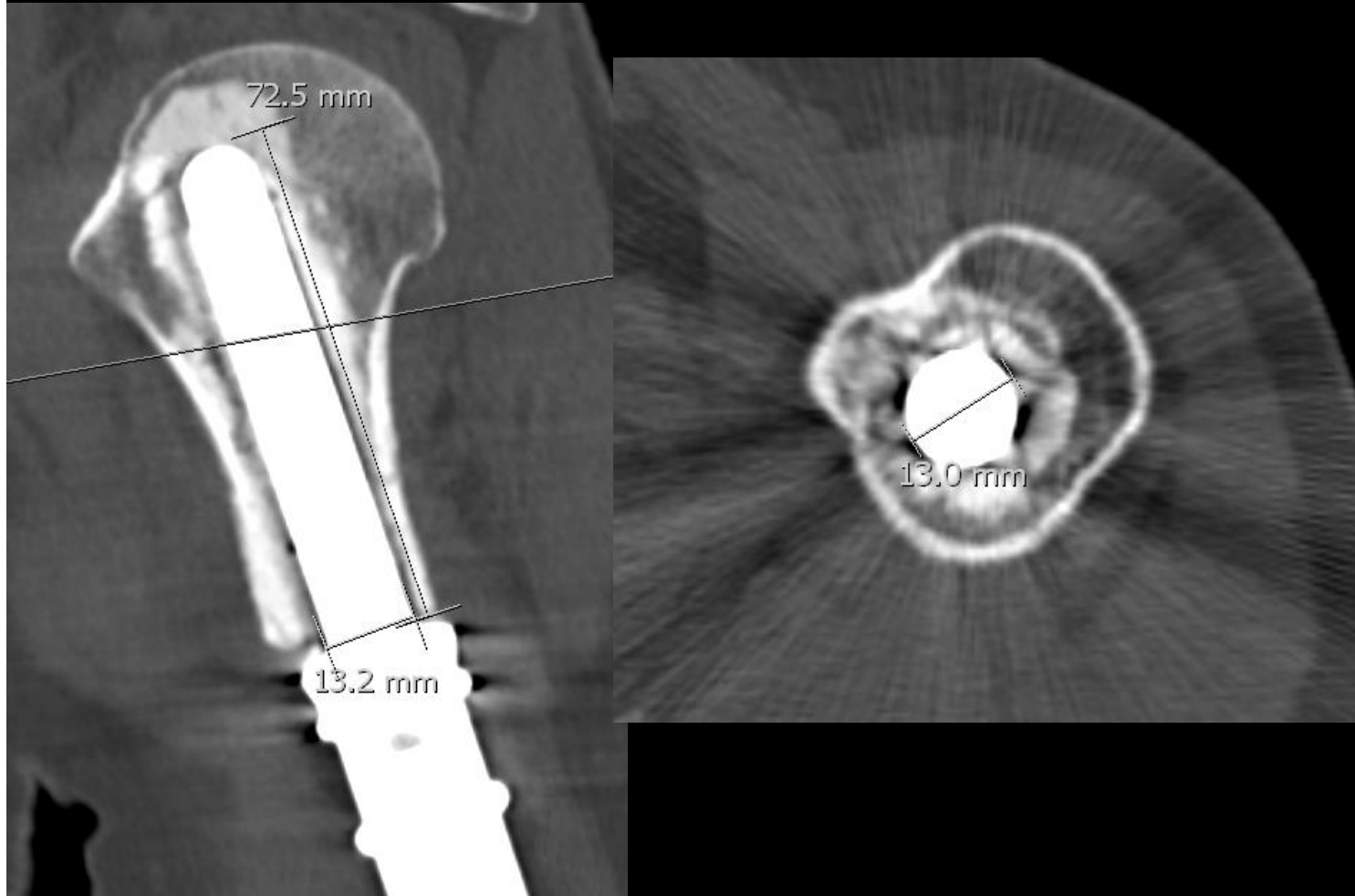
X-Ray: February 13, 2013



humerus; diaphyseal

CT: February 22, 2013

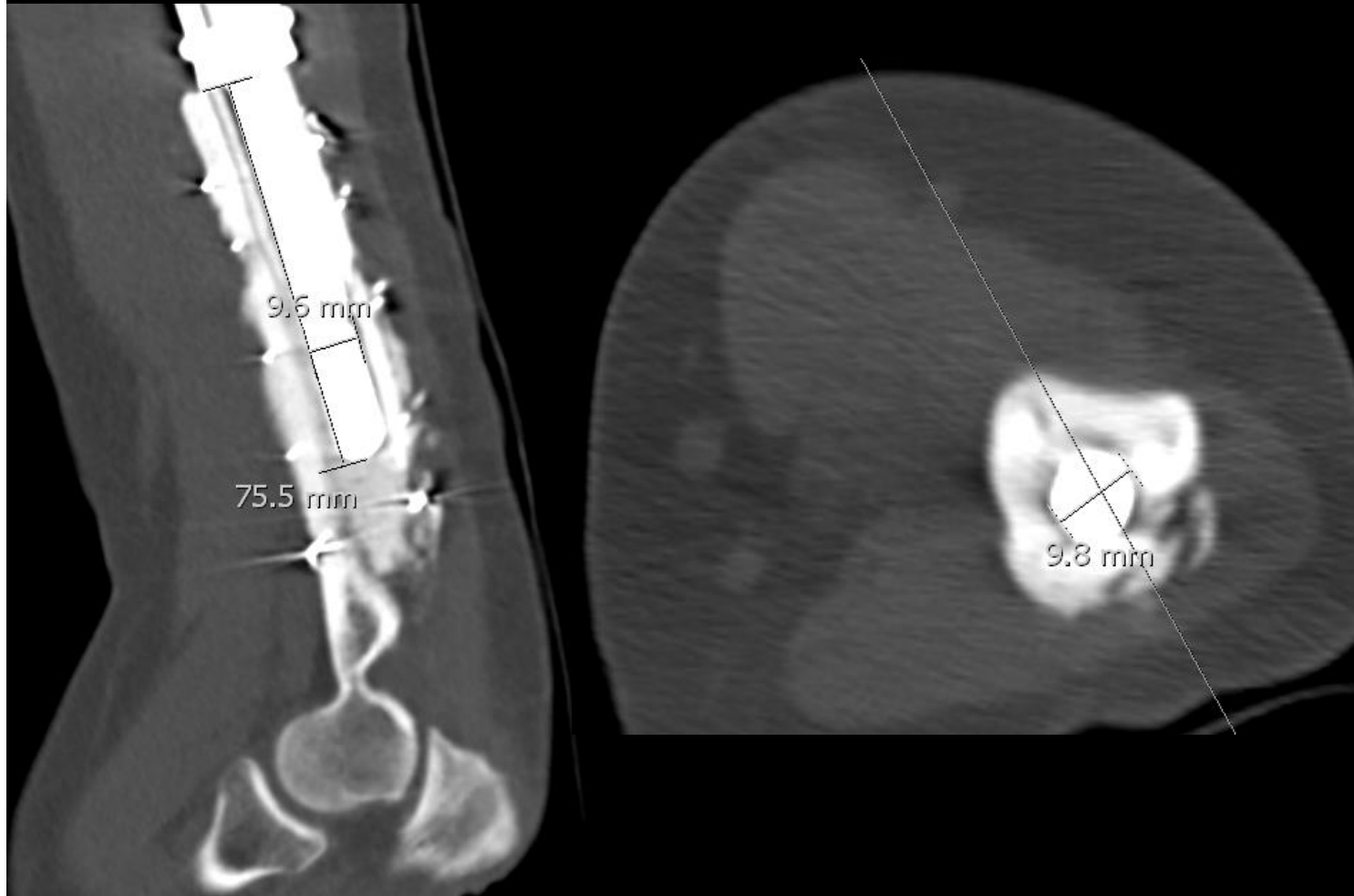Proximal Humerus



humerus; diaphyseal

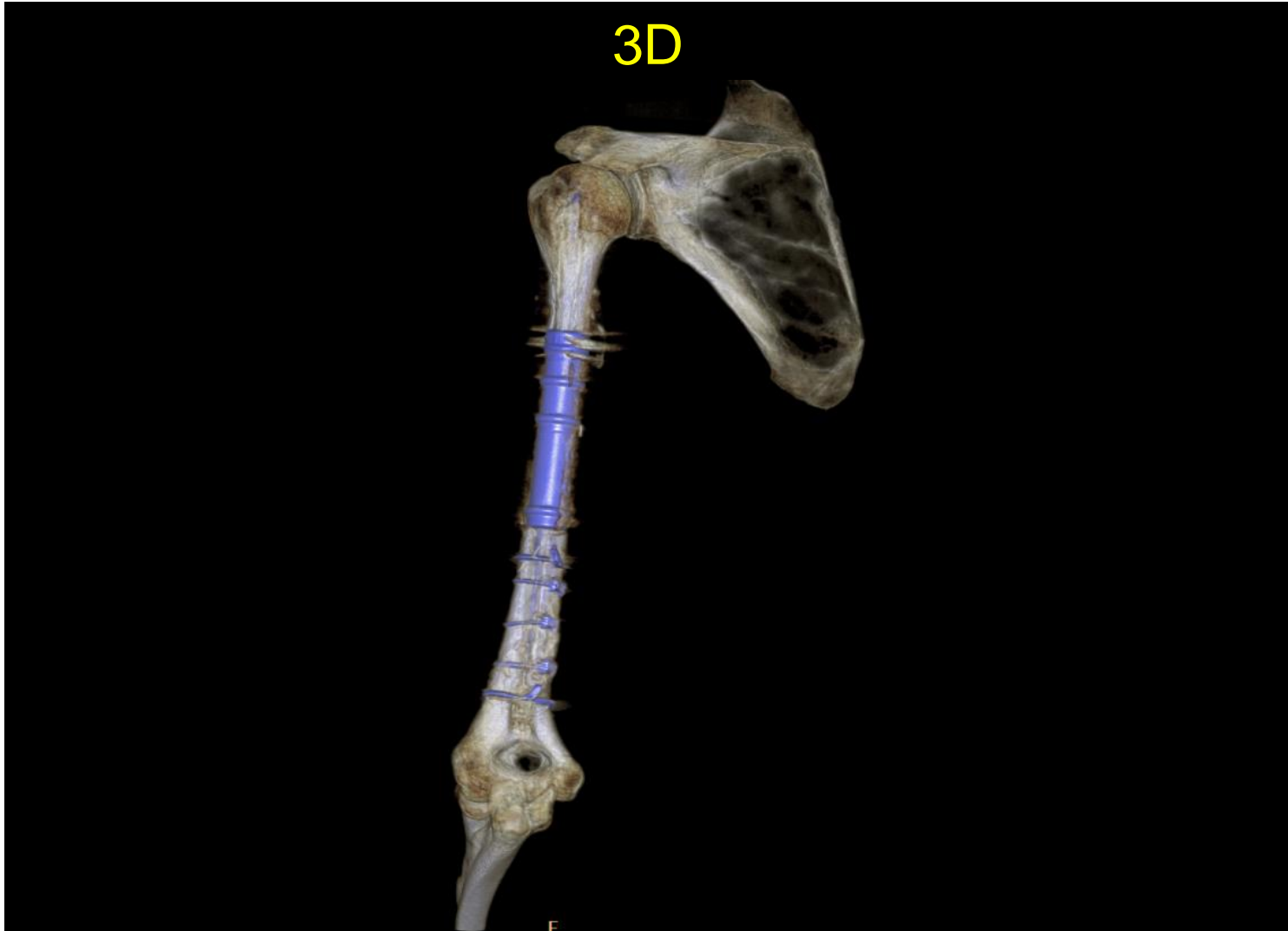
CT: February 22, 2013

Distal Humerus

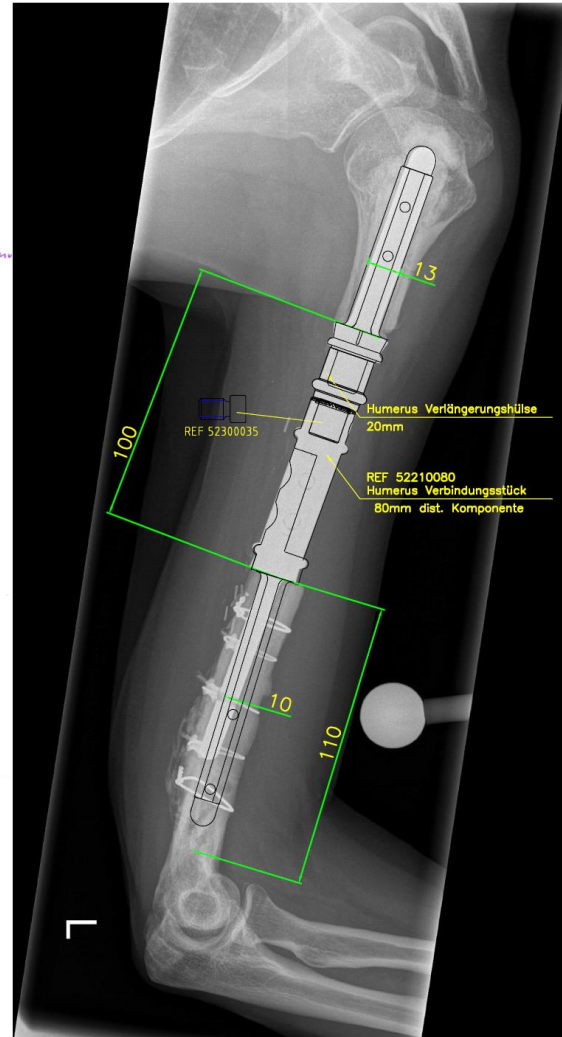
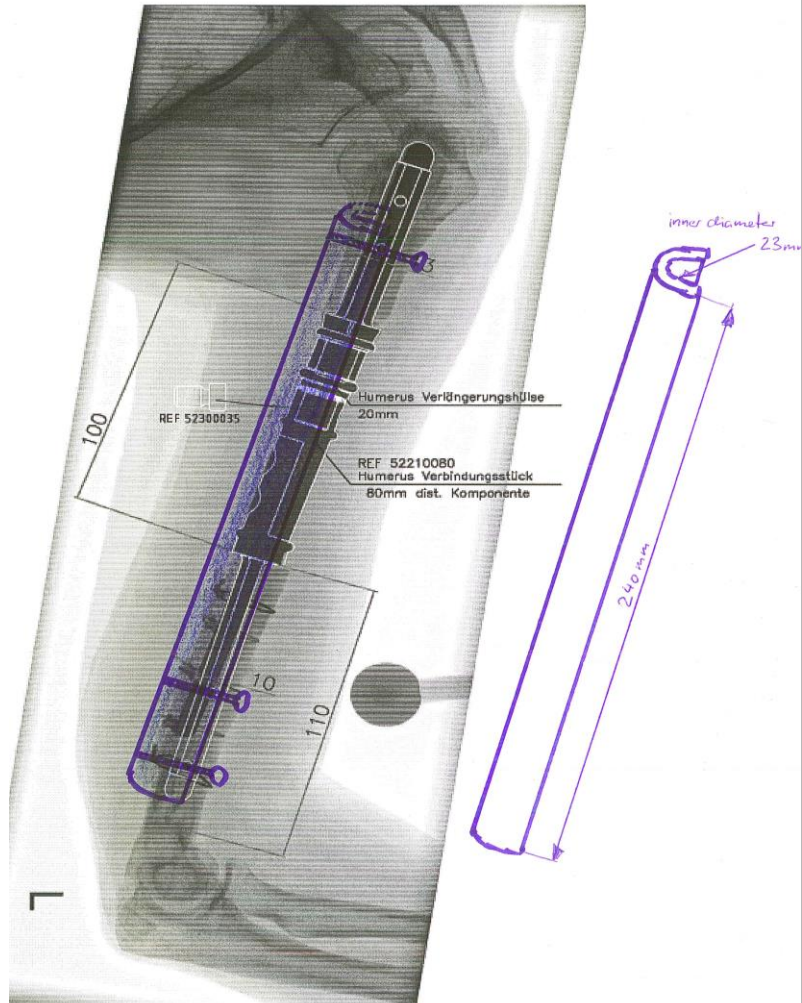


humerus; diaphyseal

CT: February 22, 2013



humerus; diaphyseal Surgery: Jun 18, 2013



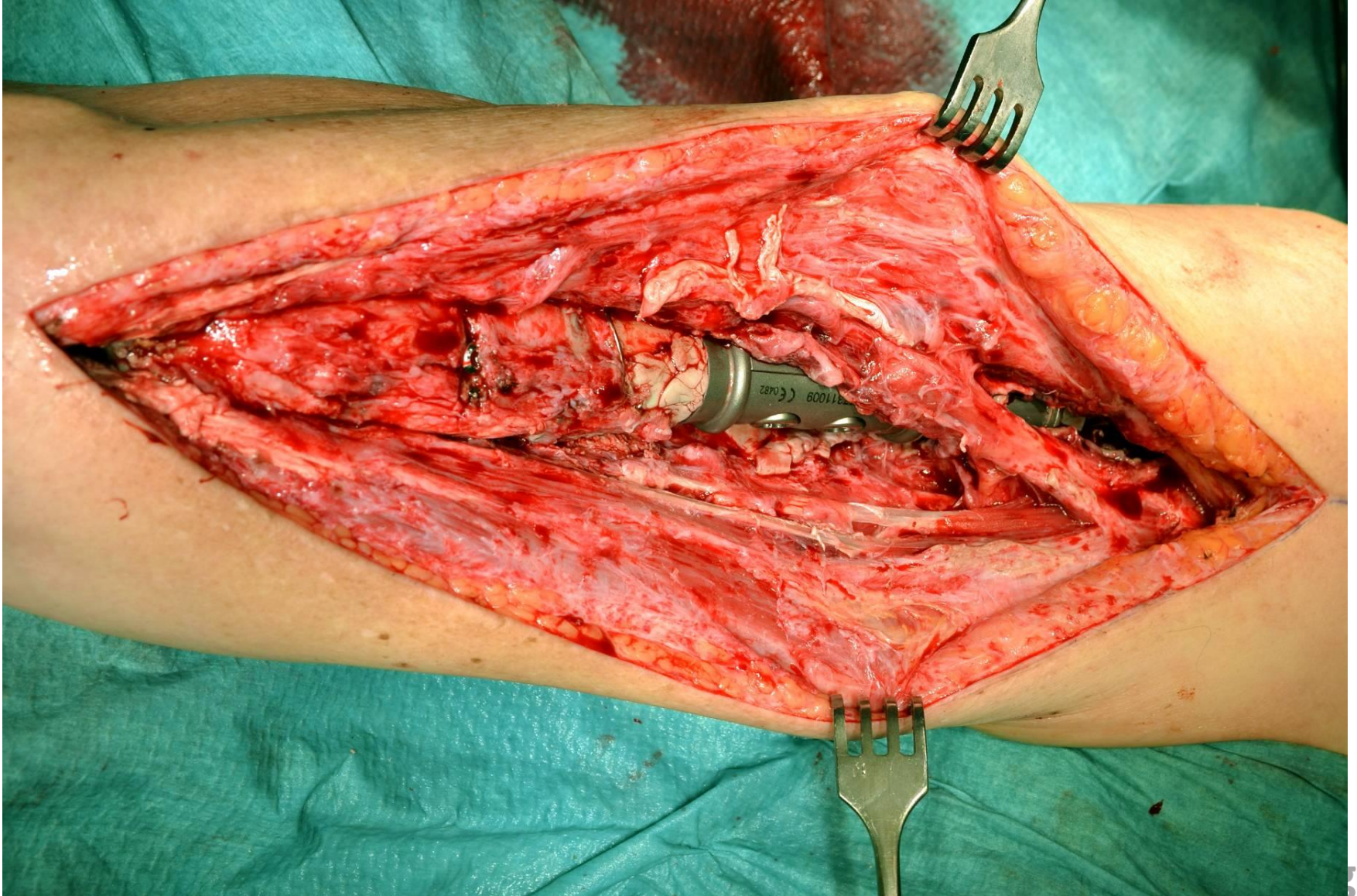
SA13057 Humerusdiaphysenimplantat
Klinik: Balgrist
Arzt: Dr. med. Reidy
Patient: ?
Datum: 08.04.13
Rekonstruktionslänge: 100mm
geplant von: P.S.

Implantate:

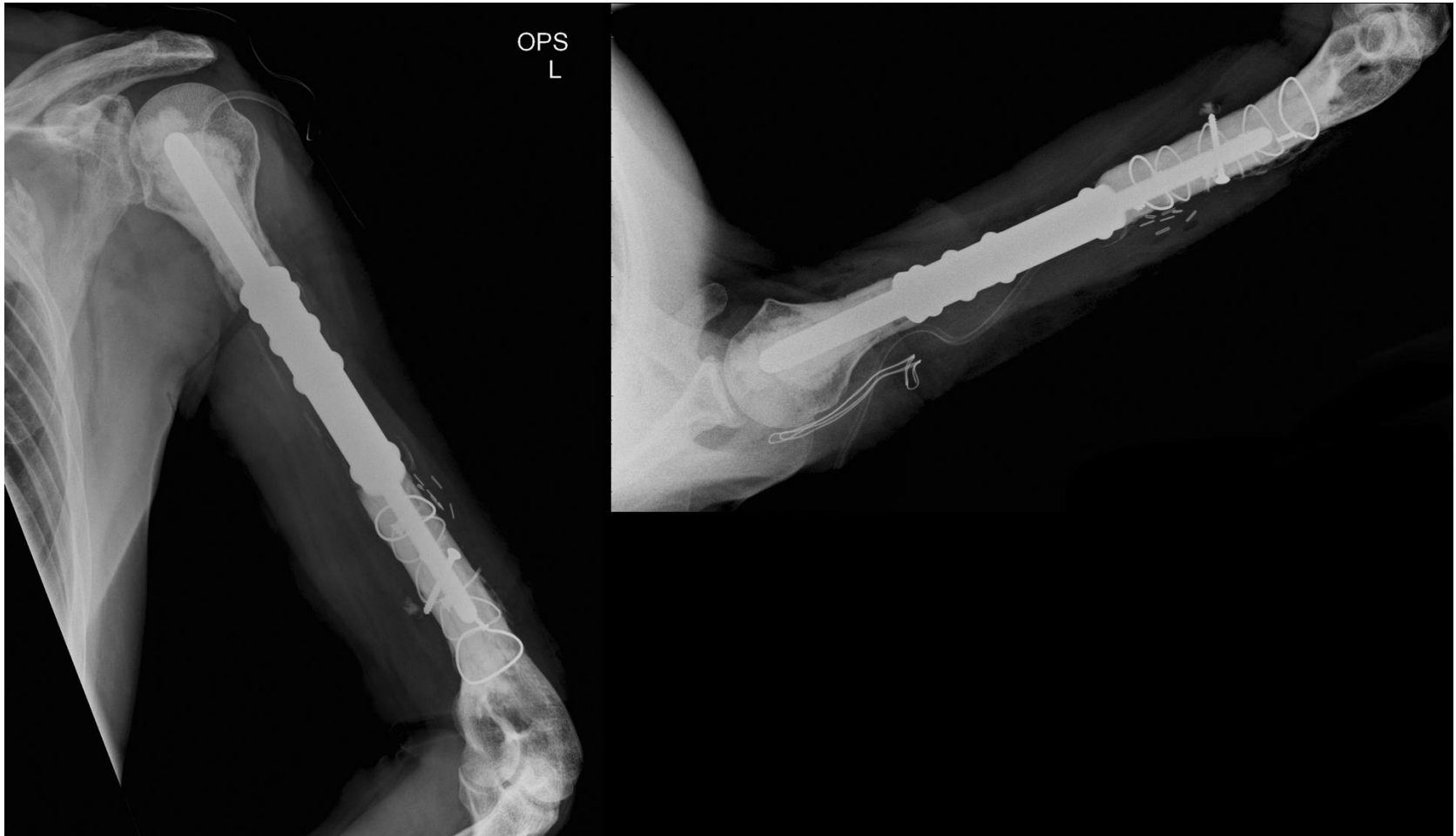SA Humerus Diaphysenimplantat
10/100mm zementiert
verriegelbar
SA Humerus Schaft 13/80mm zementiert
verriegelbar
Humerus Verlängerungshülse 20mm
Humerus Verbindungsstück 80mm
distale Komponente
Humerus Schraube M10x35mm

Diese OP-Planung soll dem Operateur eine Hilfestellung bei der Auswahl der benötigten Implantate bieten. Keinfall darf sie dazu verleiten, auf notwendige prä- oder intraoperative Verifizierungen zu verzichten. Die Planung wurde nach bestem Wissen sorgfältig durchgeführt. Eine Verantwortung für das Ergebnis kann jedoch nicht übernommen werden.

humerus; diaphyseal Surgery: Jun 18, 2013



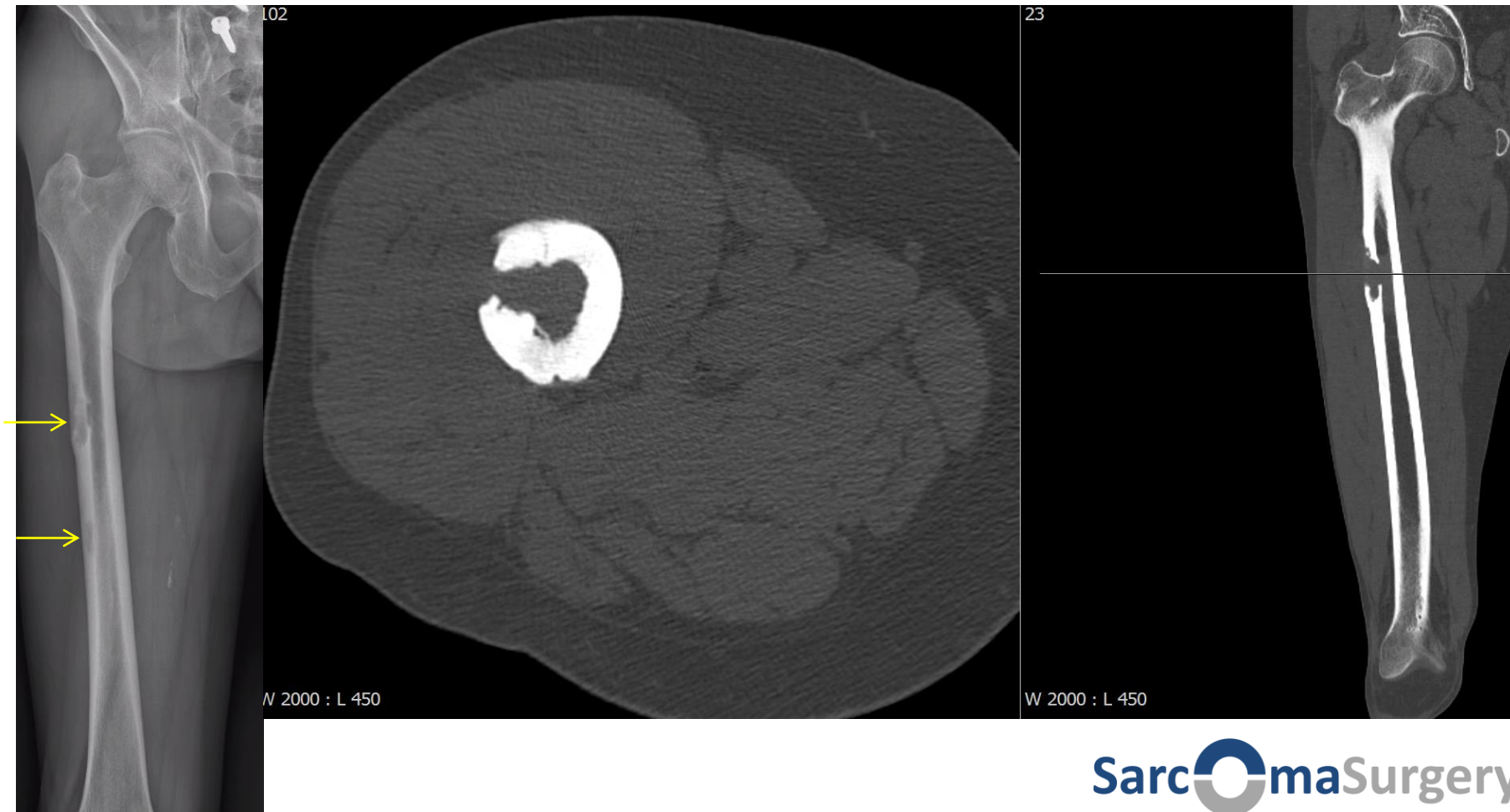
humerus; diaphyseal Surgery: Jun 18, 2013



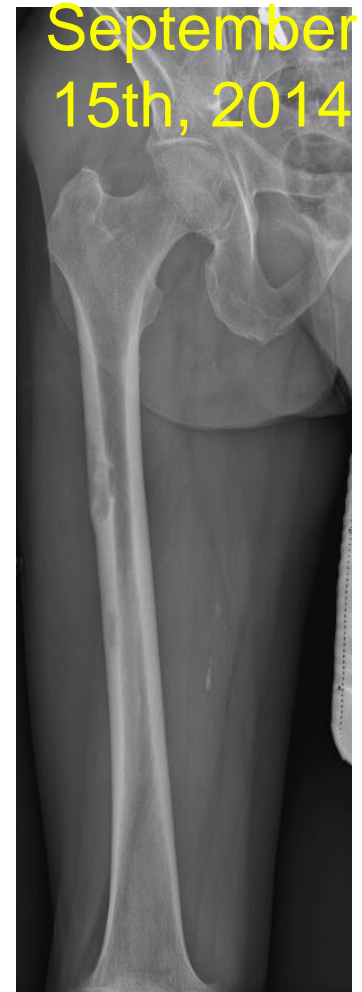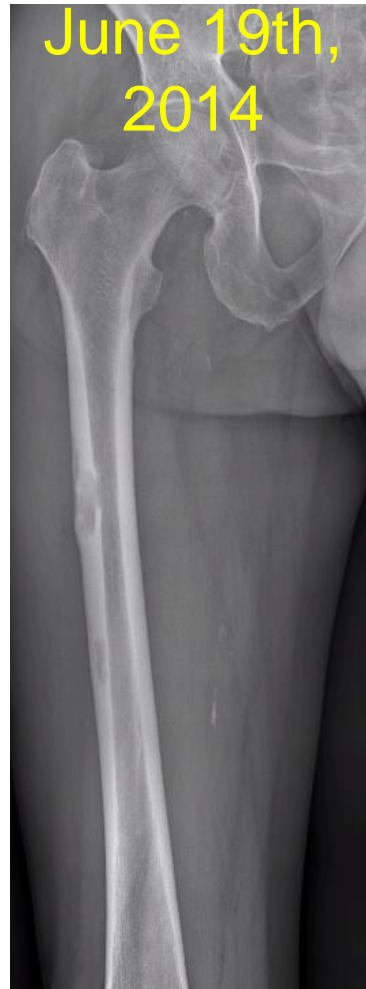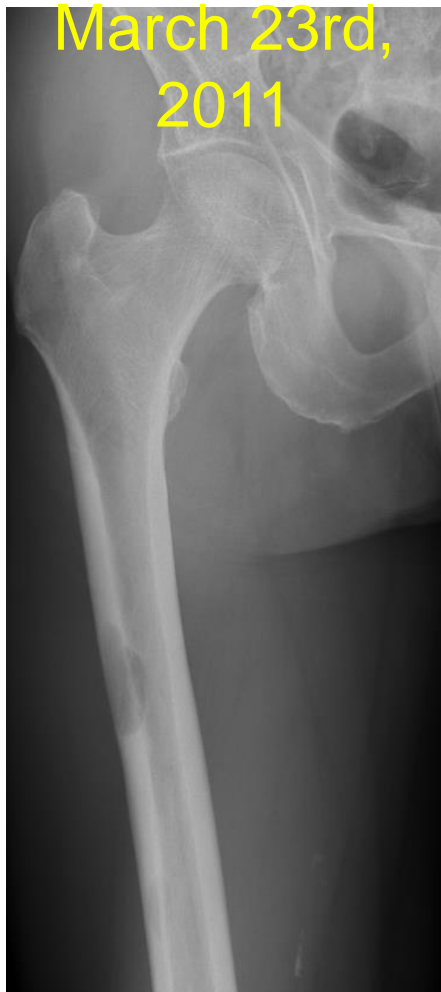humerus; diaphyseal

September 15th, 2014

- One wrong step to the back - pain in right thigh
- Weightbearing is not possible

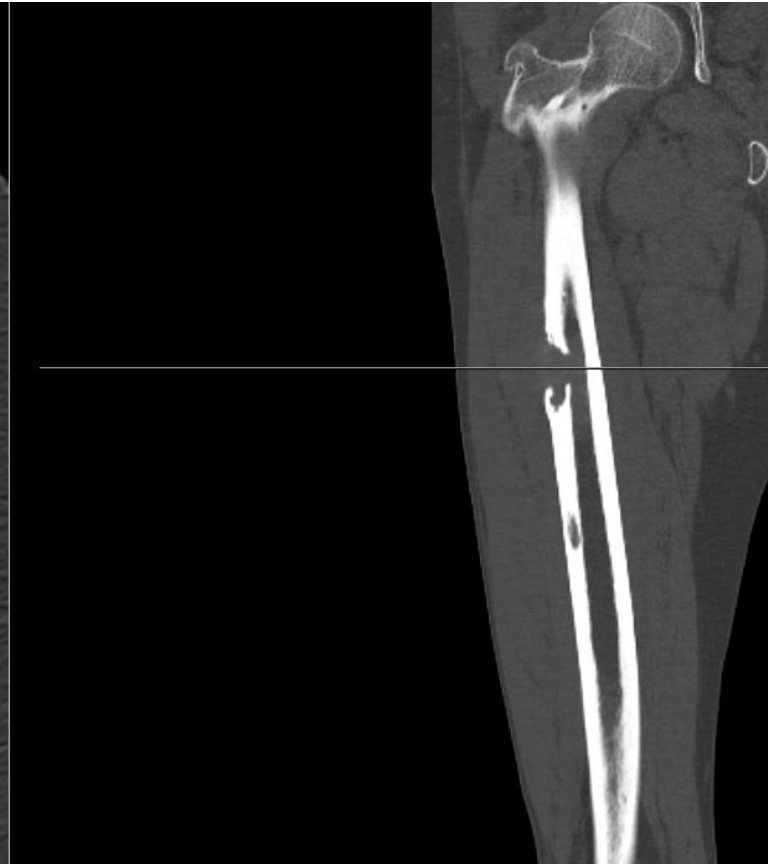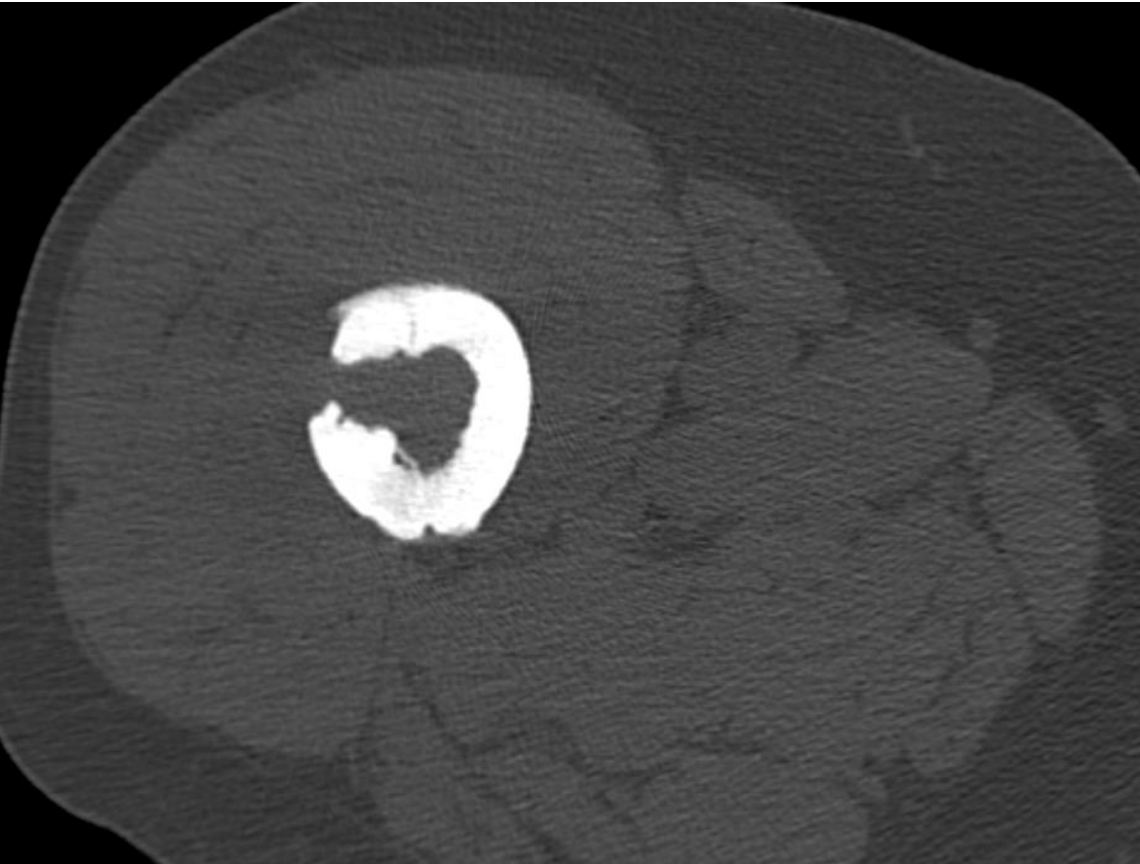


humerus; diaphyseal X-RAY

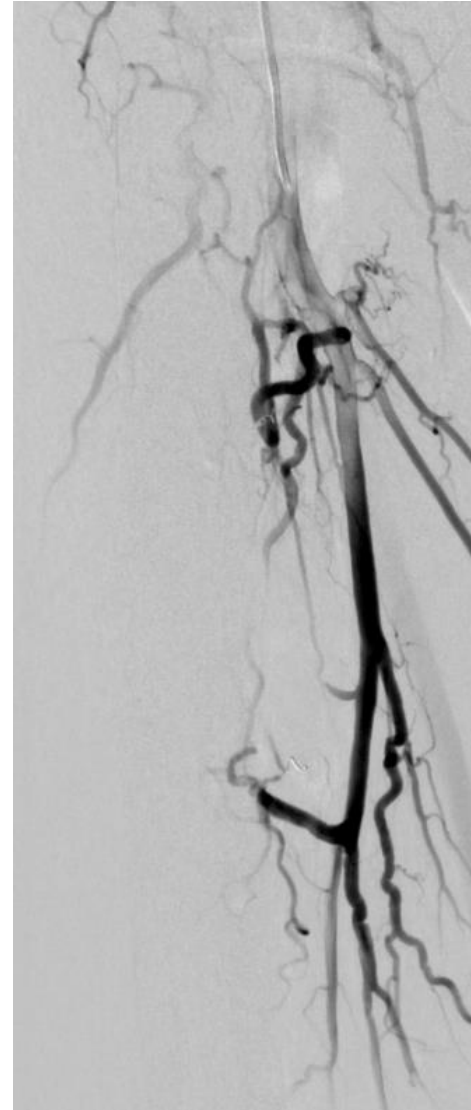

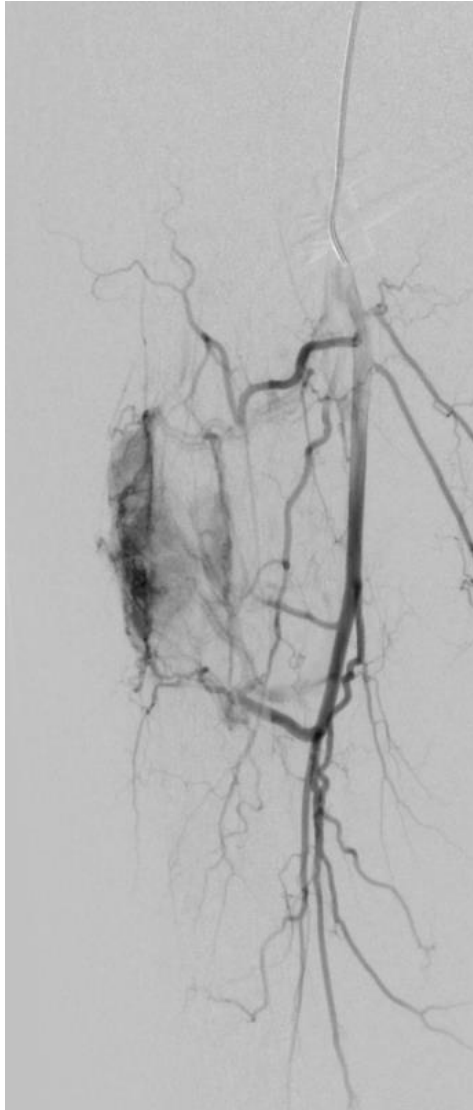


humerus; diaphyseal

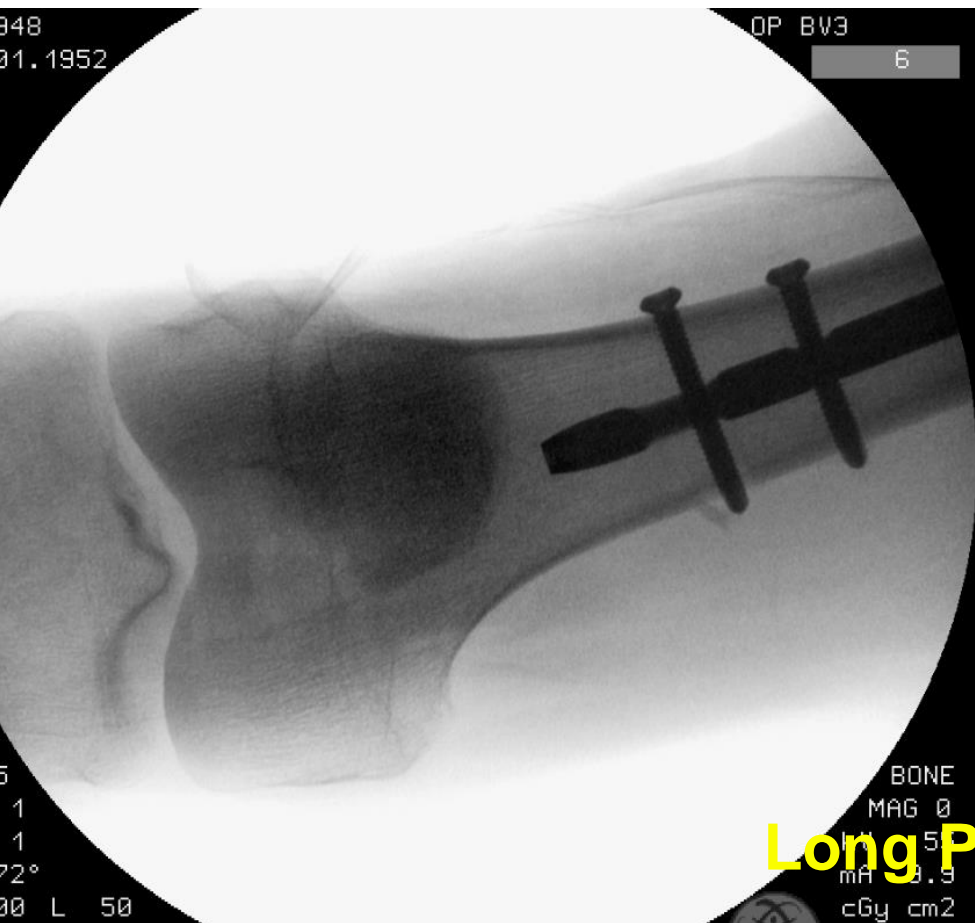CT September 15th, 2014



humerus; diaphyseal EMBOLISATION September 16th, 2014



humerus; diaphyseal SURGERY September 16th, 2014



Long PFNA

