

Scapula; partial glenoid resection

♀ 51y

**1990 and 2000 Resection of
osteochondroma R scapula**

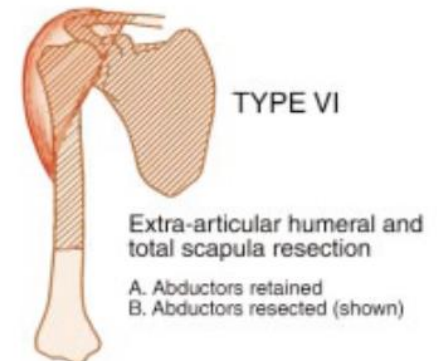
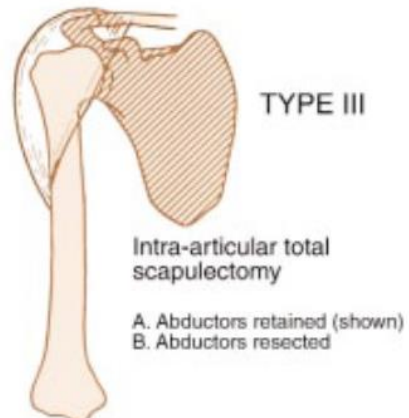
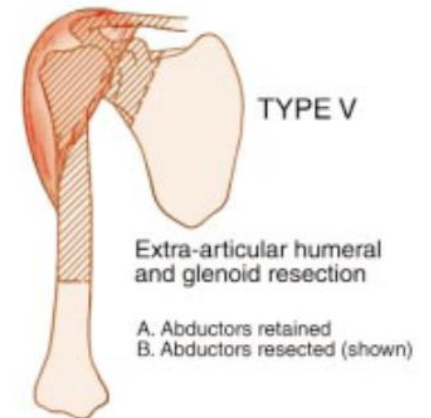
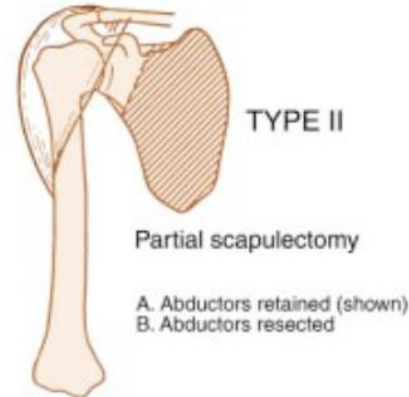
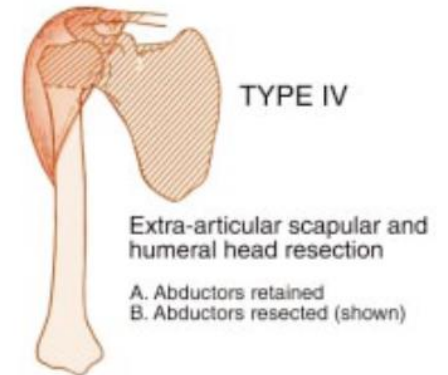
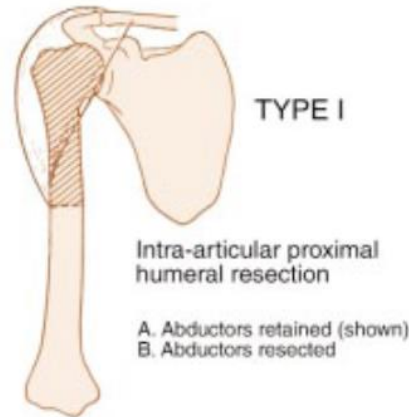
**2 month history of R shoulder pain at
night/supine and at overhead work**

**Free ROM with little pain for abduction
and flexion**

axillary nerve?

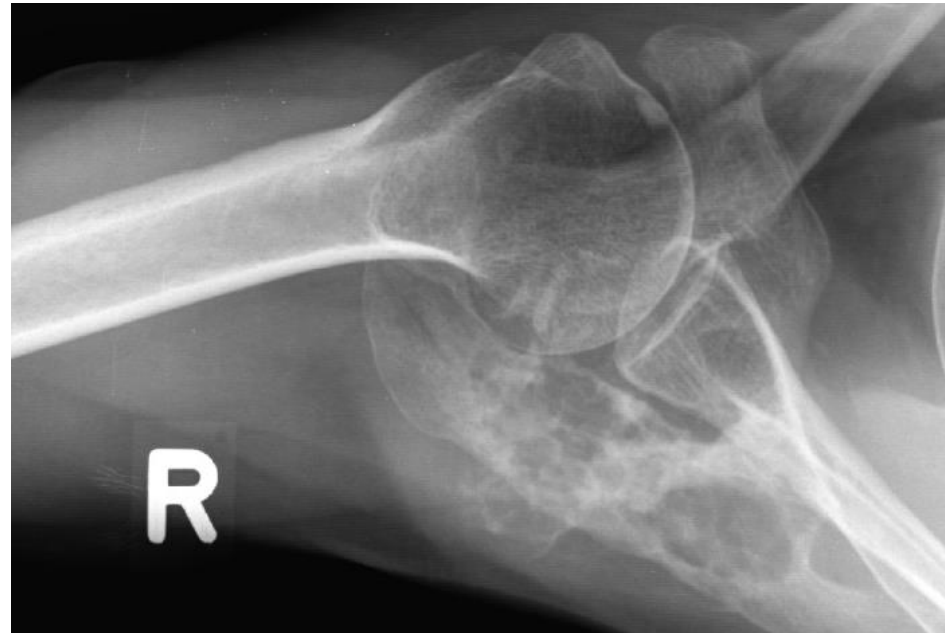
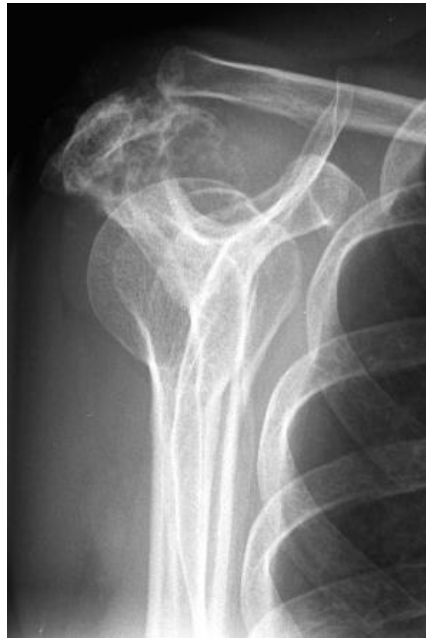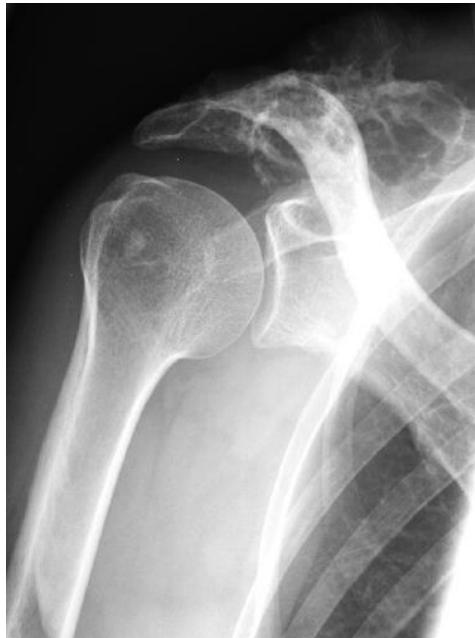intra- / transarticular?

level of OT & abductor?



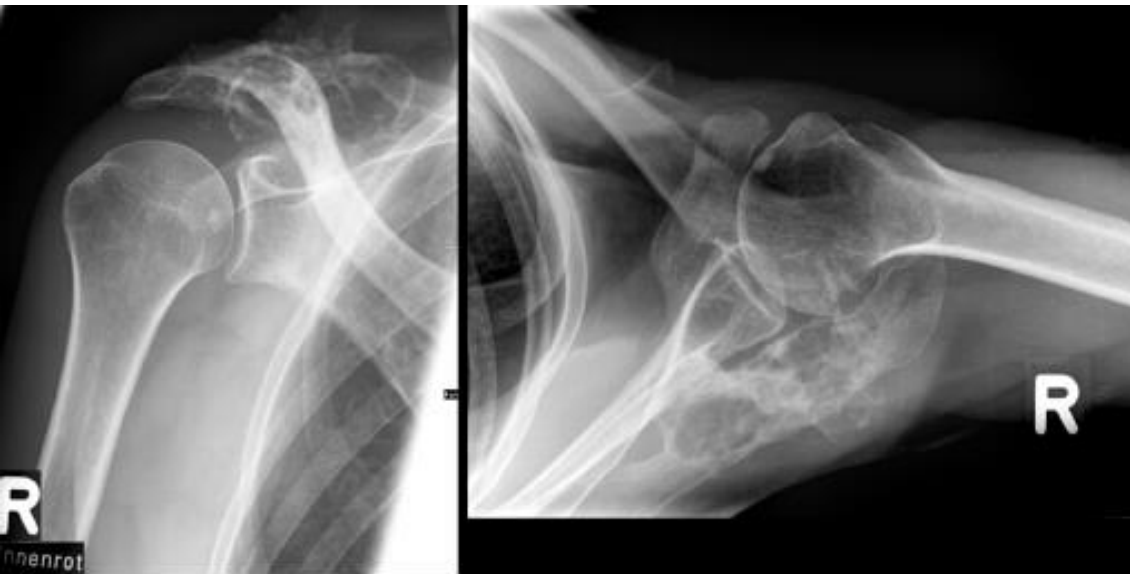
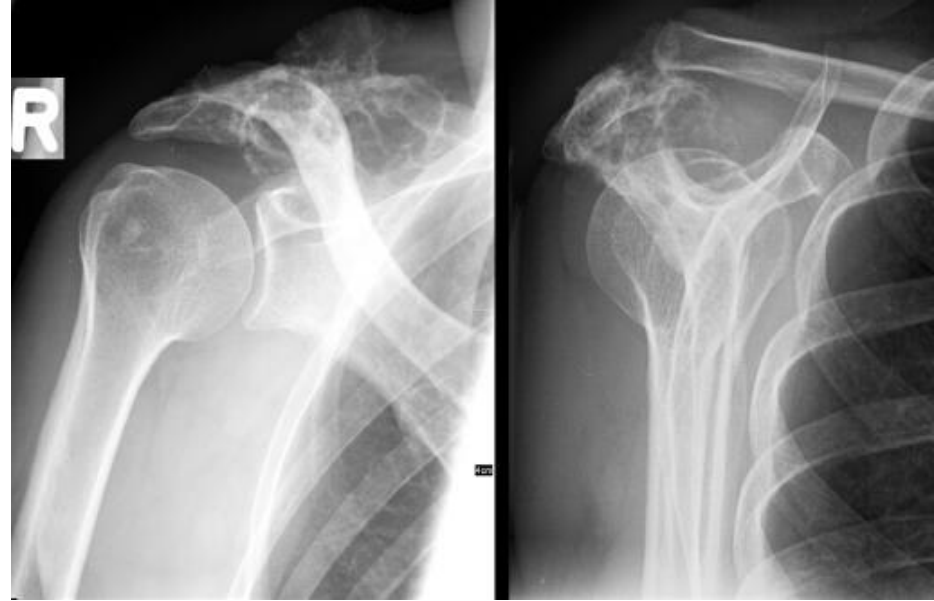Scapula; partial glenoid resection

Xray, Mar 18, 2008

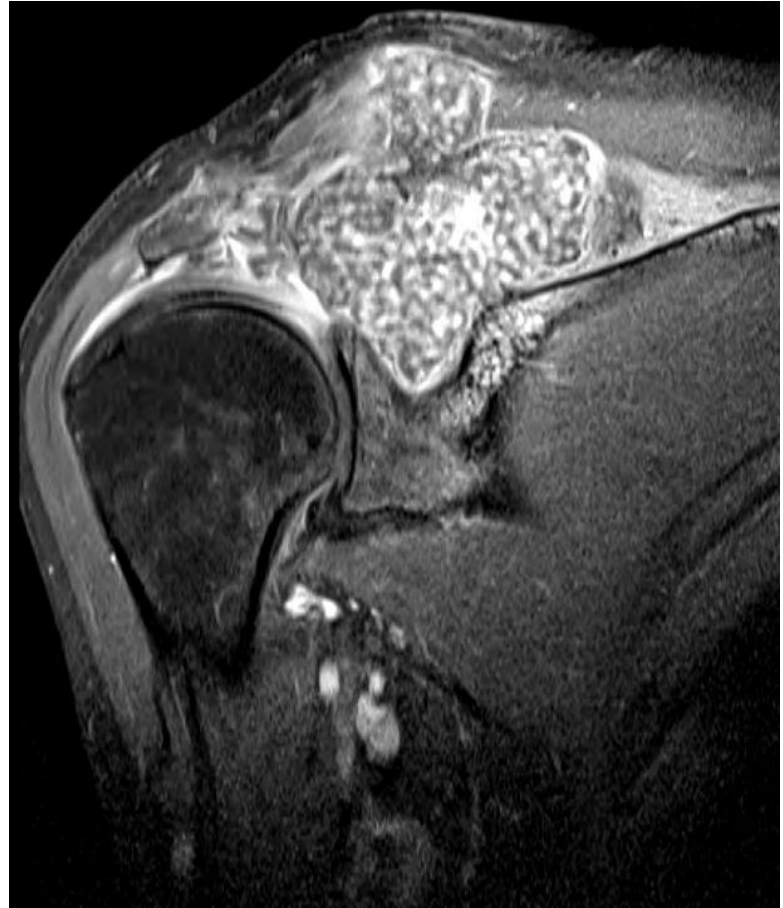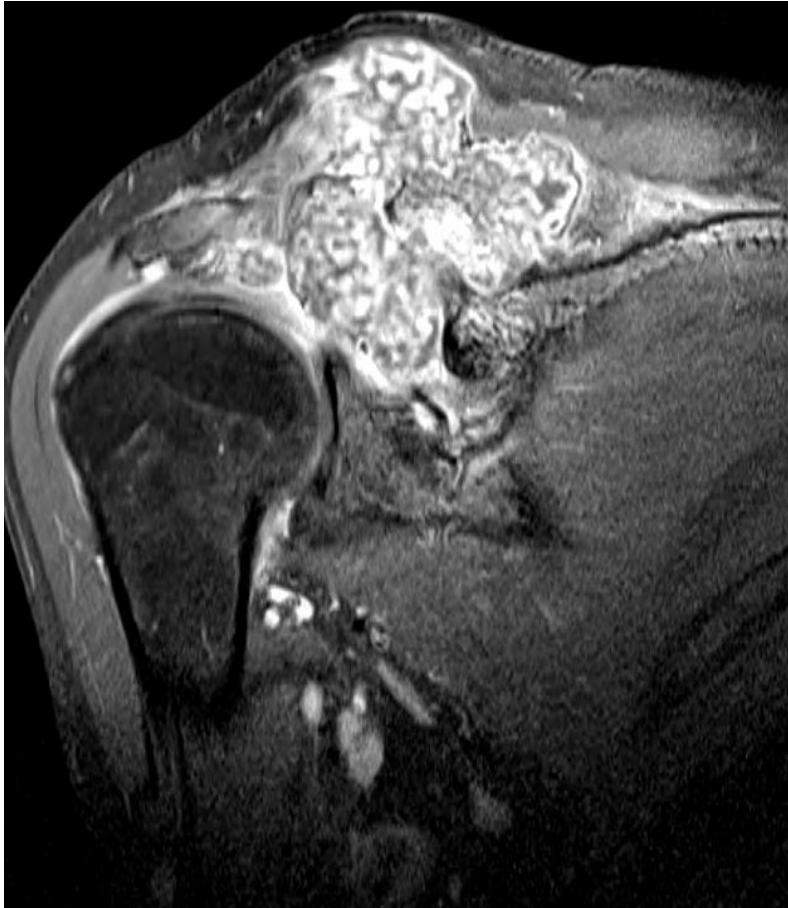


Scapula; partial glenoid resection

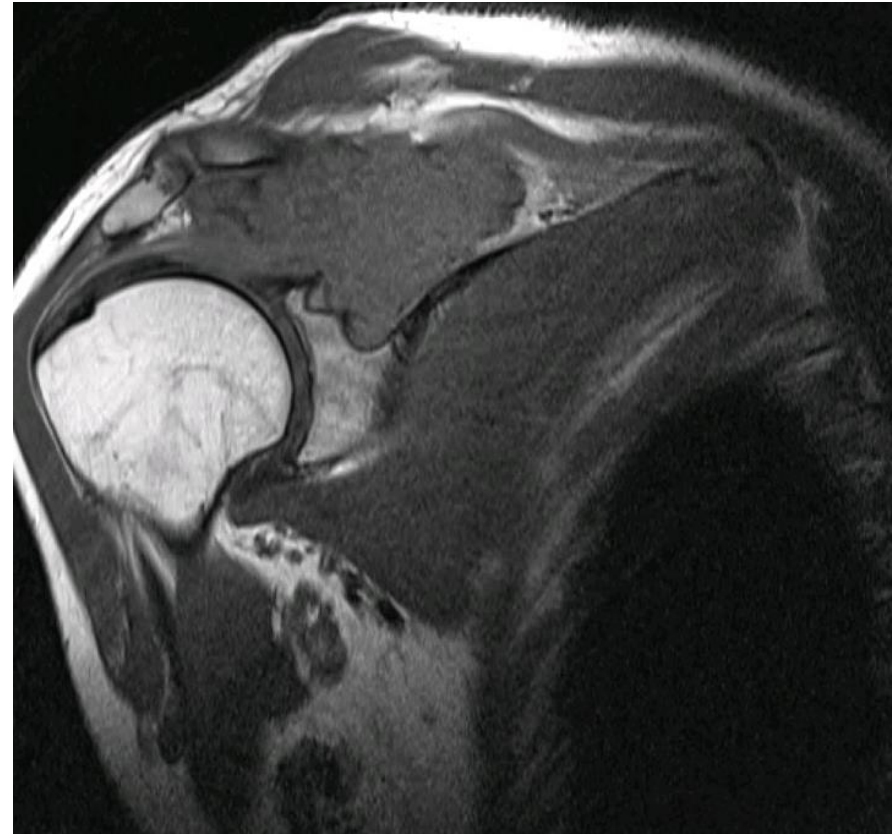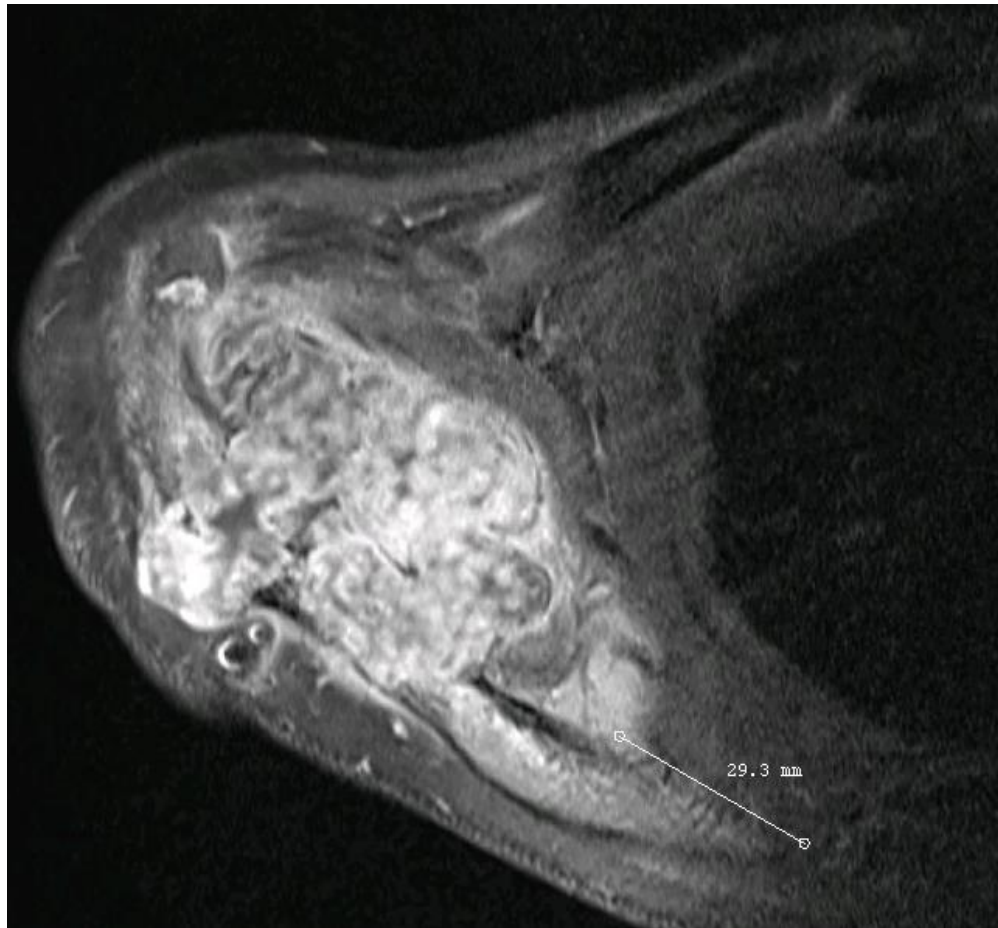
Xray, Mar 18, 2008



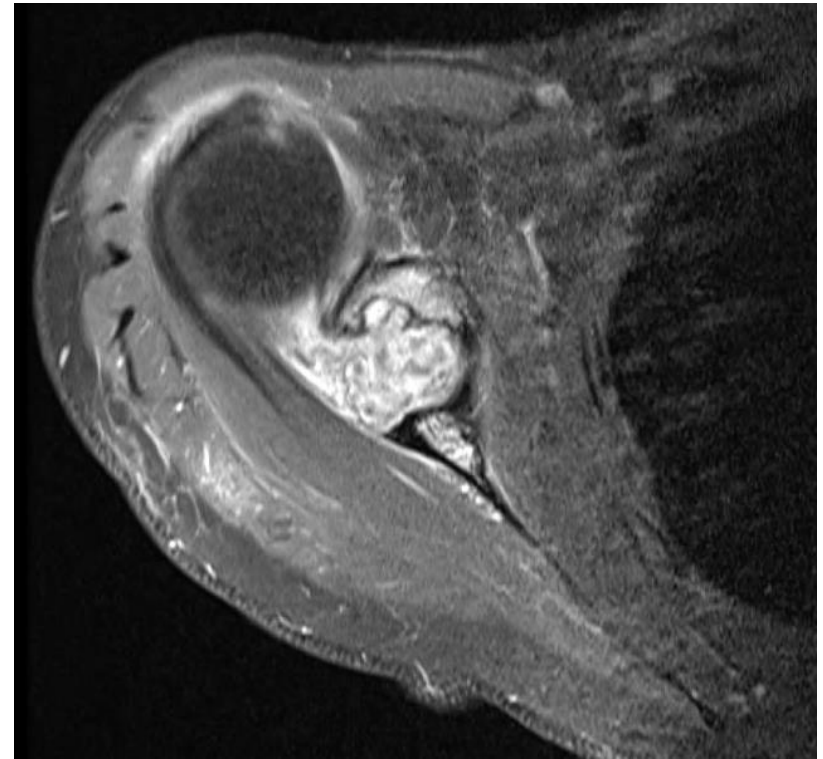
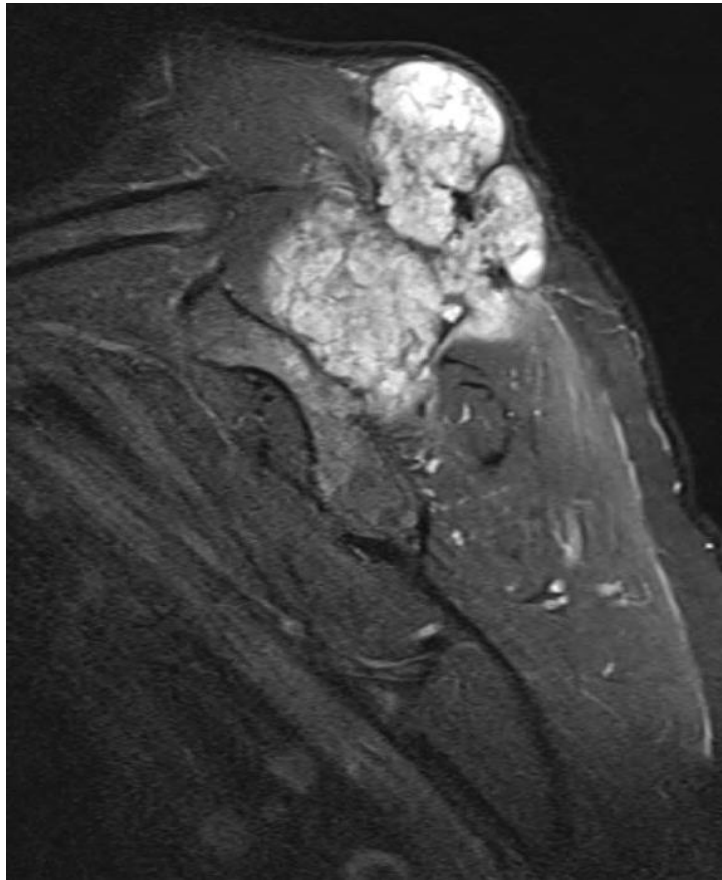
Scapula; partial glenoid resection MRI shoulder, May 16, 2008

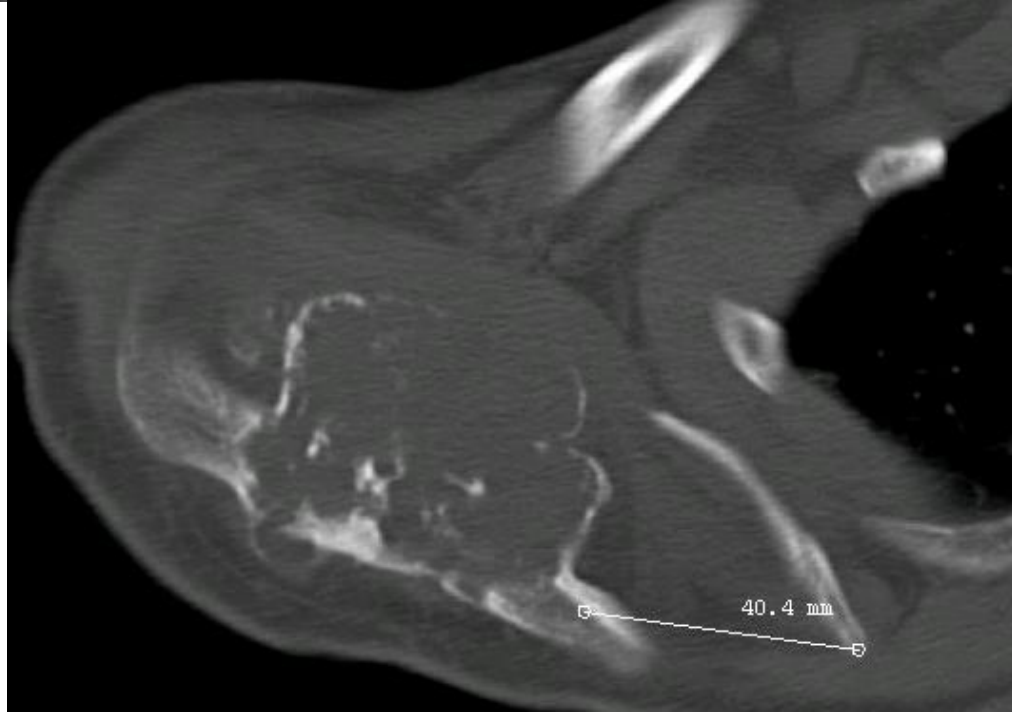
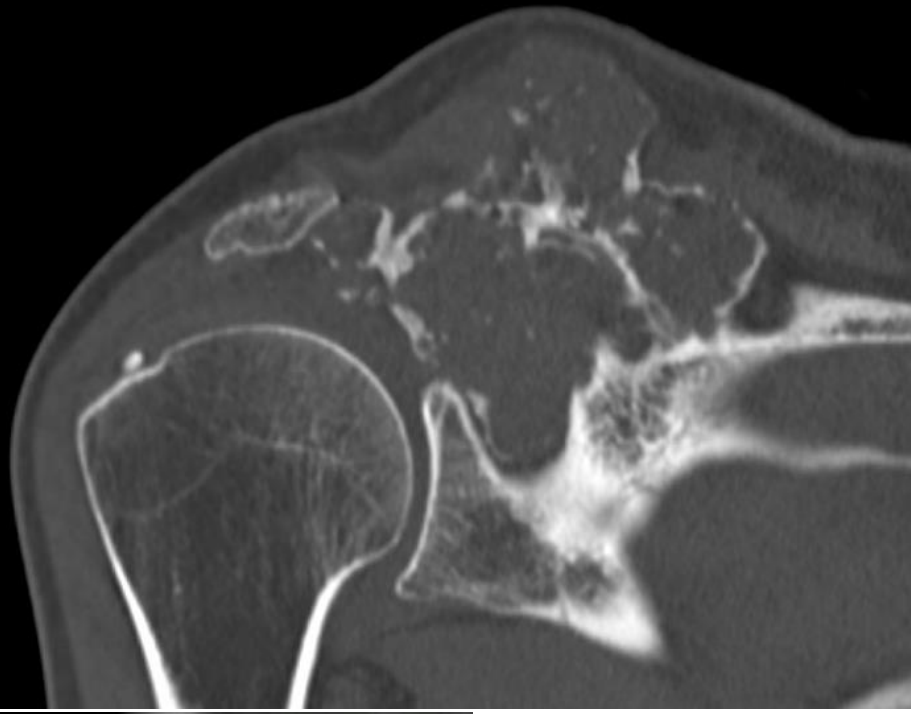
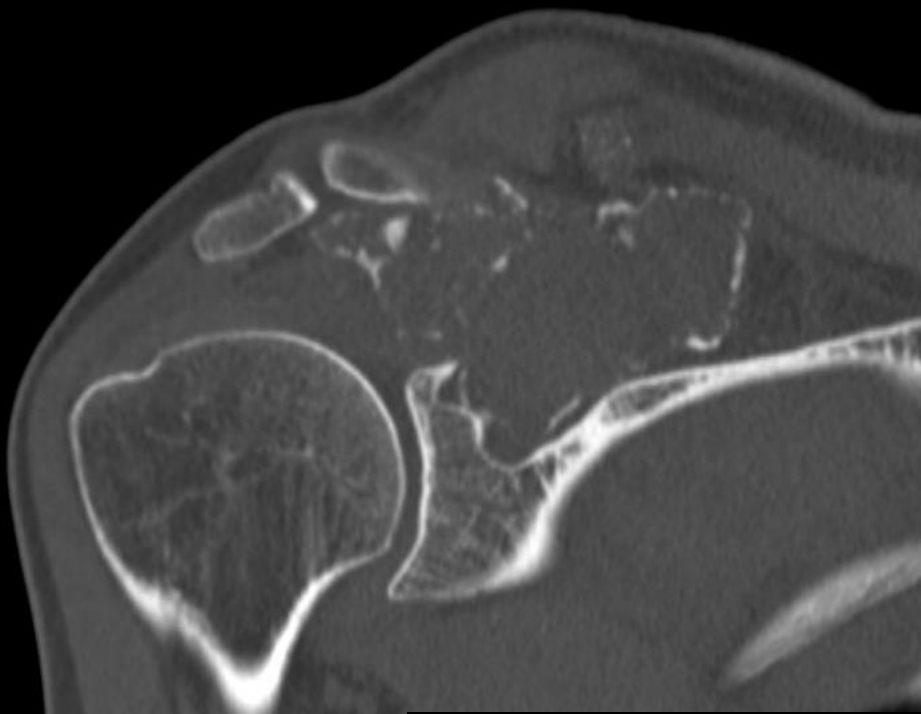


Scapula; partial glenoid resection MRI shoulder, May 16, 2008

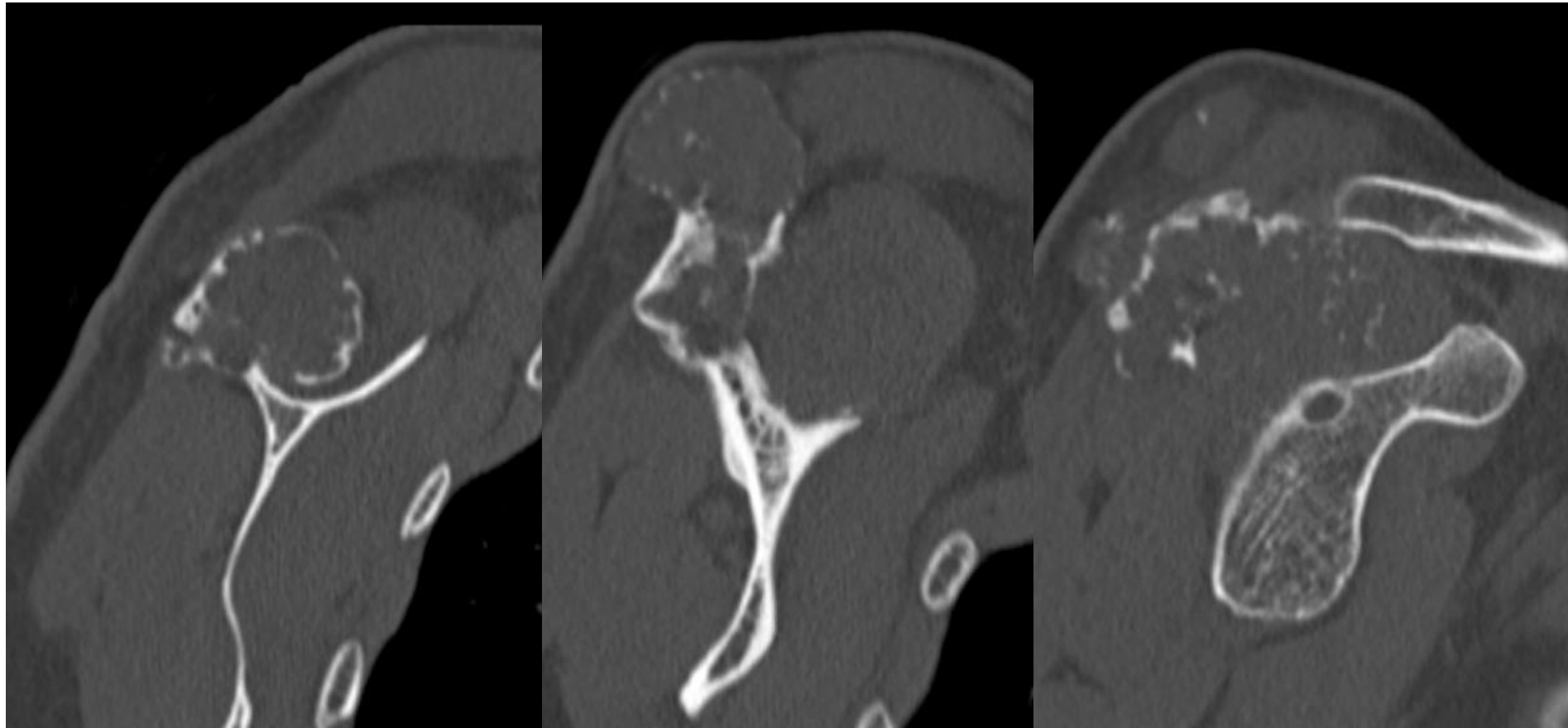


Scapula; partial glenoid resection MRI shoulder, May 16, 2008

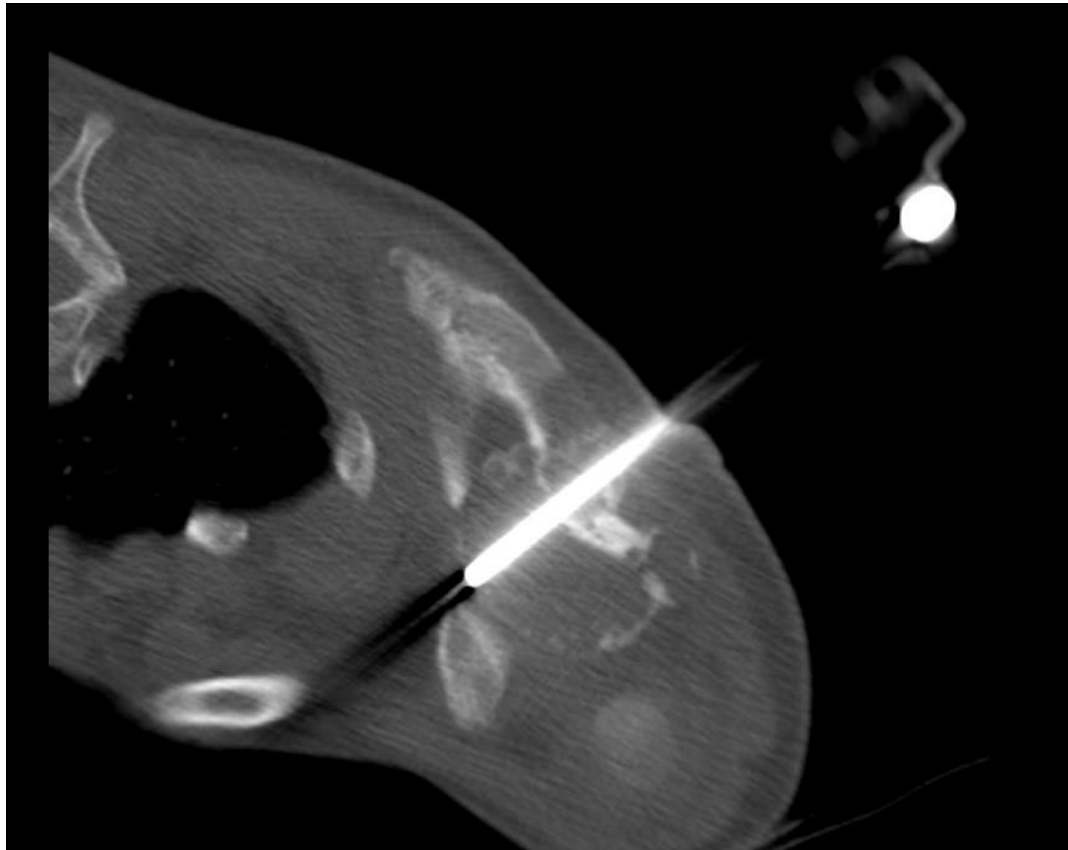




Scapula; partial glenoid resection CT chest, May 16, 2008



Scapula; partial glenoid resection CT BIOPSY 23.5.08



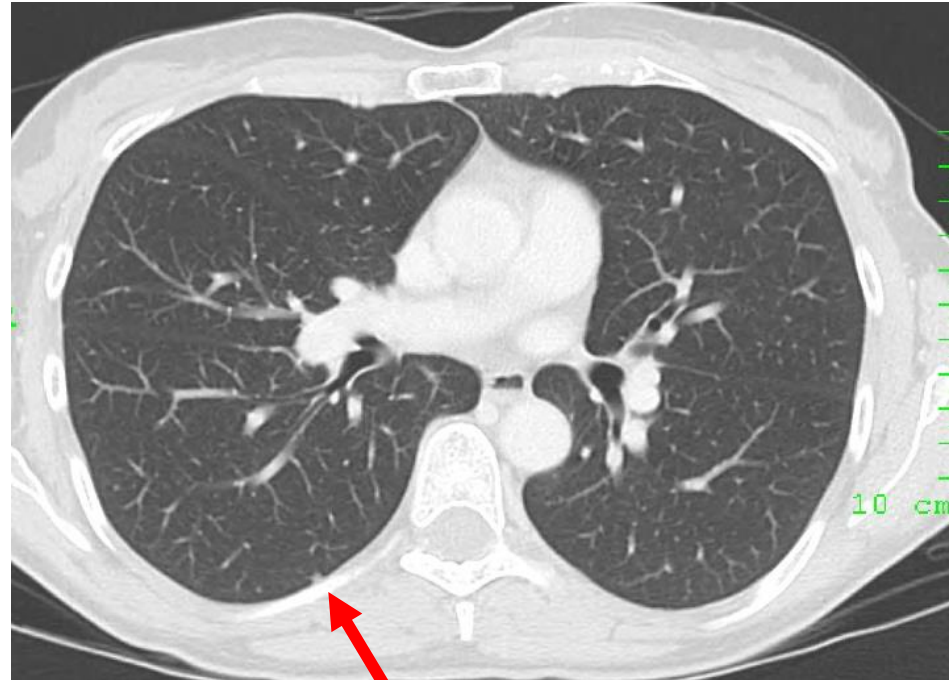
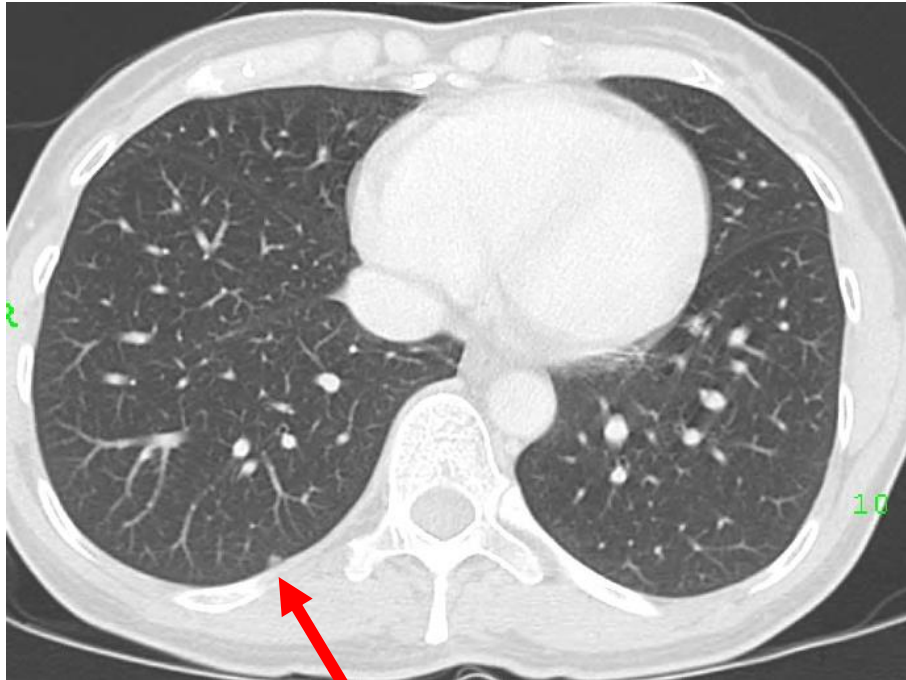
Scapula; partial glenoid resection

24.6.08 Biopsy

conventional low grade chondrosarcoma

Scapula; partial glenoid resection

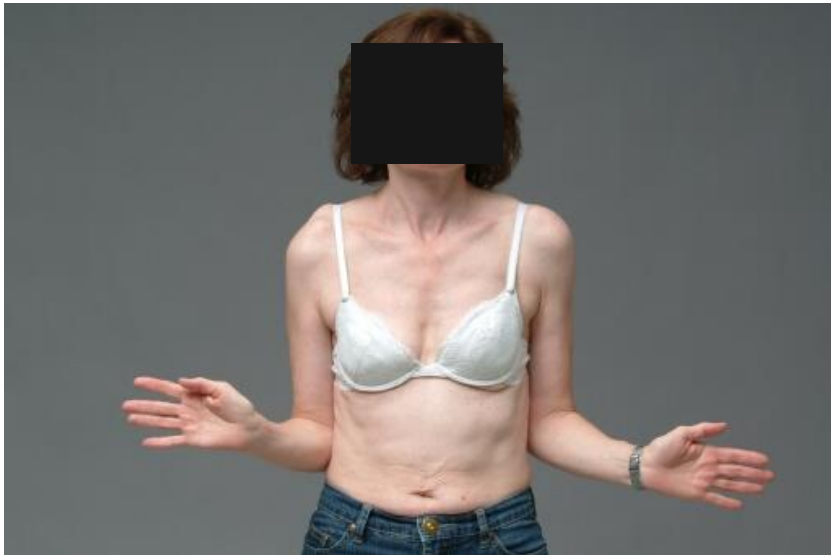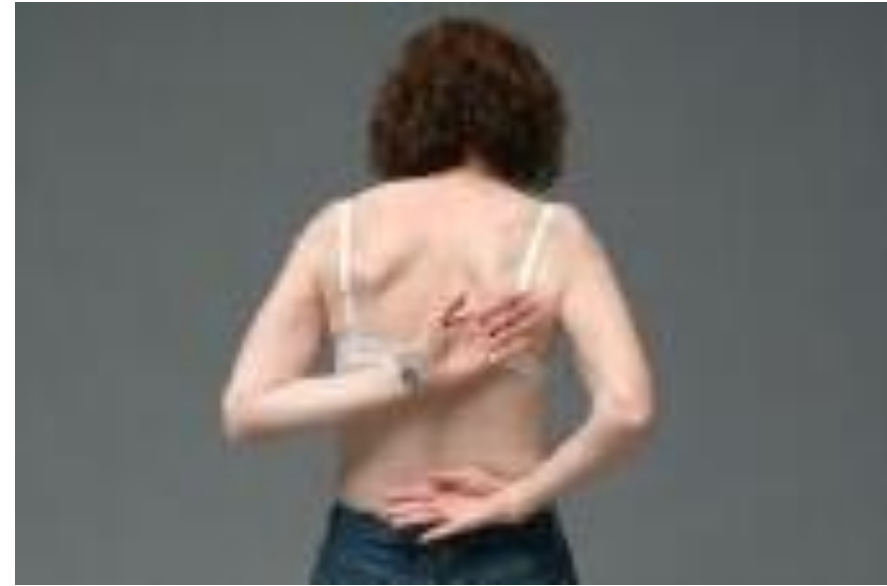CT chest, June 11, 2008



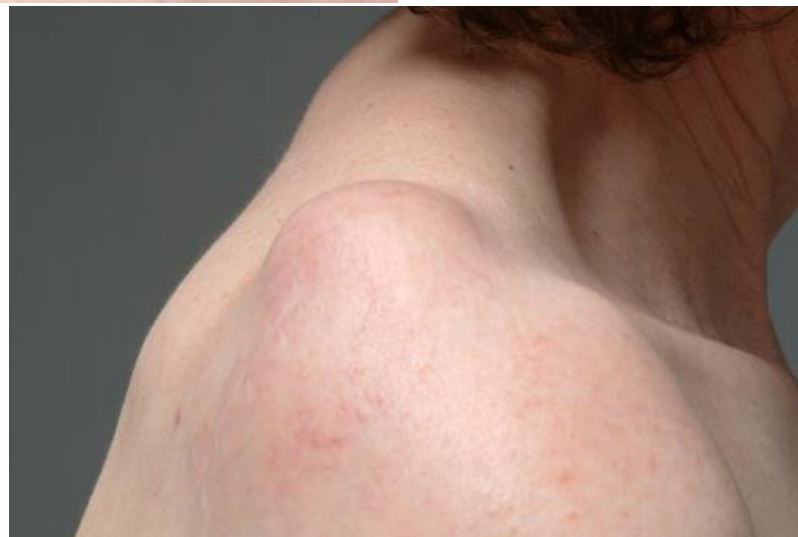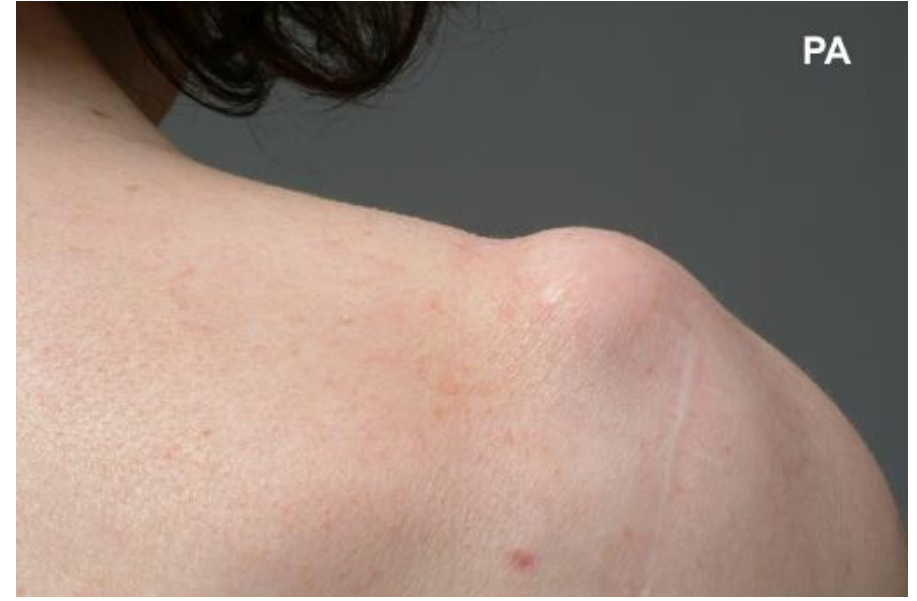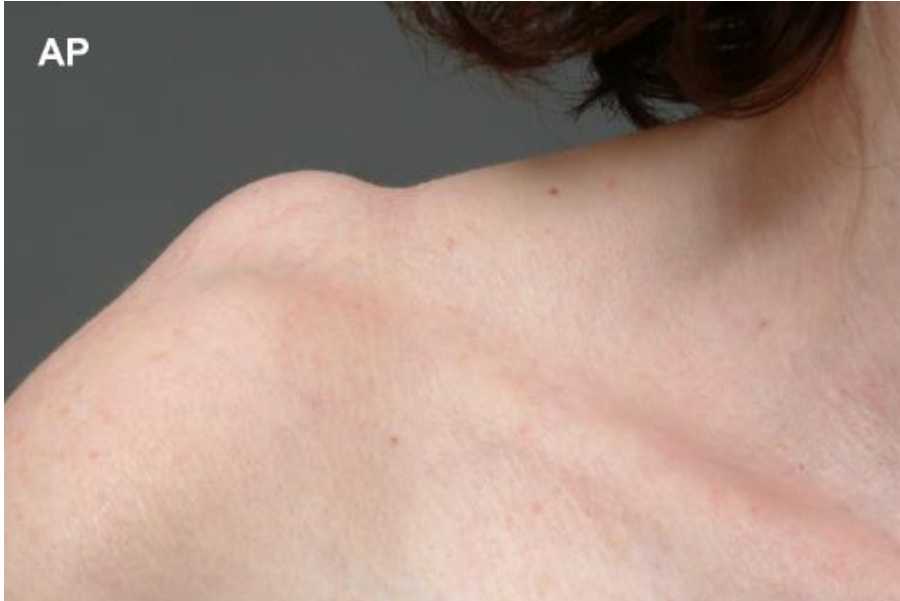indeterminate nodules

Scapula; partial glenoid resection

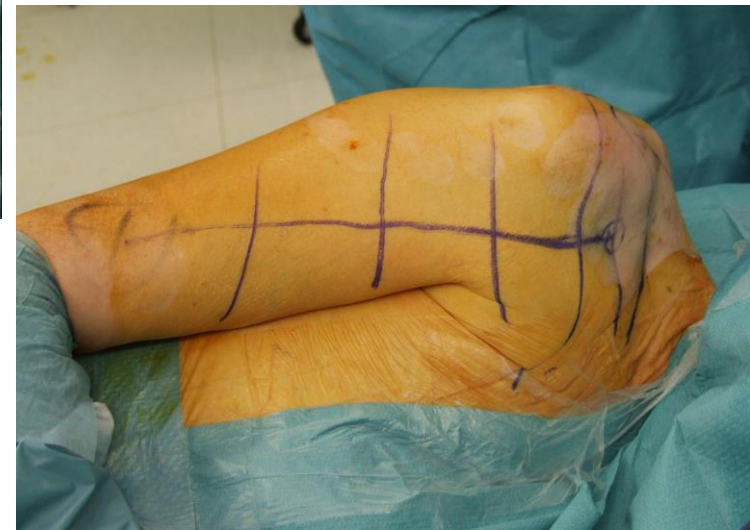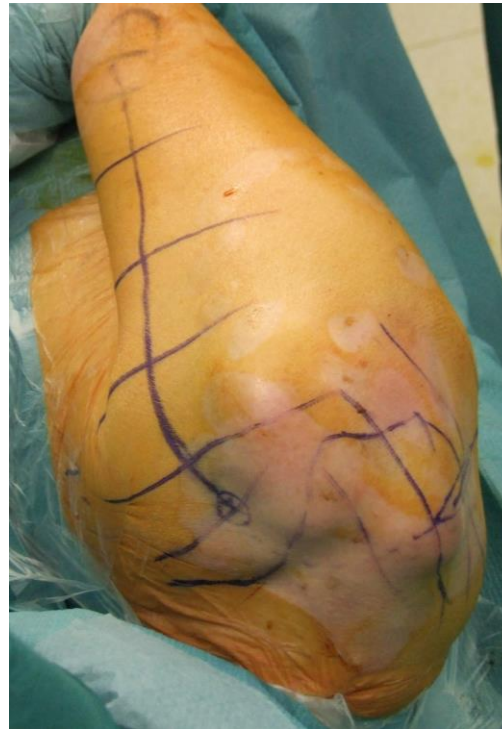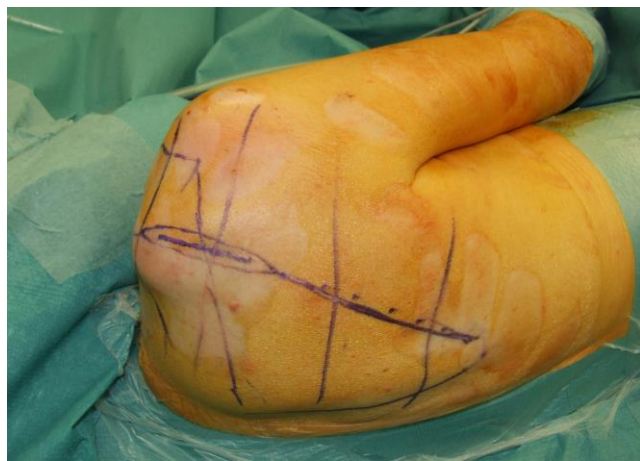1 day pre-OP, July 23, 2008

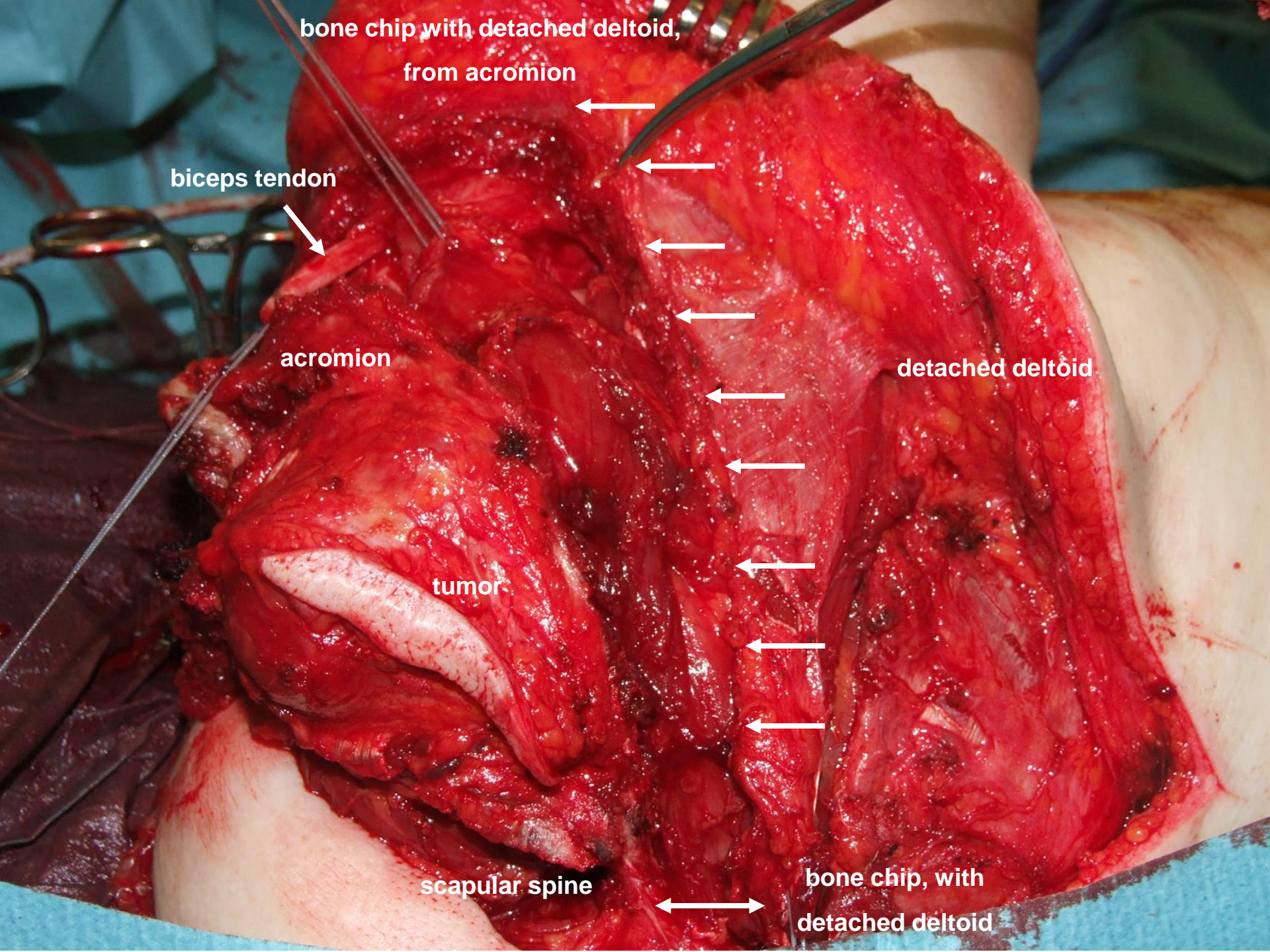


Scapula; partial glenoid resection 1 day pre-OP, July 23, 2008



Scapula; partial glenoid resection surgery, July 24, 2008





bone chip with detached deltoid,
from acromion

biceps tendon

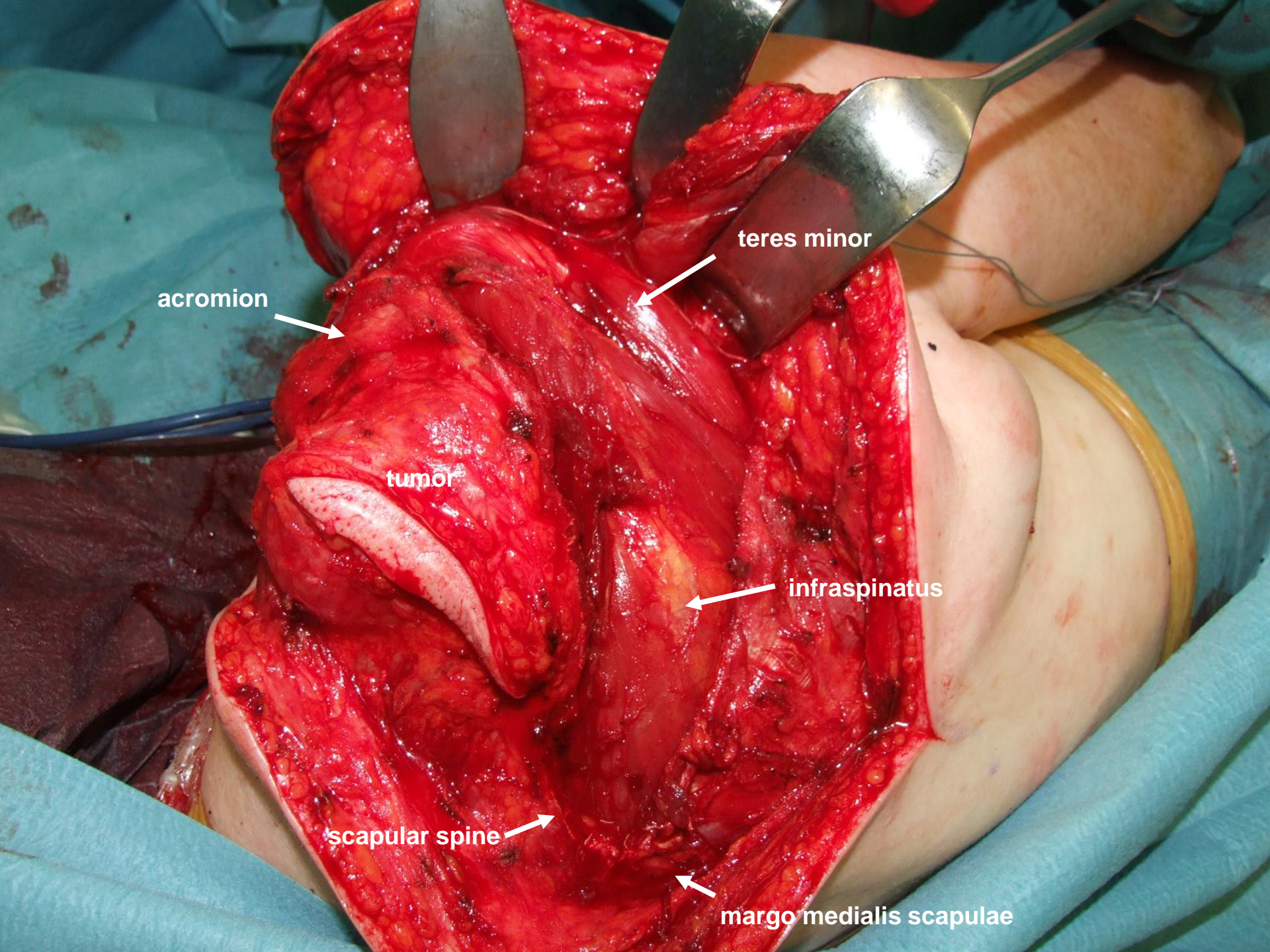
acromion

tumor

scapular spine

detached deltoid

bone chip, with
detached deltoid



acromion

teres minor

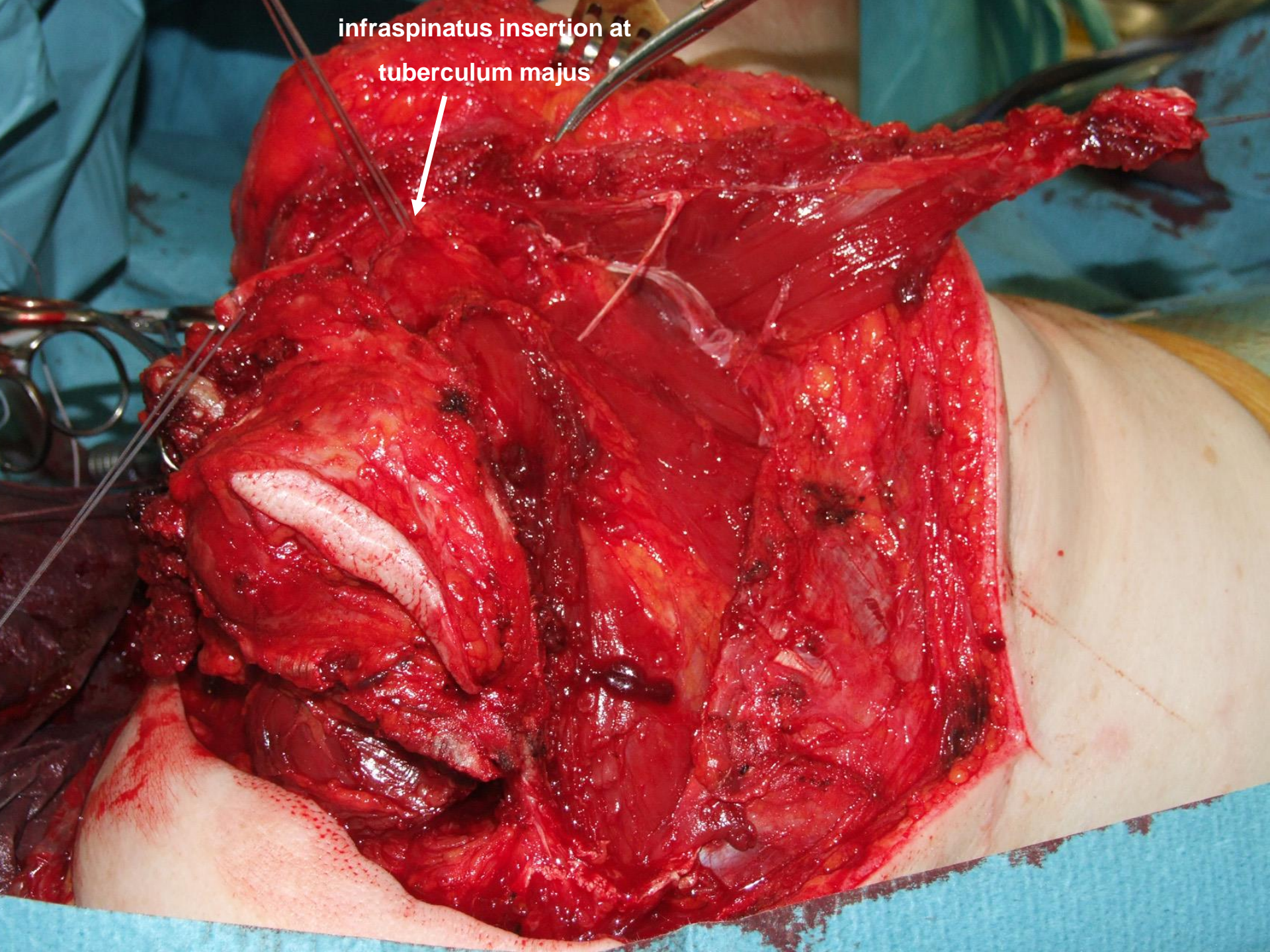tumor

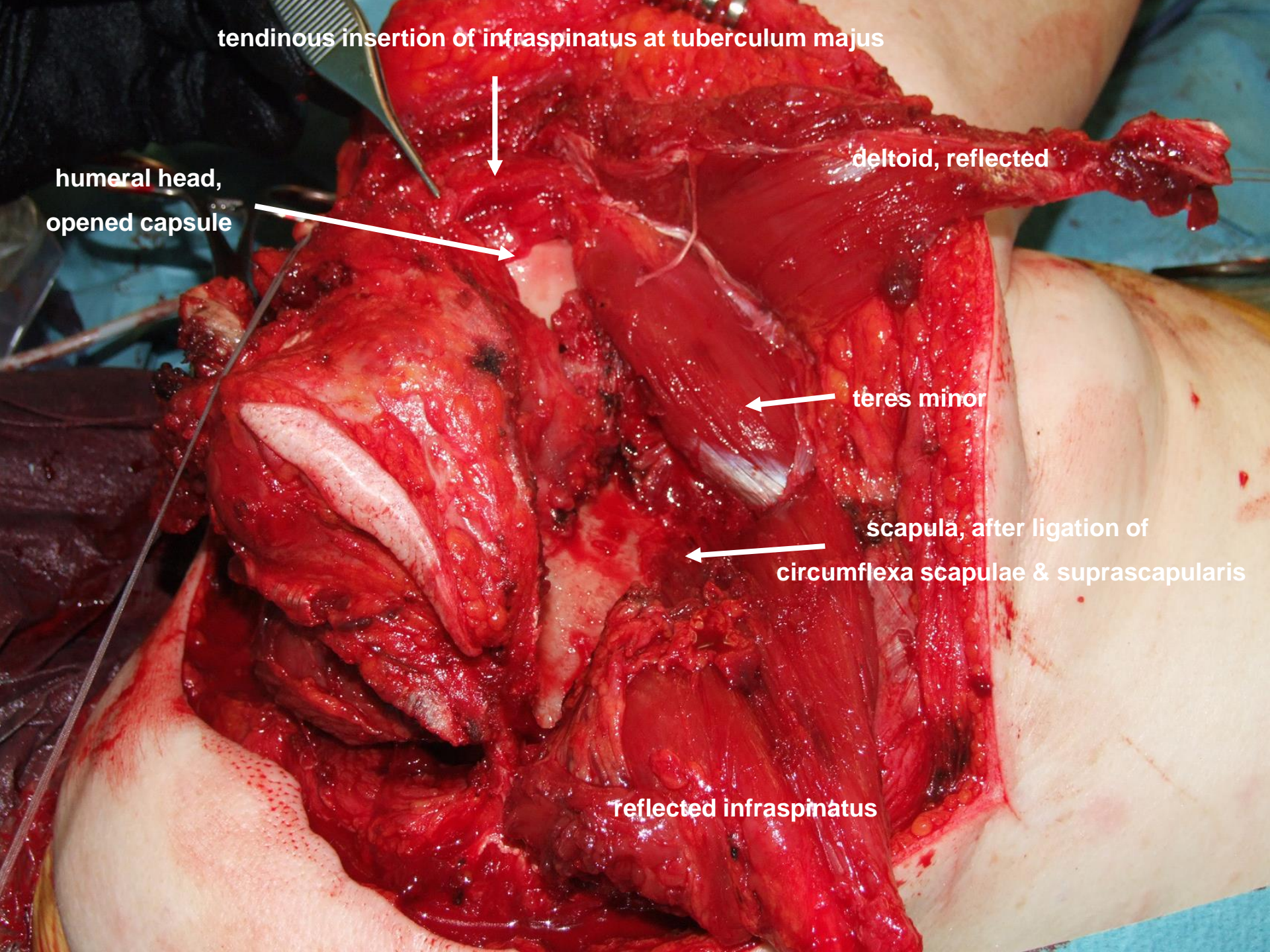
infraspinatus

scapular spine

margo medialis scapulae

infraspinatus insertion at
tuberculum majus





tendinous insertion of infraspinatus at tuberculum majus



deltoid, reflected

humeral head,
opened capsule



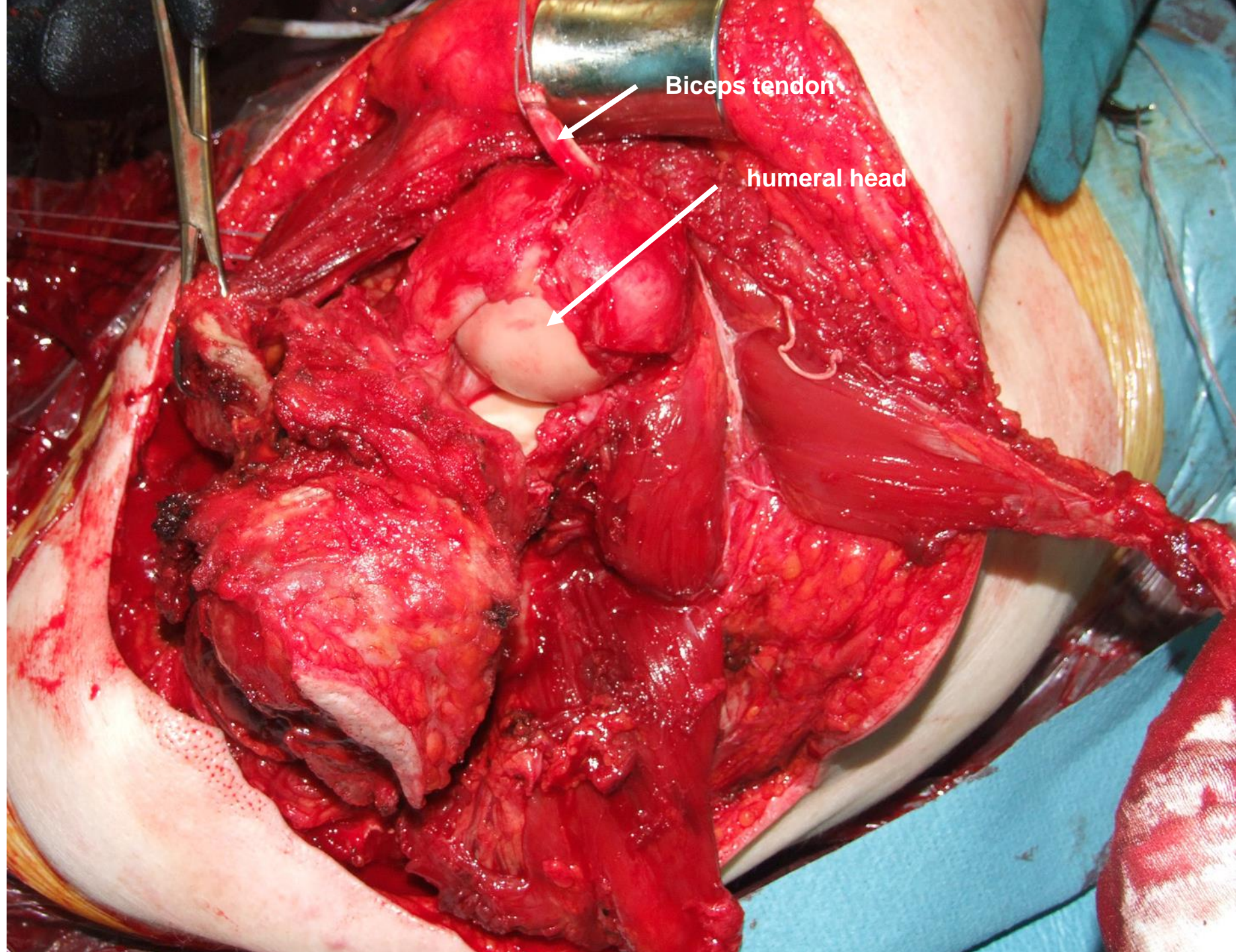
teres minor



scapula, after ligation of
circumflexa scapulae & suprascapularis

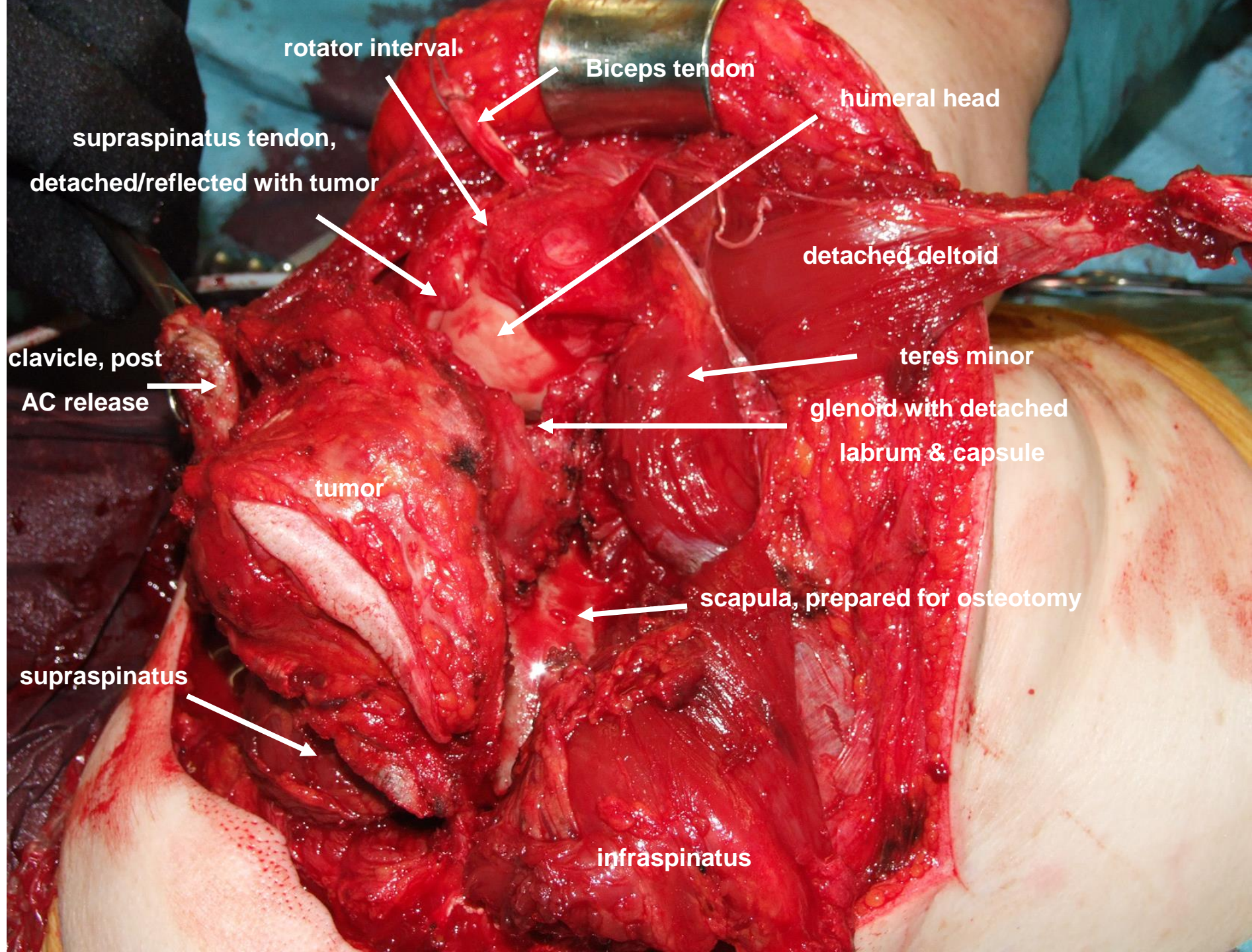


reflected infraspinatus



Biceps tendon

humeral head



rotator interval

Biceps tendon

humeral head

supraspinatus tendon,
detached/reflected with tumor

detached deltoid

clavicle, post
AC release

teres minor

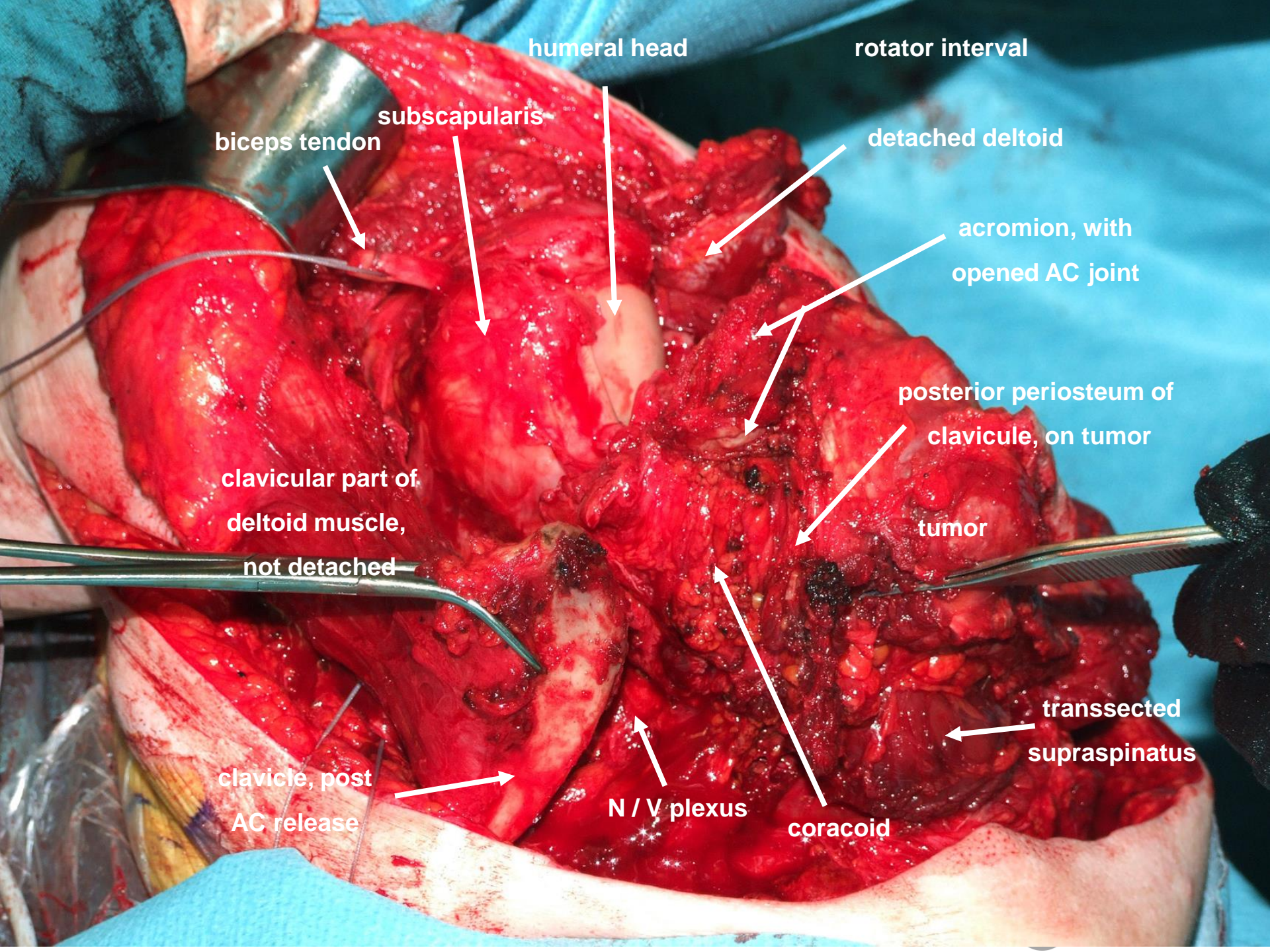
glenoid with detached
labrum & capsule

tumor

scapula, prepared for osteotomy

supraspinatus

infraspinatus



humeral head

rotator interval

biceps tendon

subscapularis

detached deltoid

acromion, with
opened AC joint

clavicular part of
deltoid muscle,
not detached

posterior periosteum of
clavicle, on tumor

tumor

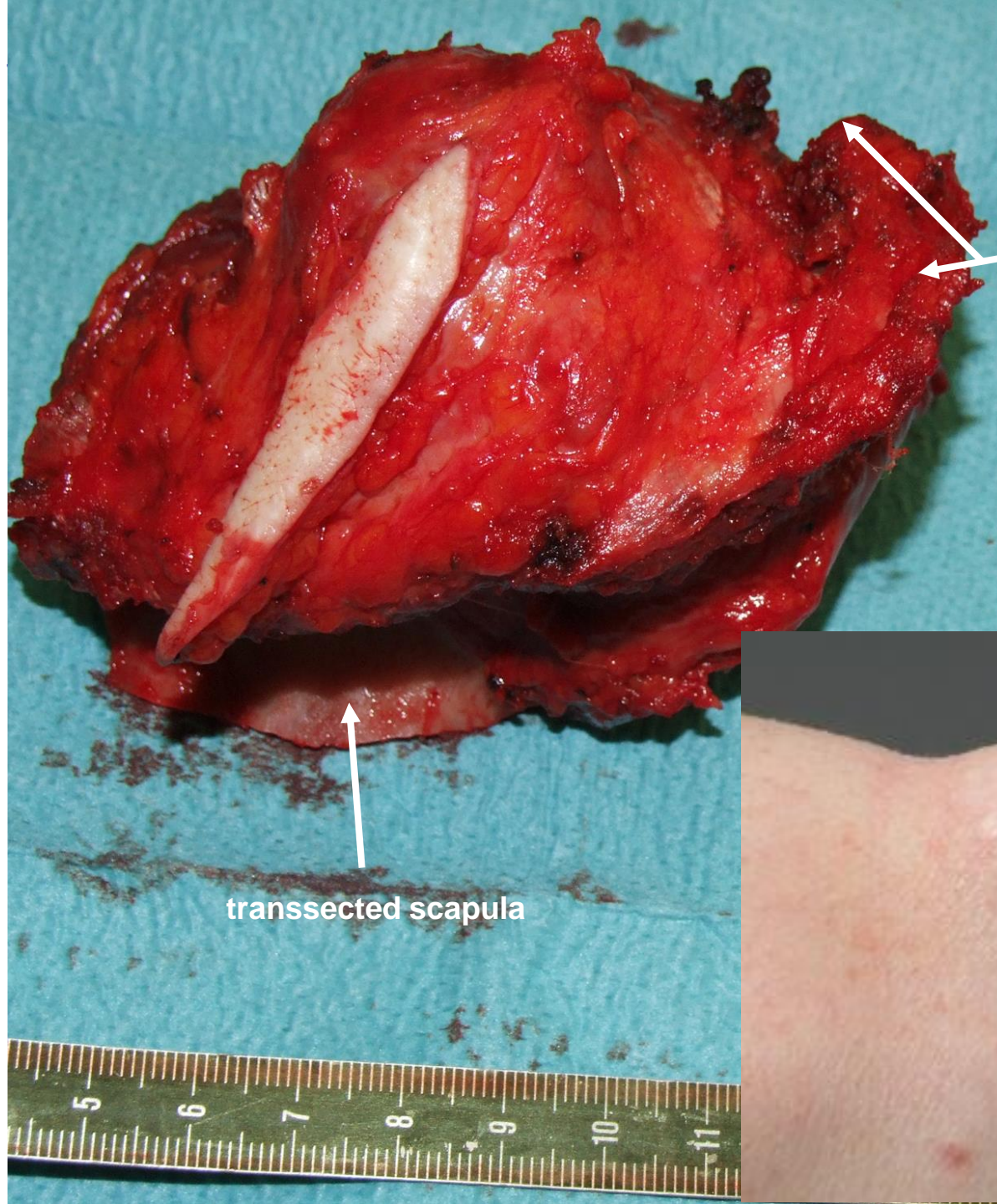
transsected
supraspinatus

clavicle, post
AC release

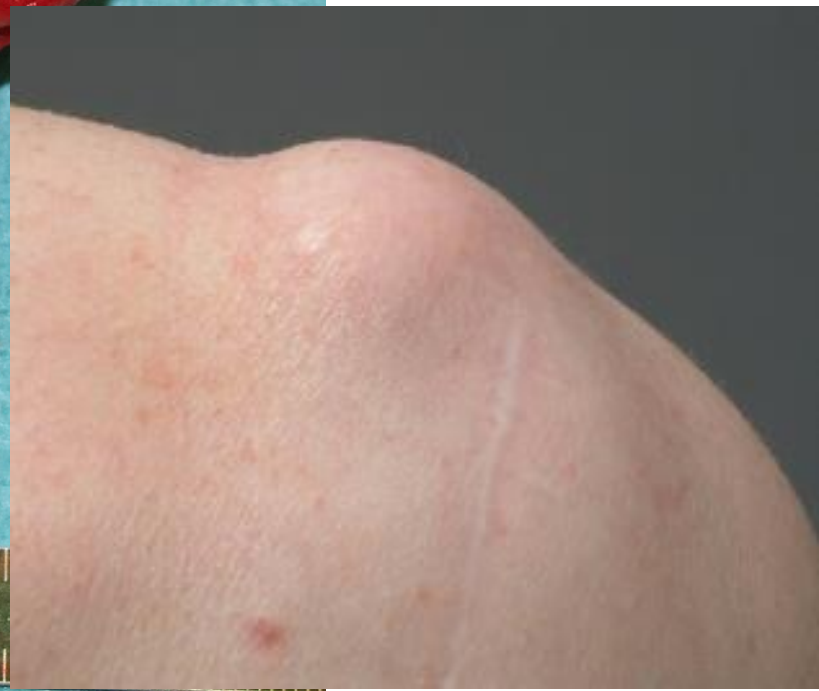N / V plexus

coracoid

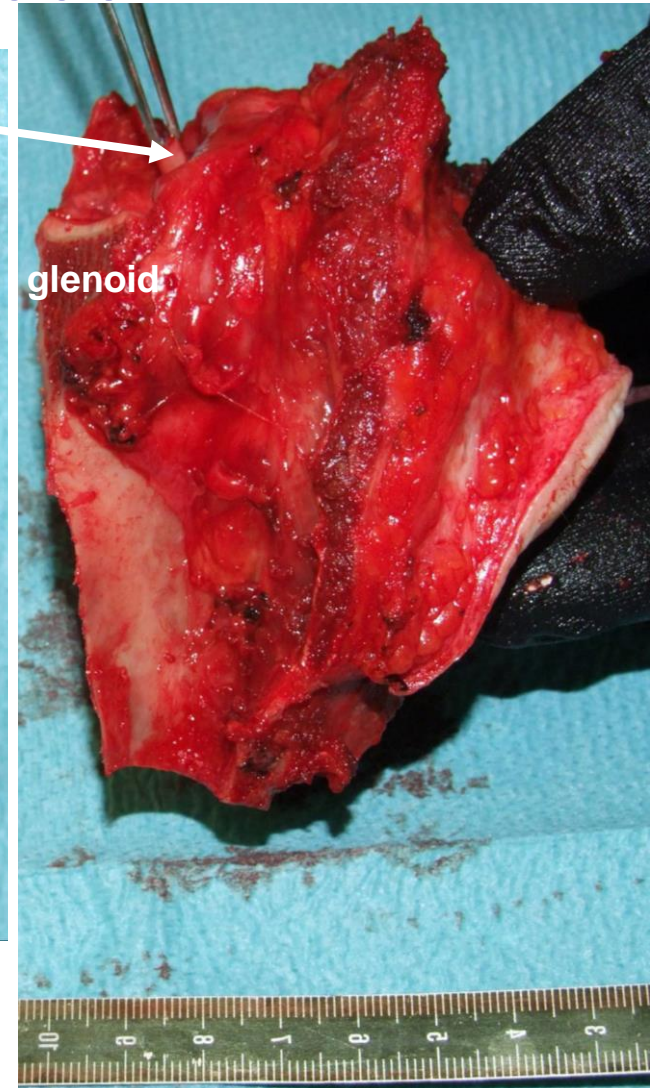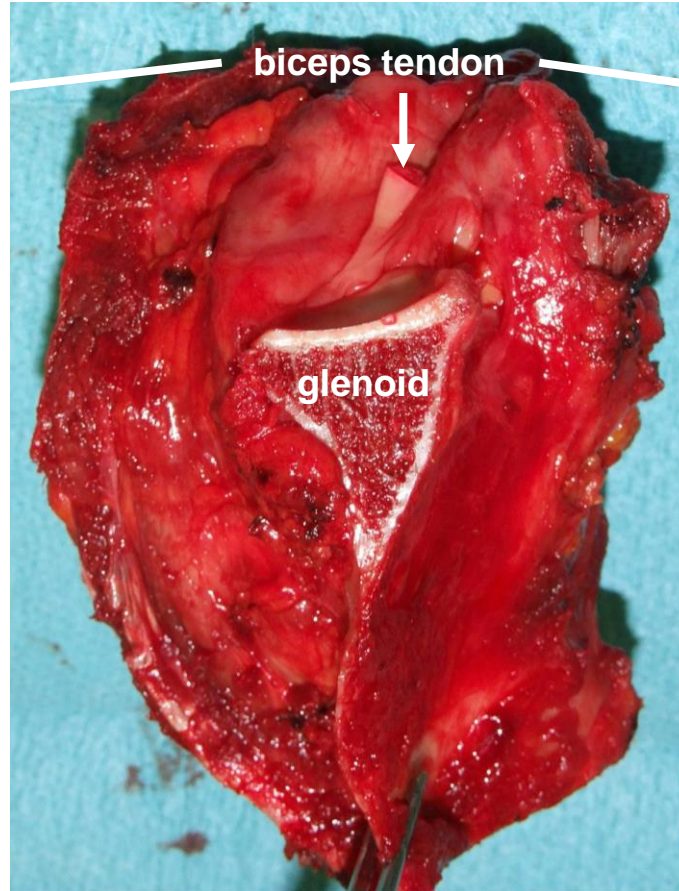
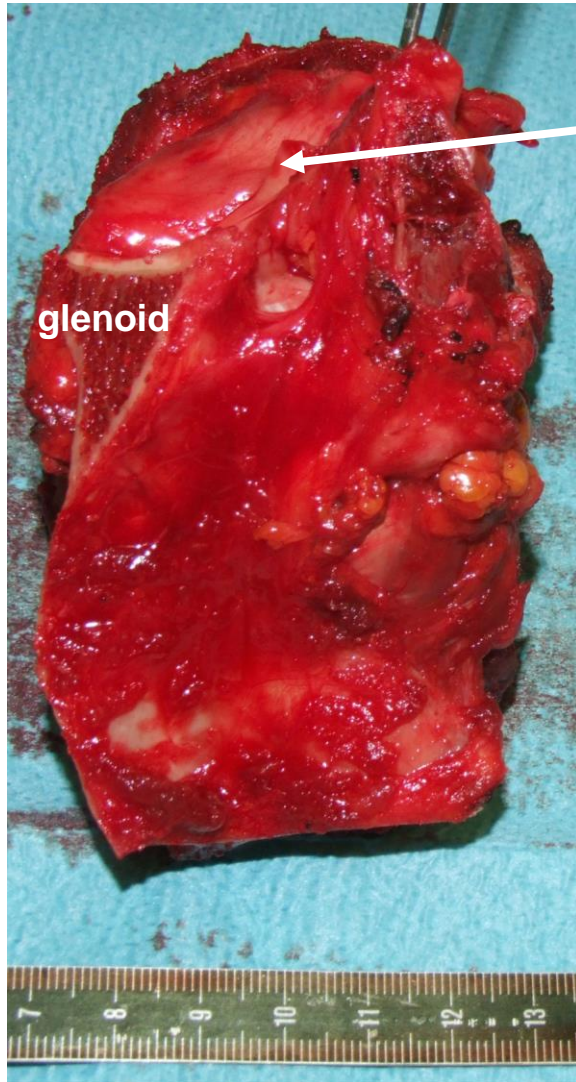
ection



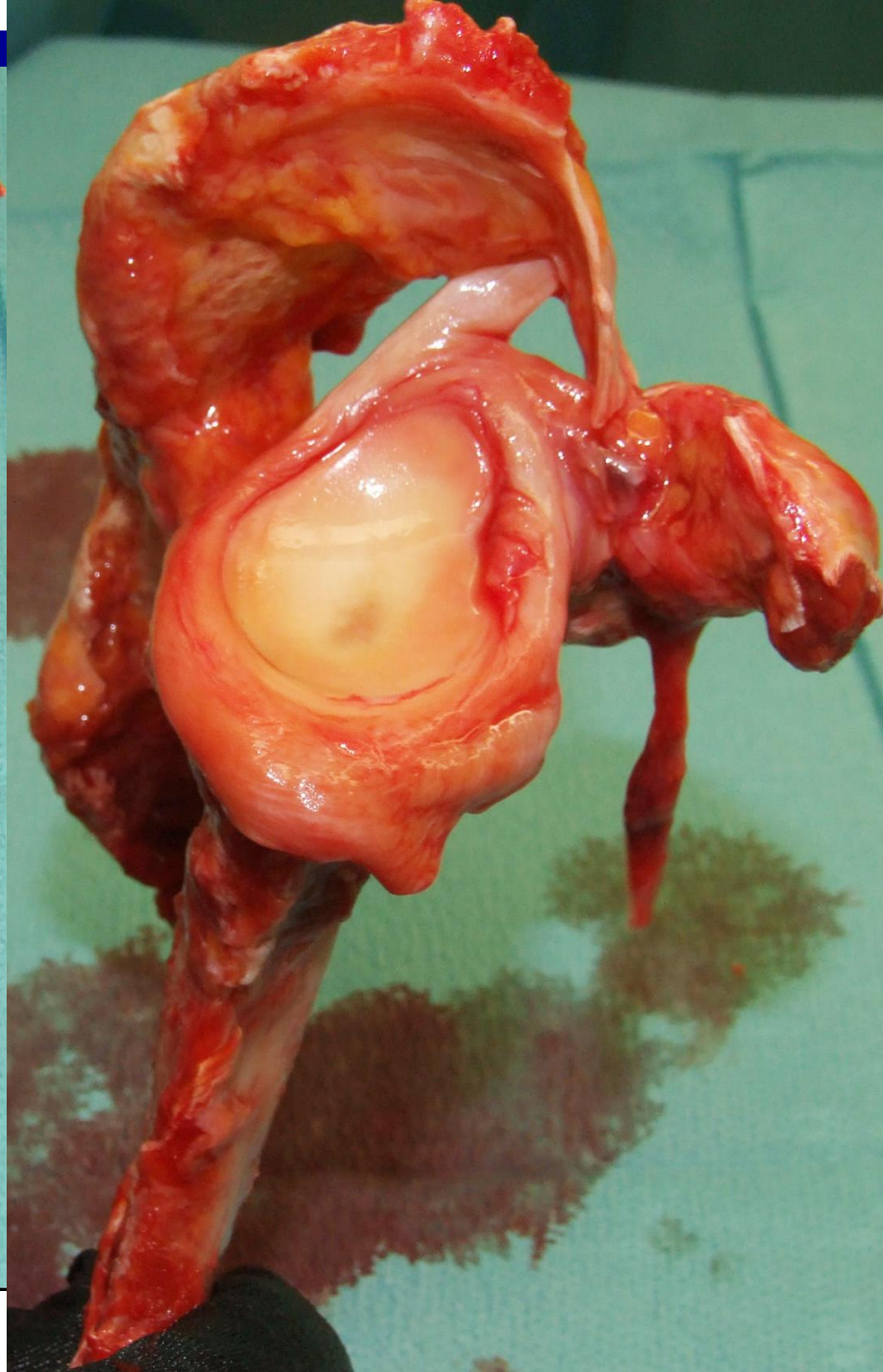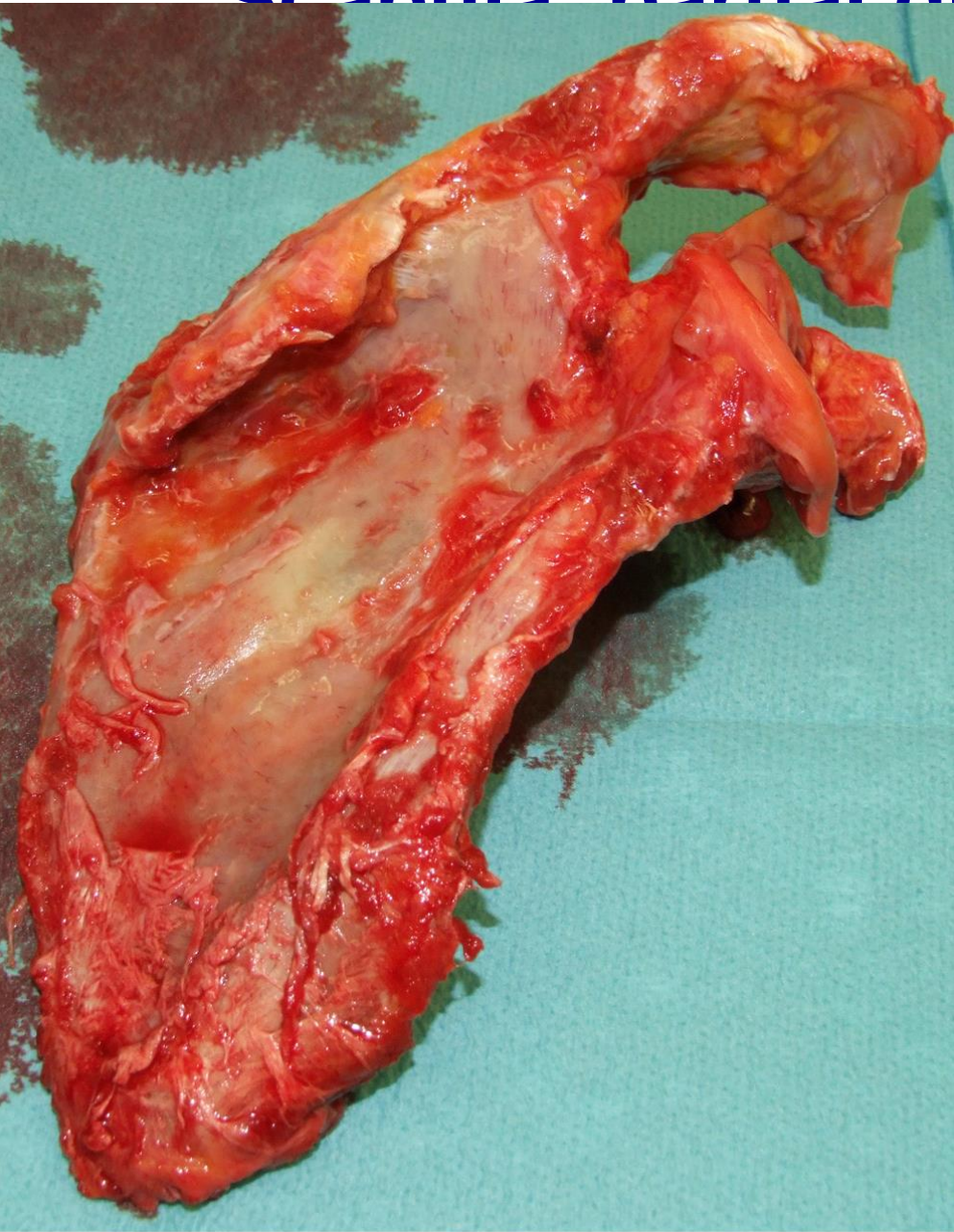
transsected scapula



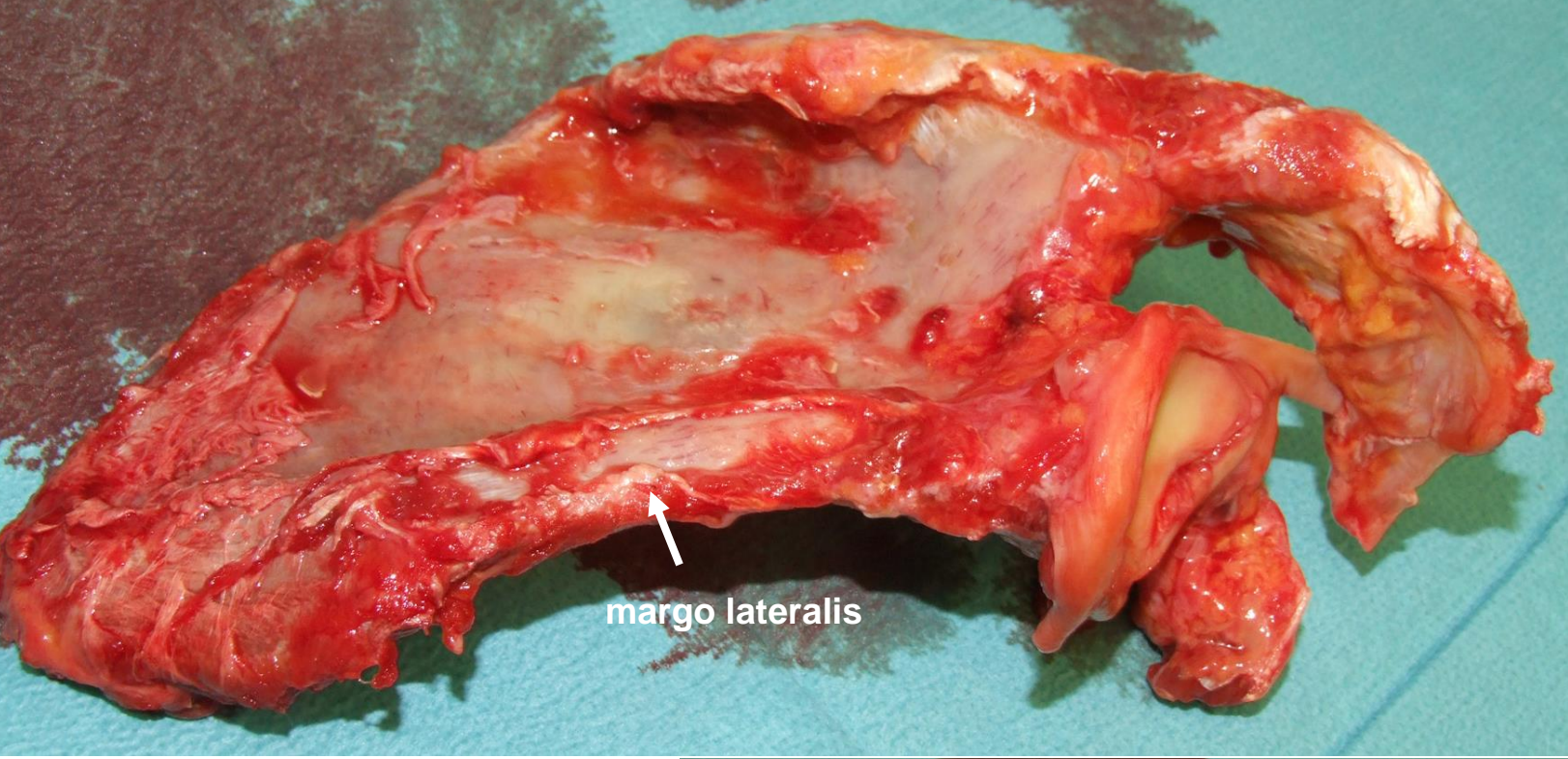
Scapula; partial glenoid resection surgery, July 24, 2008



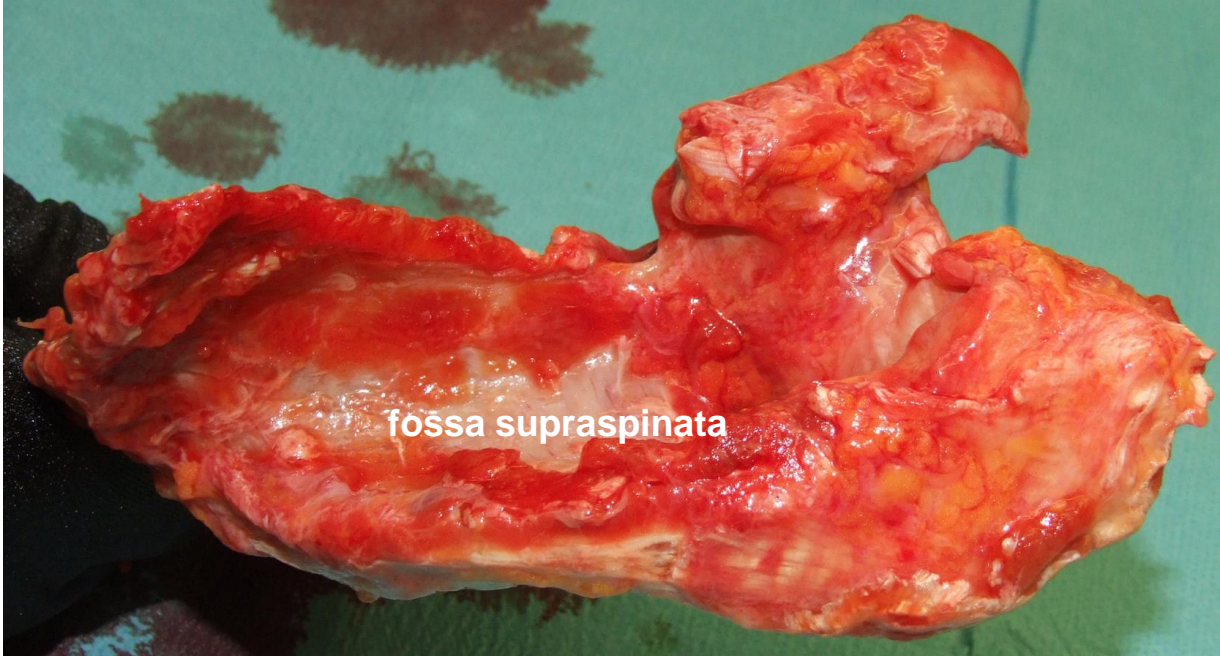Scapula: partial of



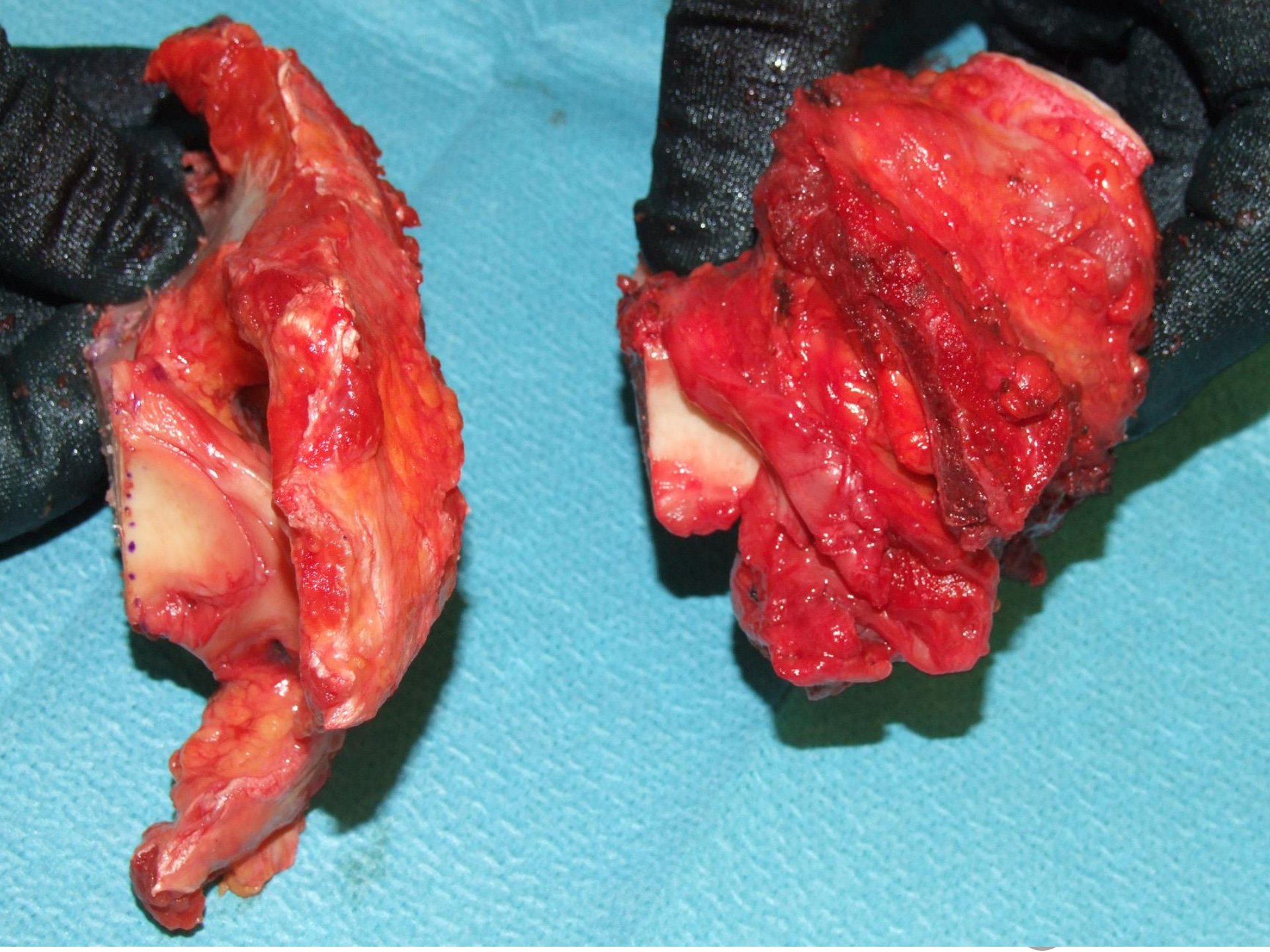
n



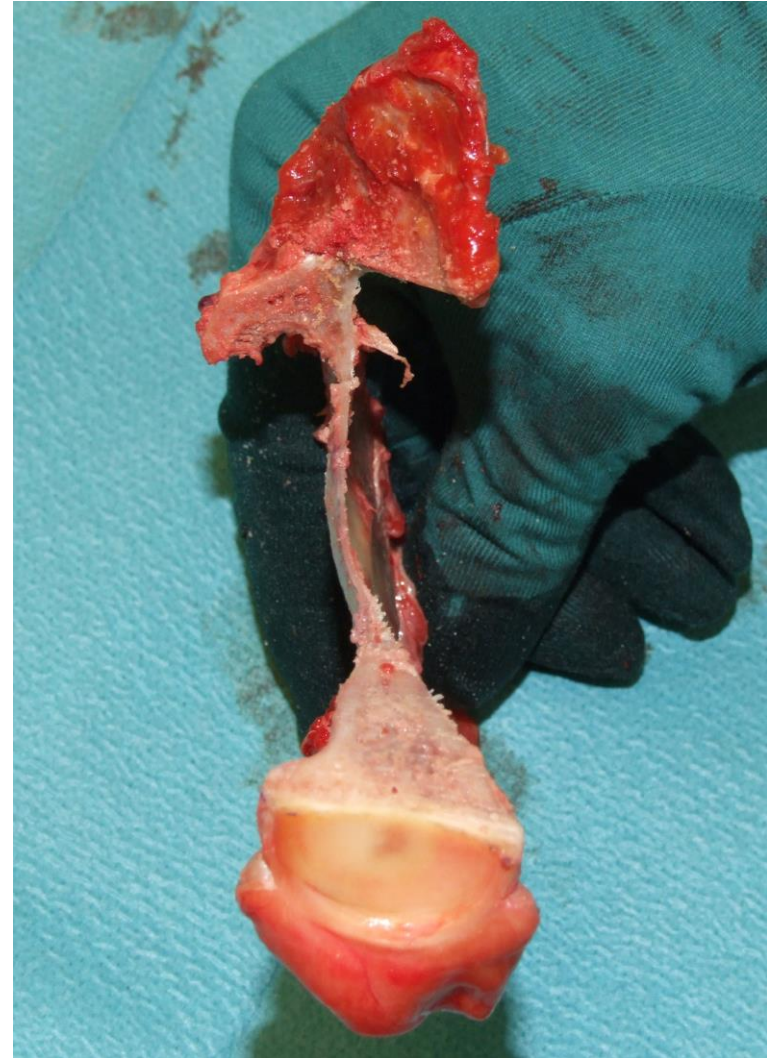
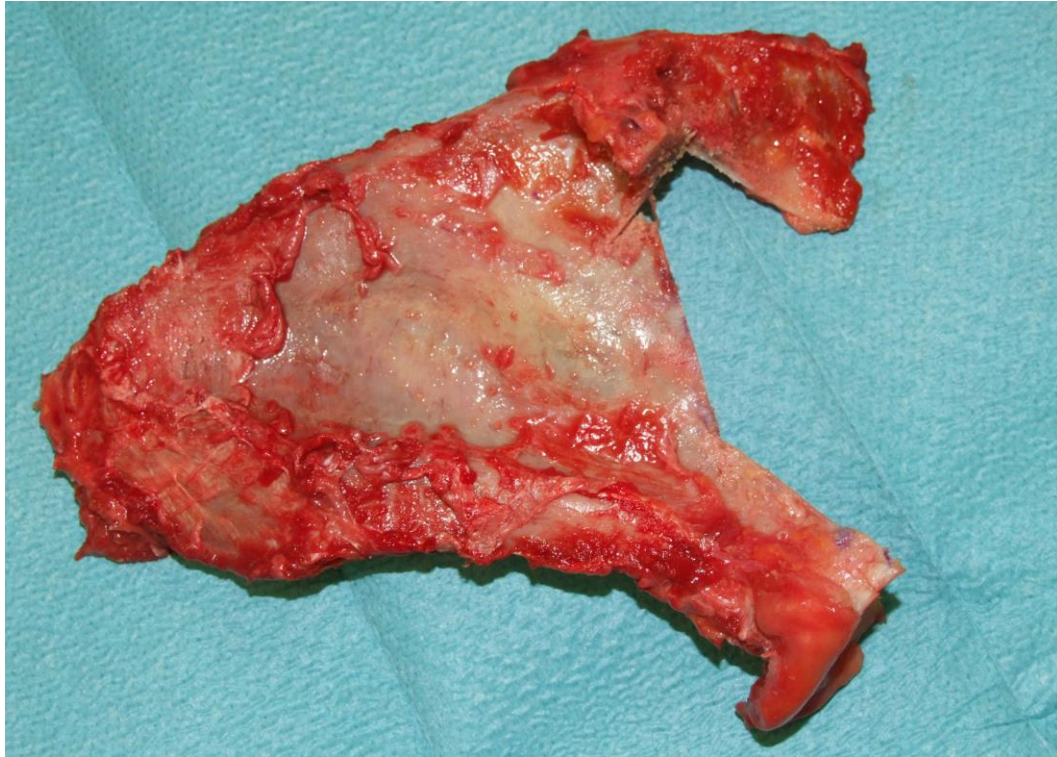
margo lateralis

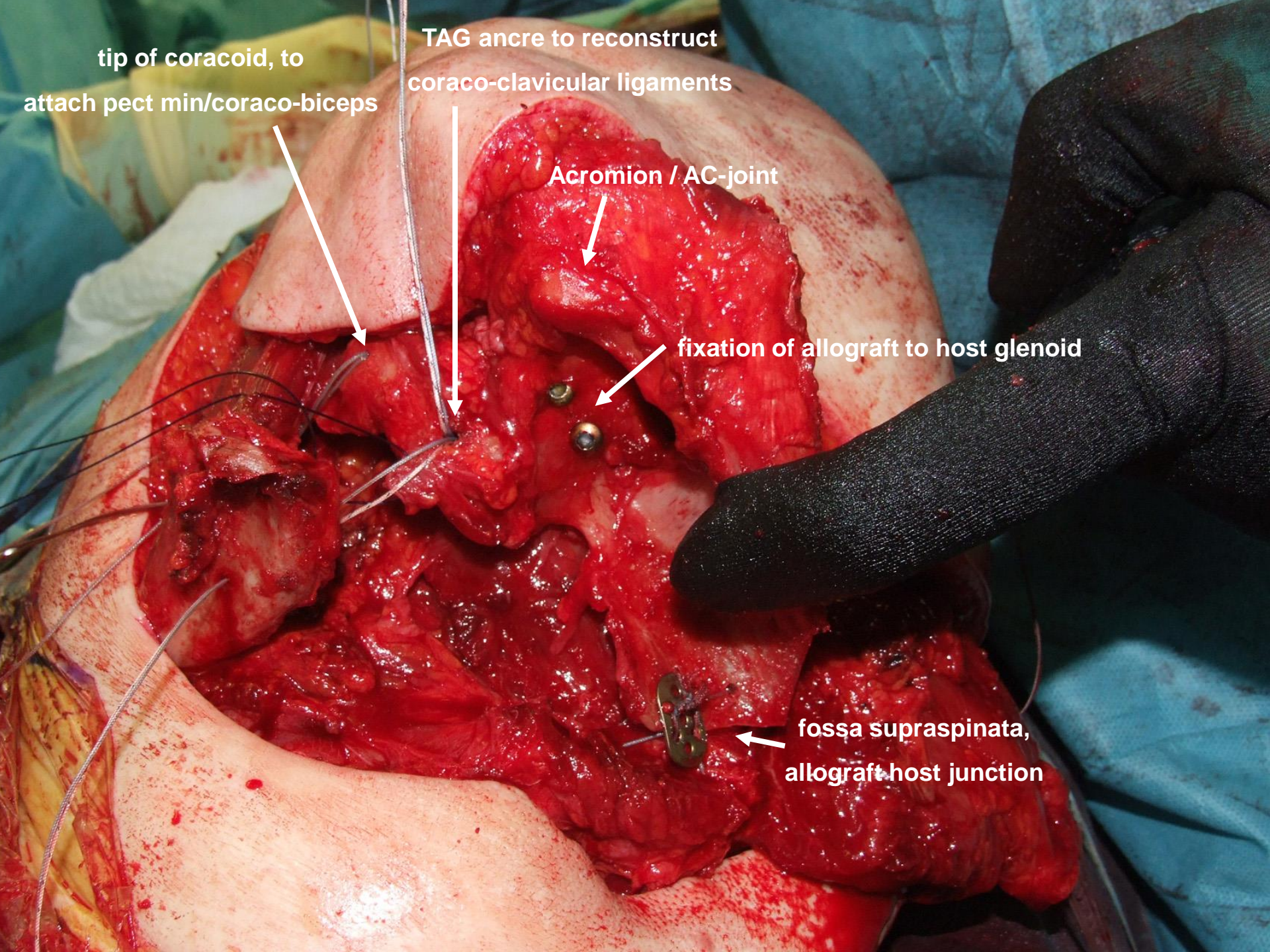


fossa suprascapularis



Scapula; partial glenoid resection surgery, July 24, 2008





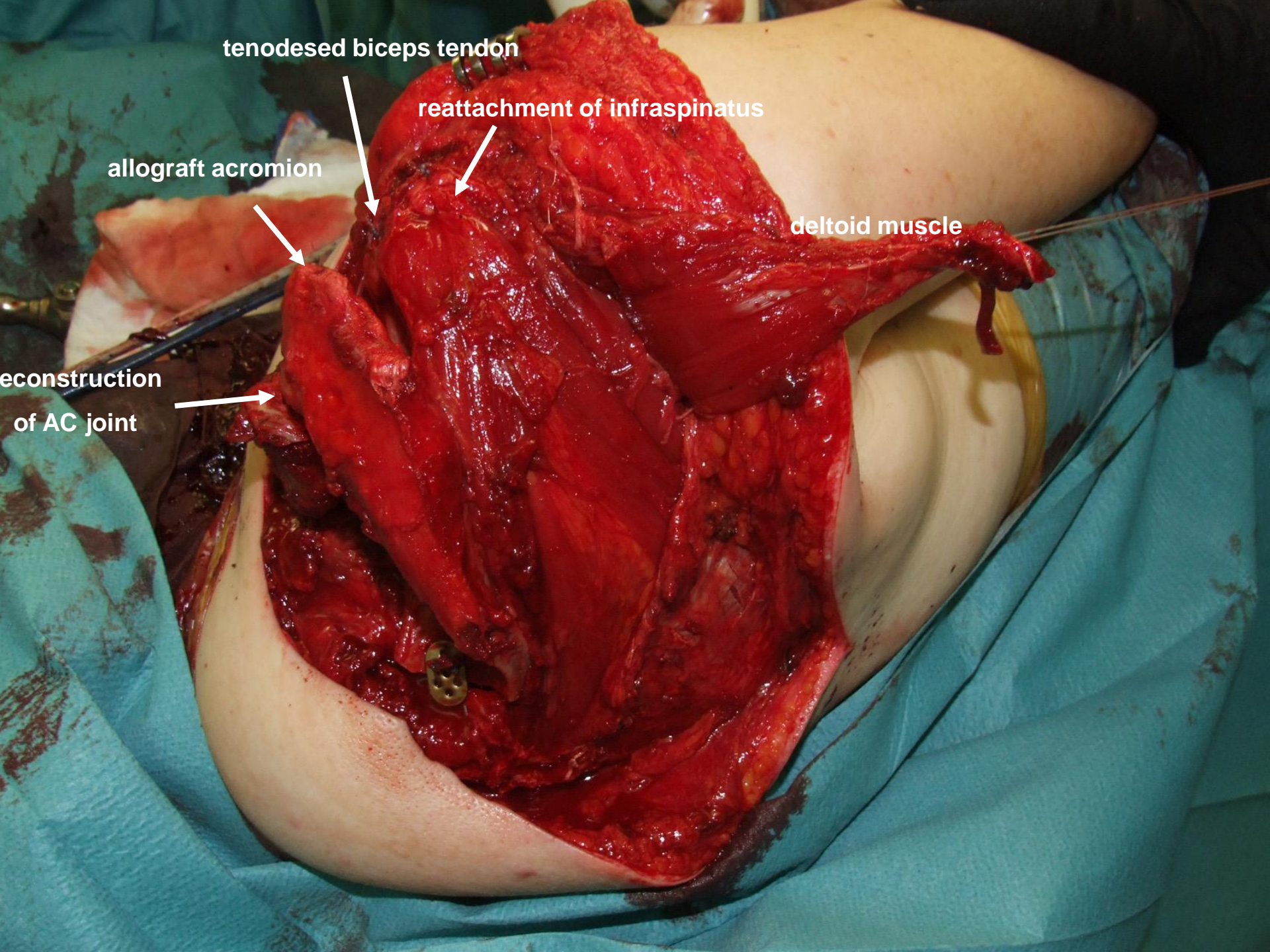
tip of coracoid, to
attach pect min/coraco-biceps

TAG ancre to reconstruct
coraco-clavicular ligaments

Acromion / AC-joint

fixation of allograft to host glenoid

fossa supraspinata,
allograft host junction



tenodesed biceps tendon

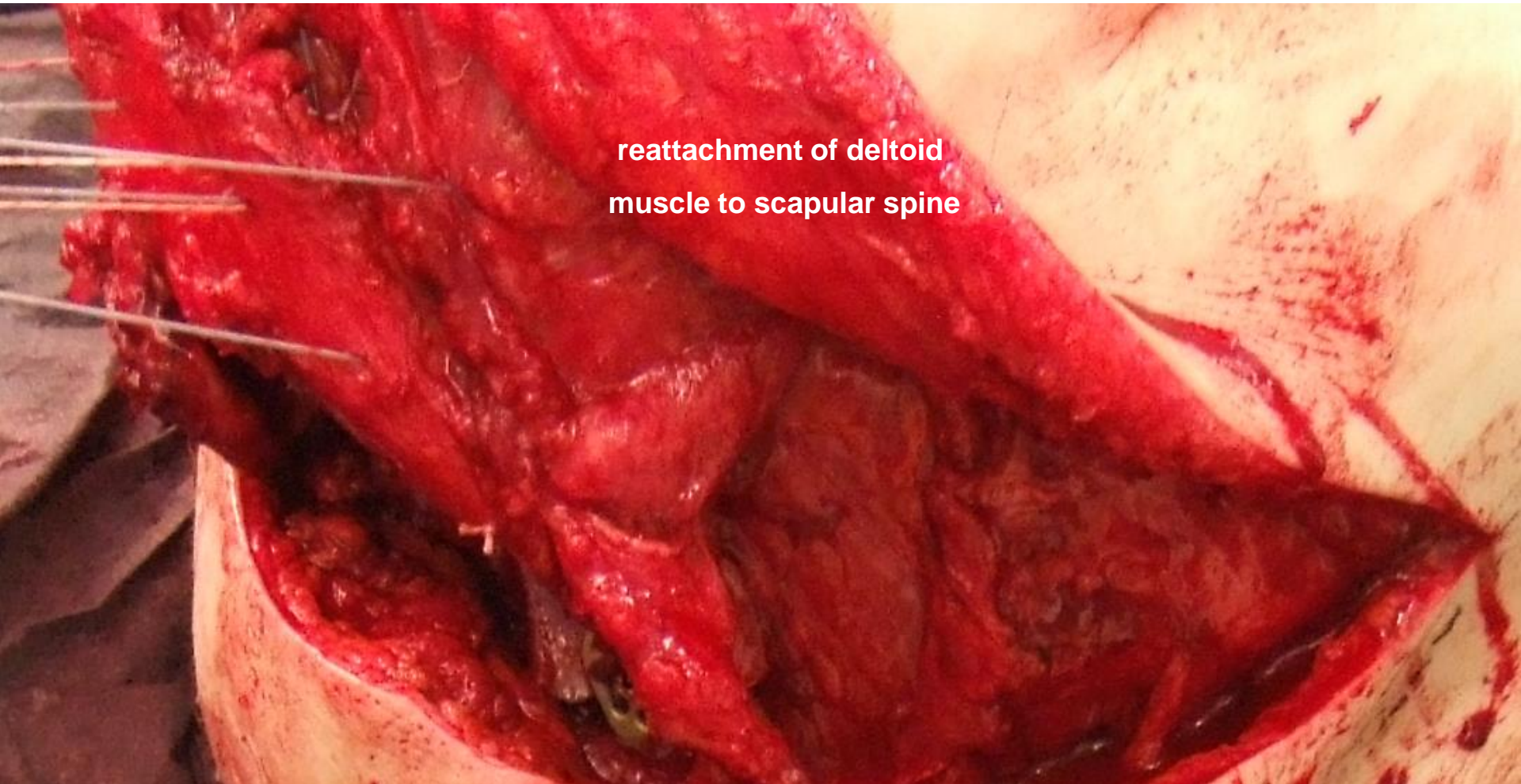
reattachment of infraspinatus

allograft acromion

deltoid muscle

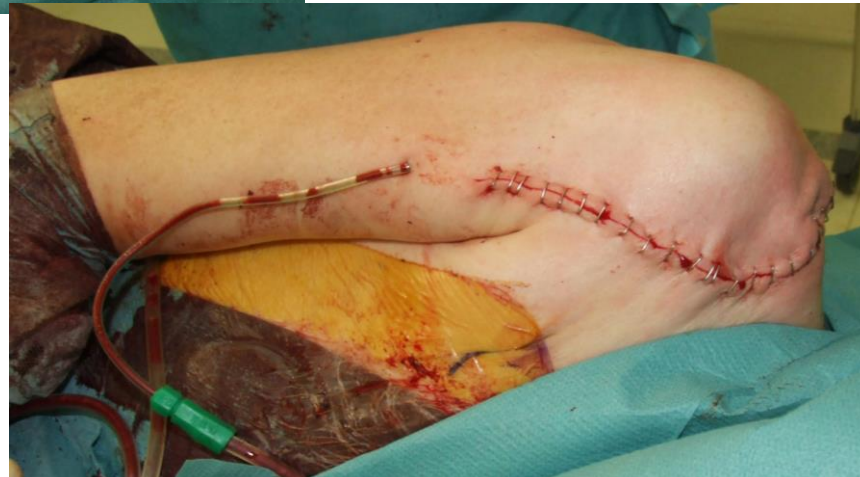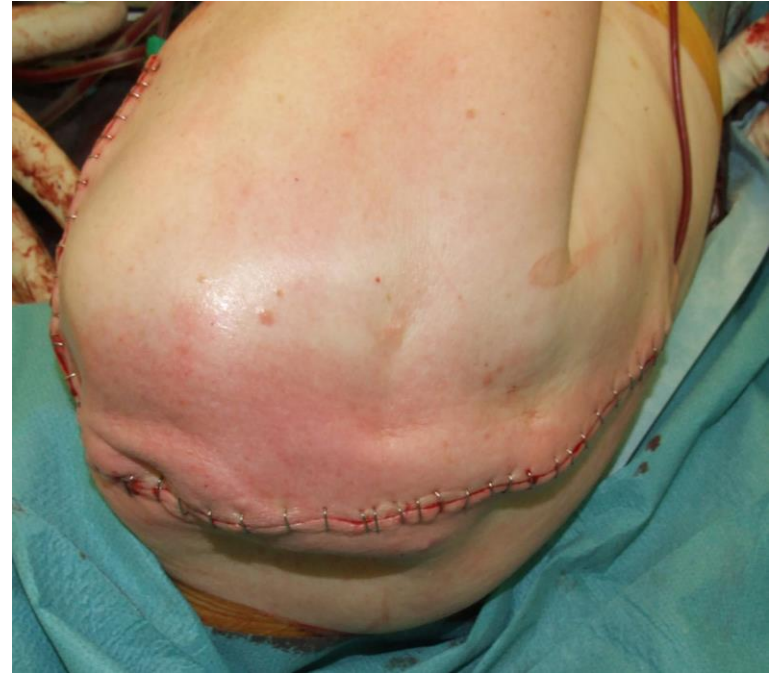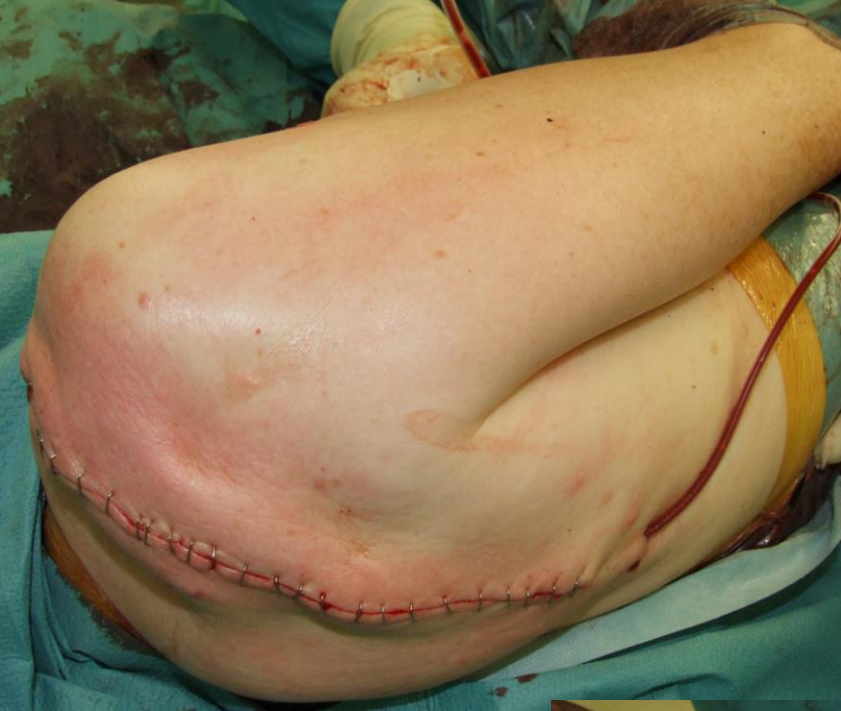reconstruction
of AC joint

Scapula; partial glenoid resection surgery, July 24, 2008

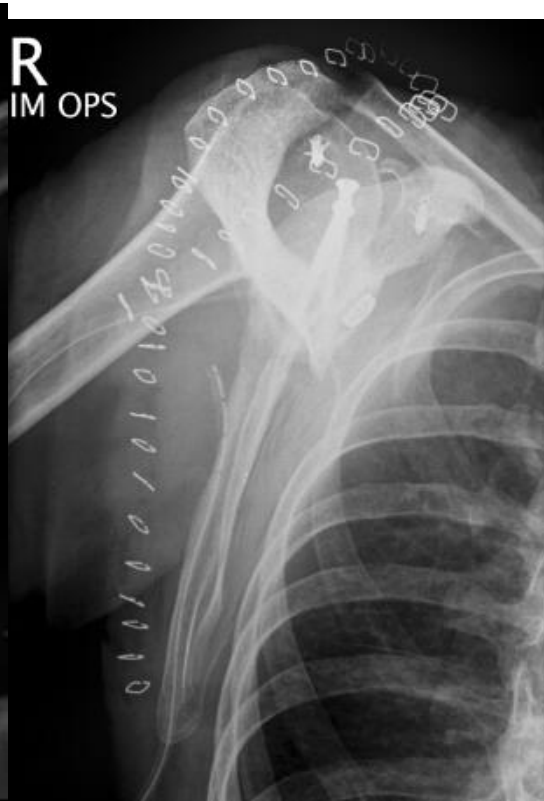
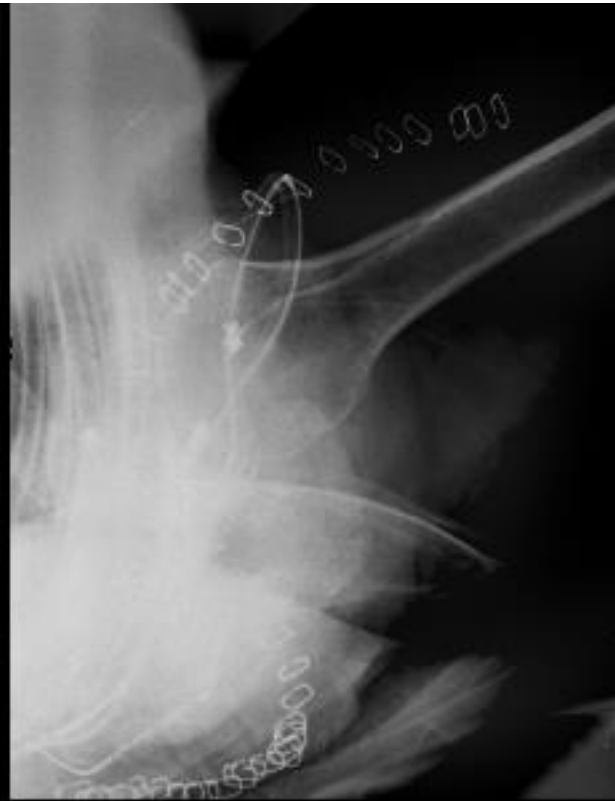
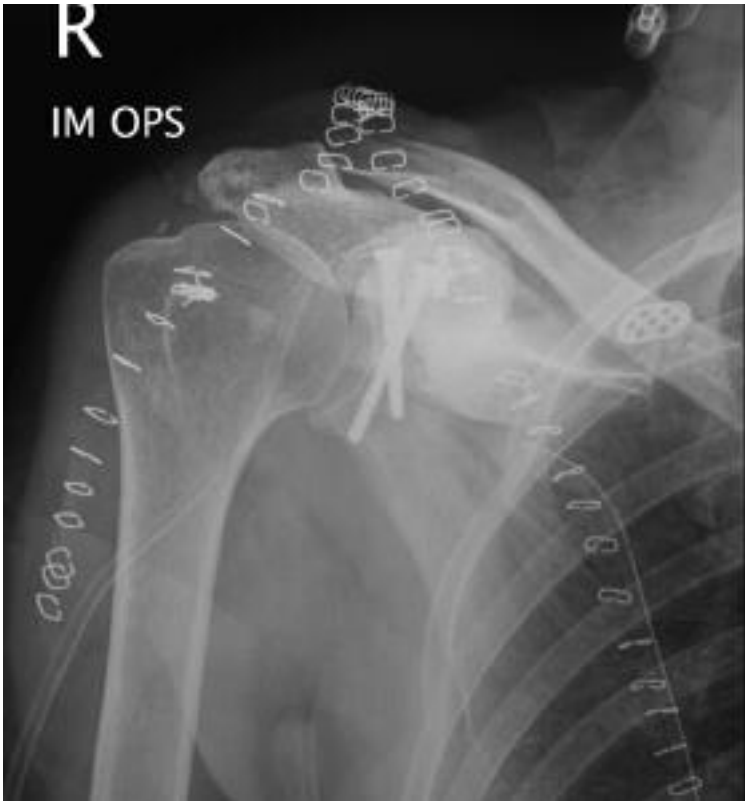

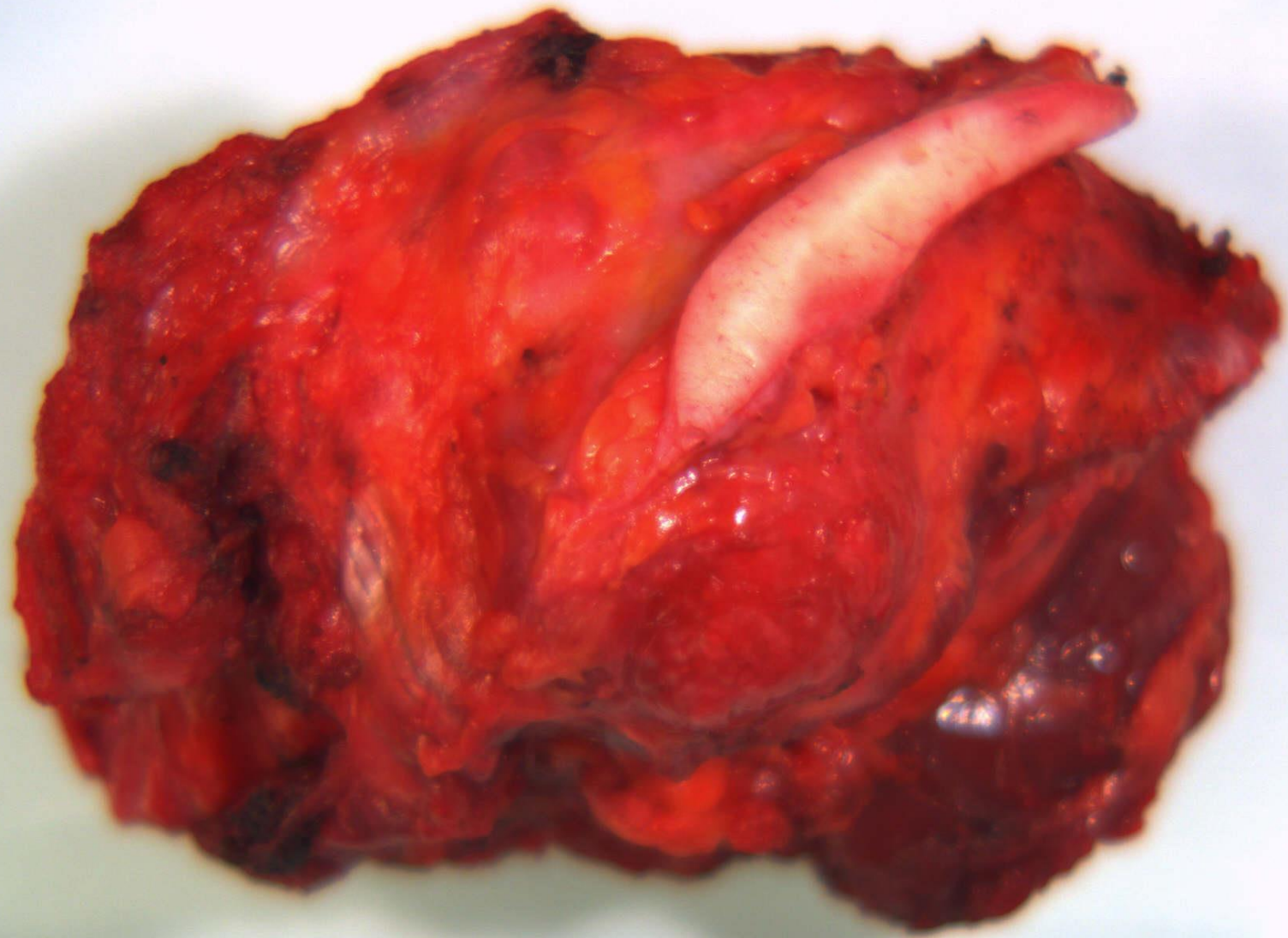
reattachment of deltoid
muscle to scapular spine

Scapula; partial glenoid resection surgery, July 24, 2008

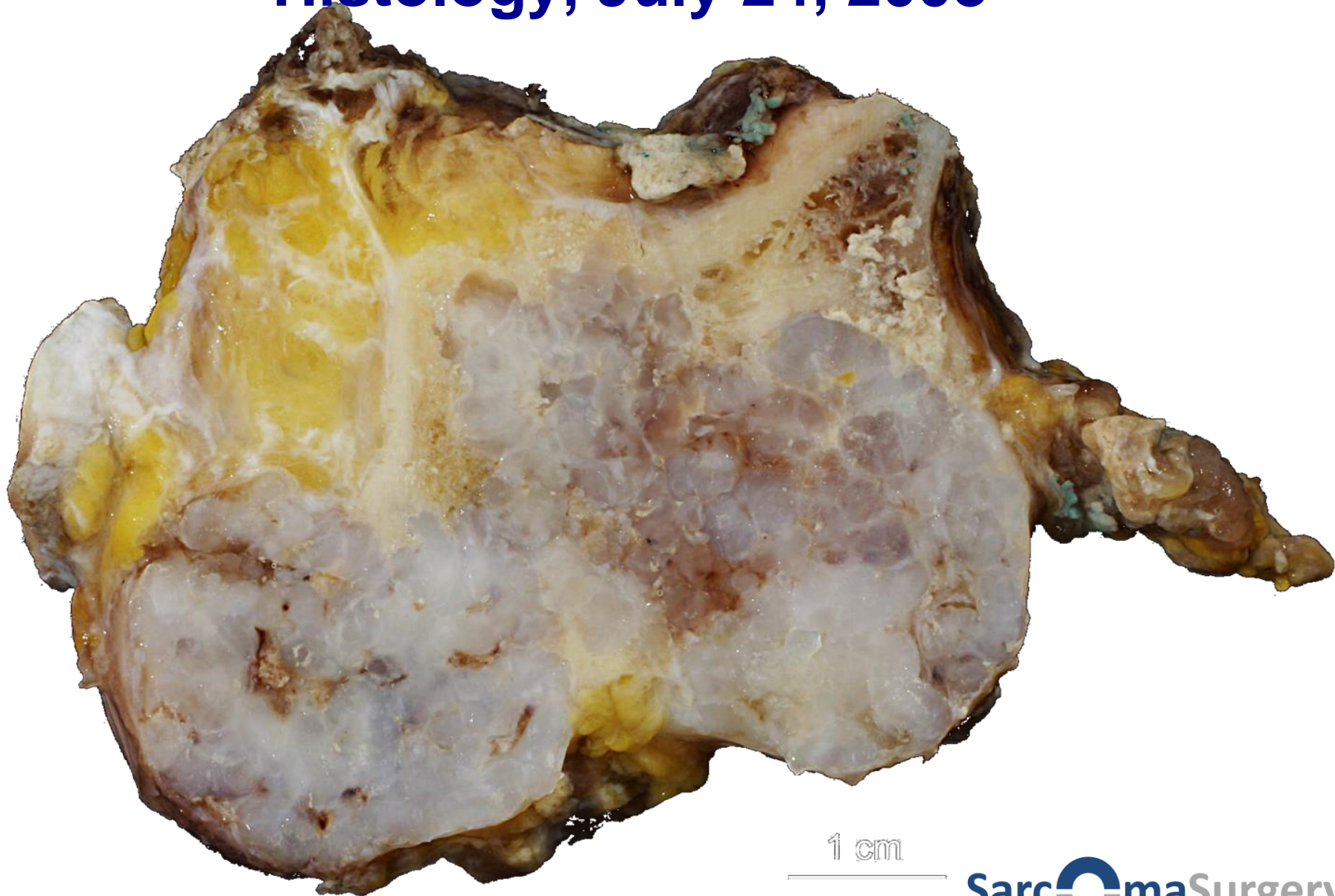


Scapula; partial glenoid resection post surgery, July 24, 2008

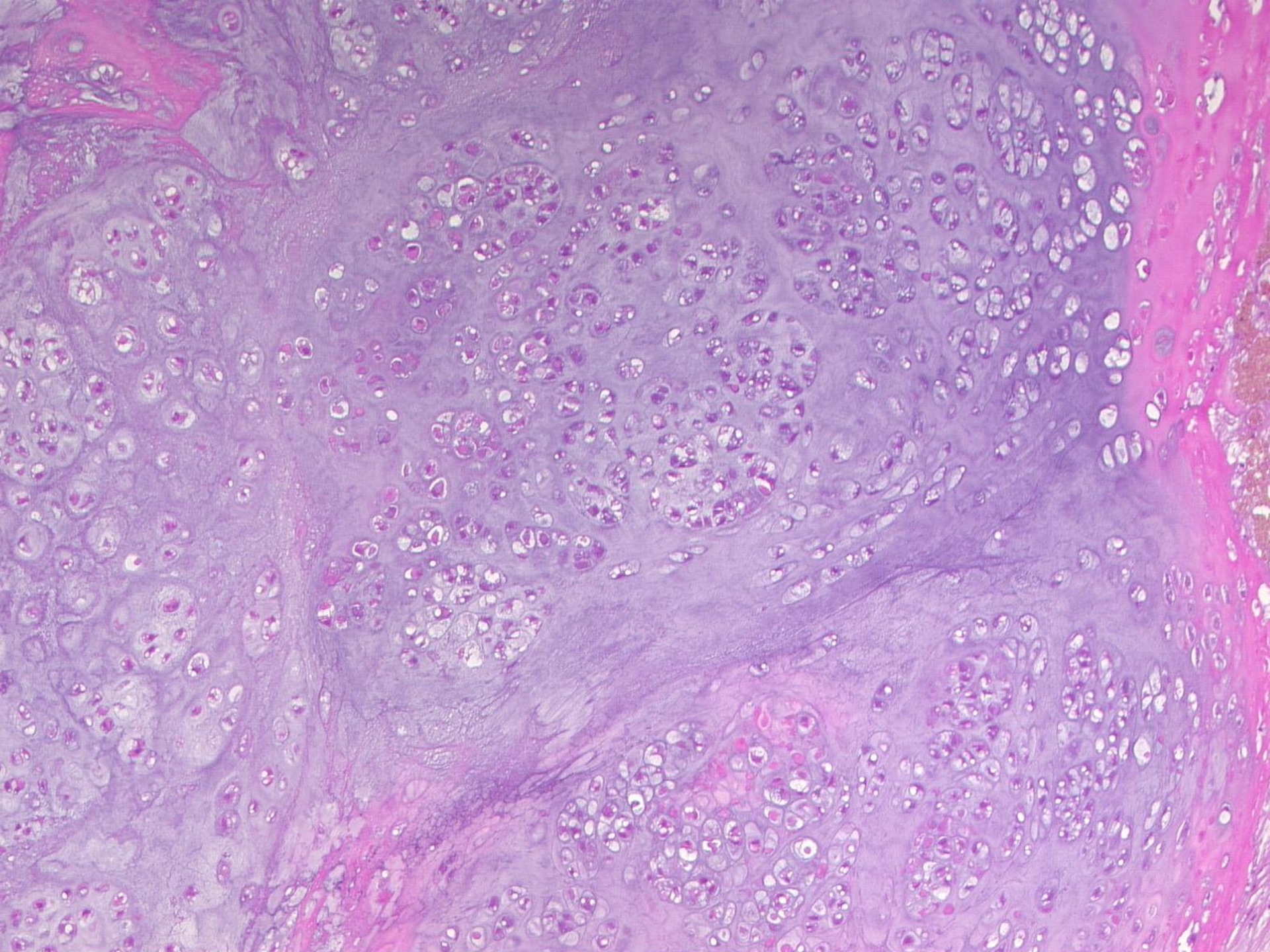


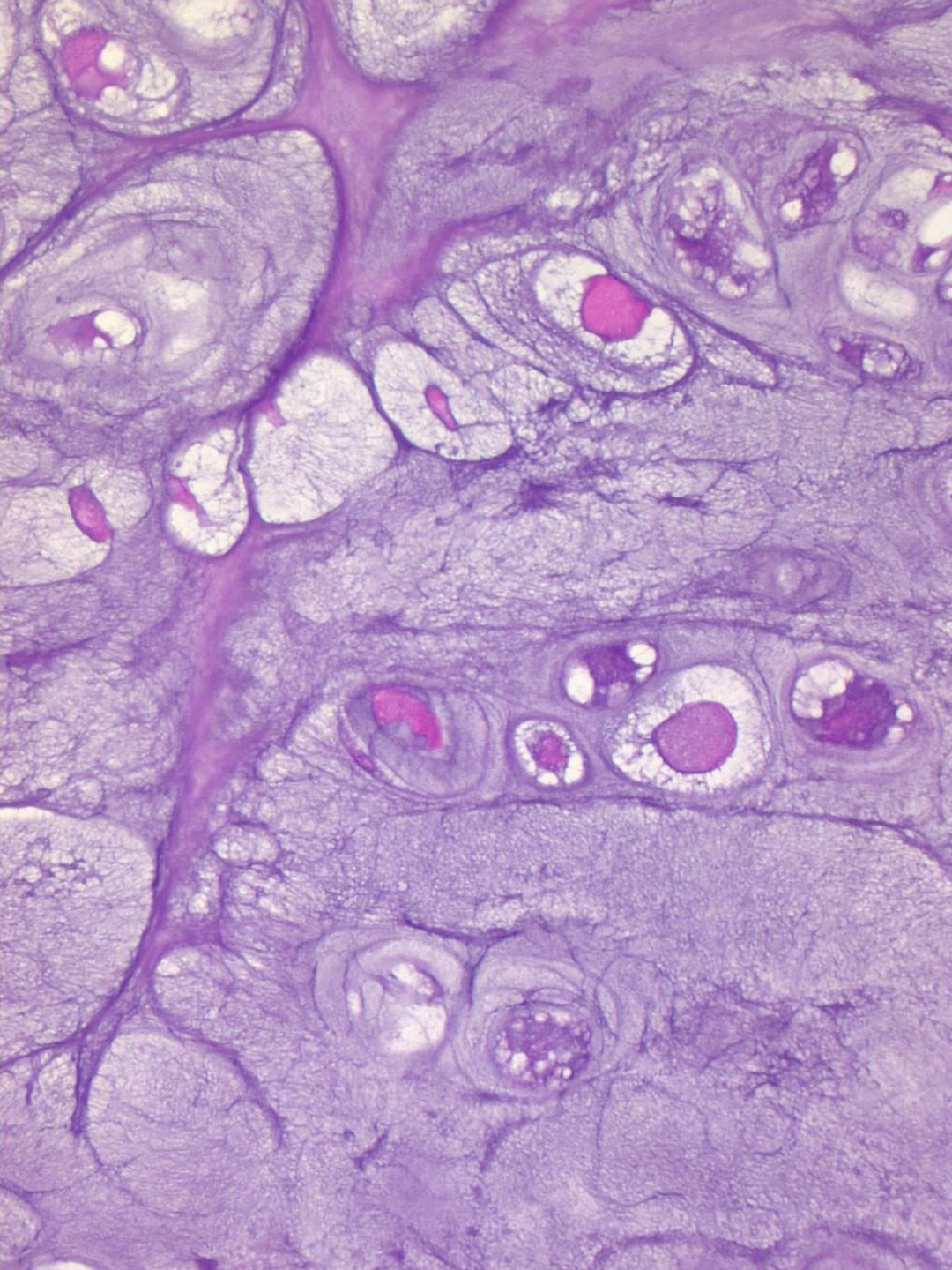
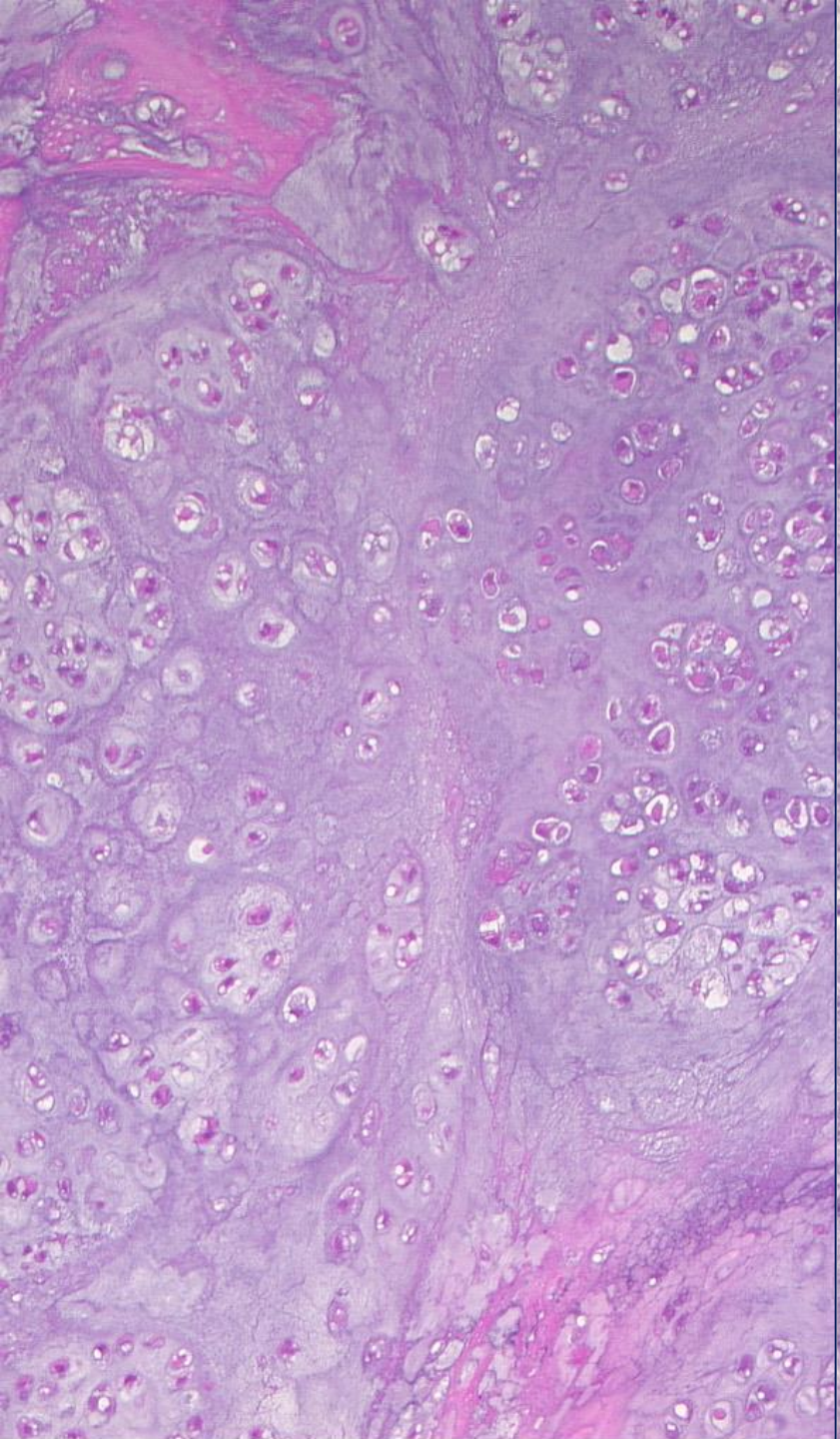


Scapula; partial glenoid resection Histology, July 24, 2008

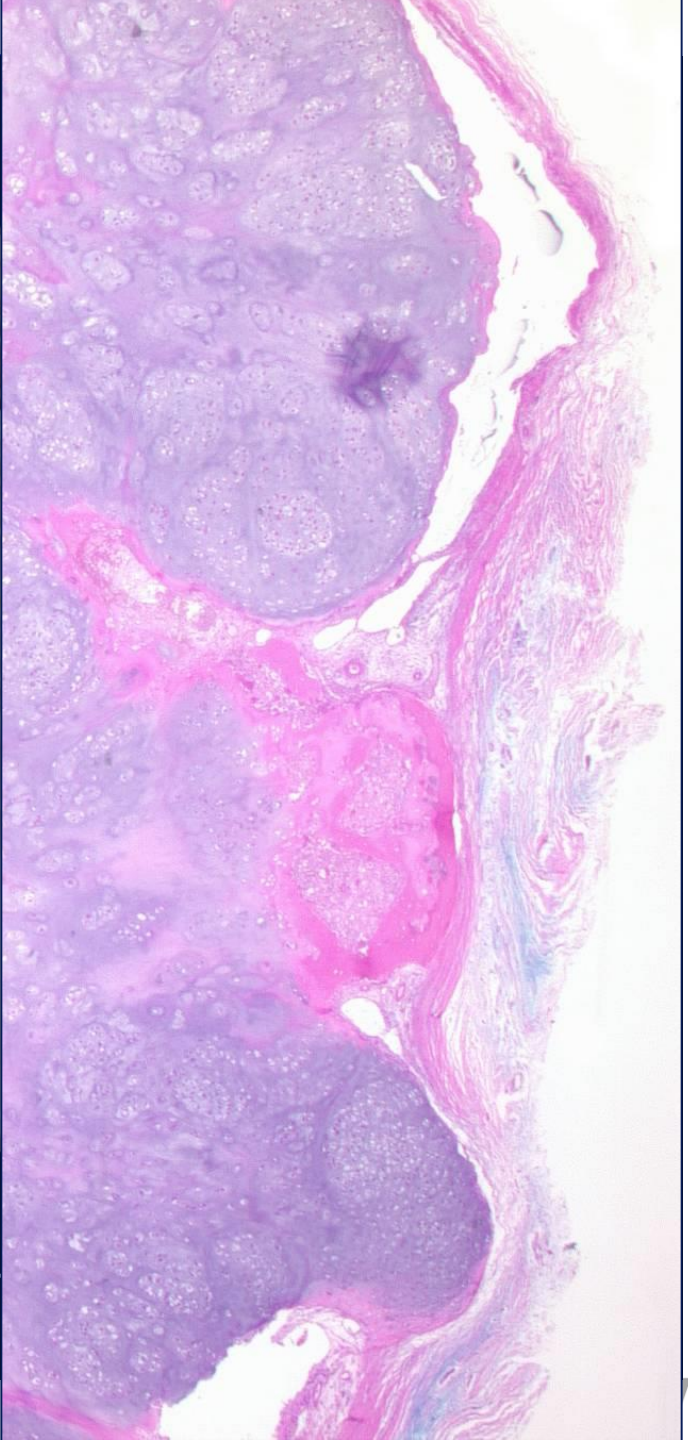
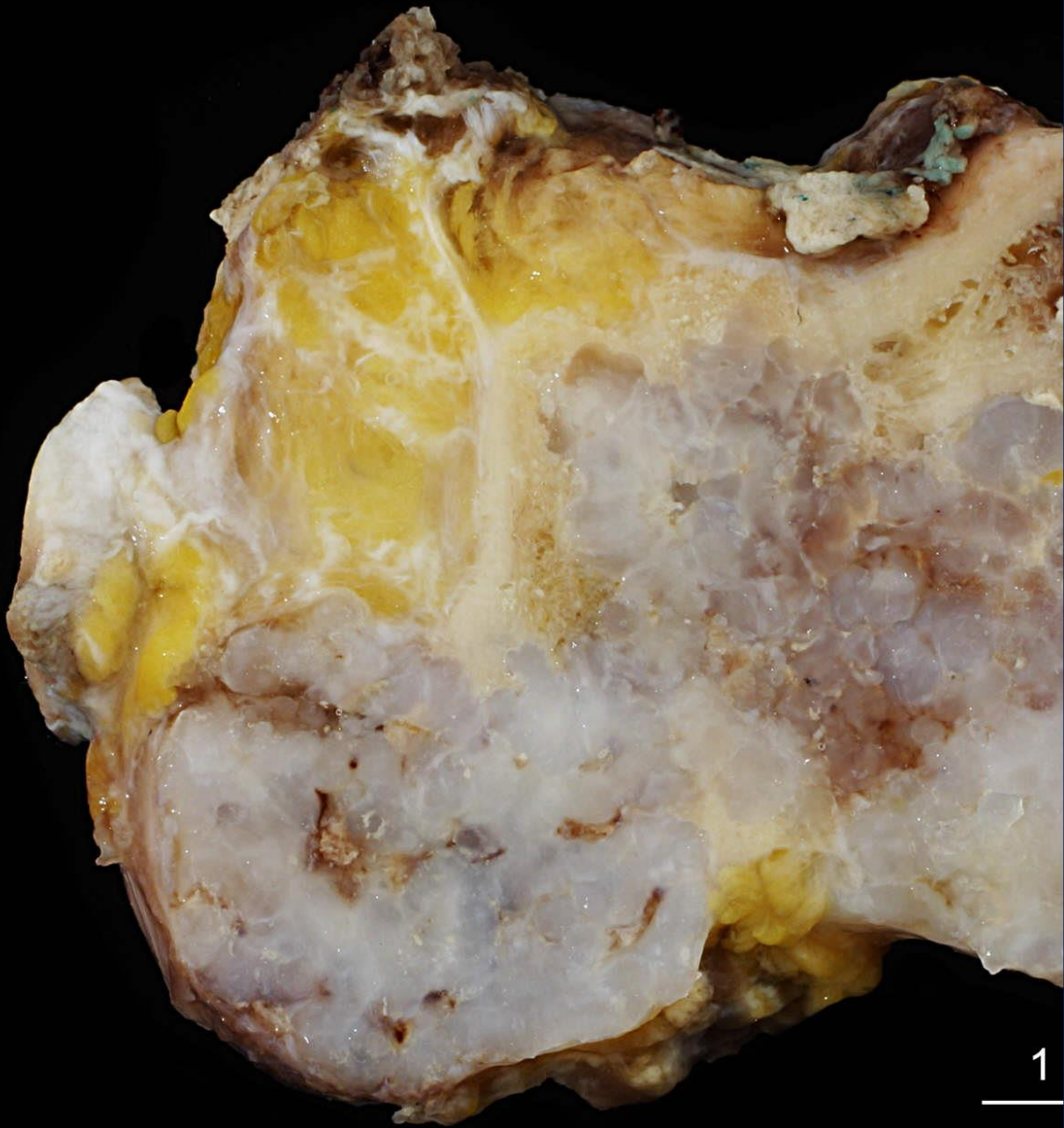


1 cm

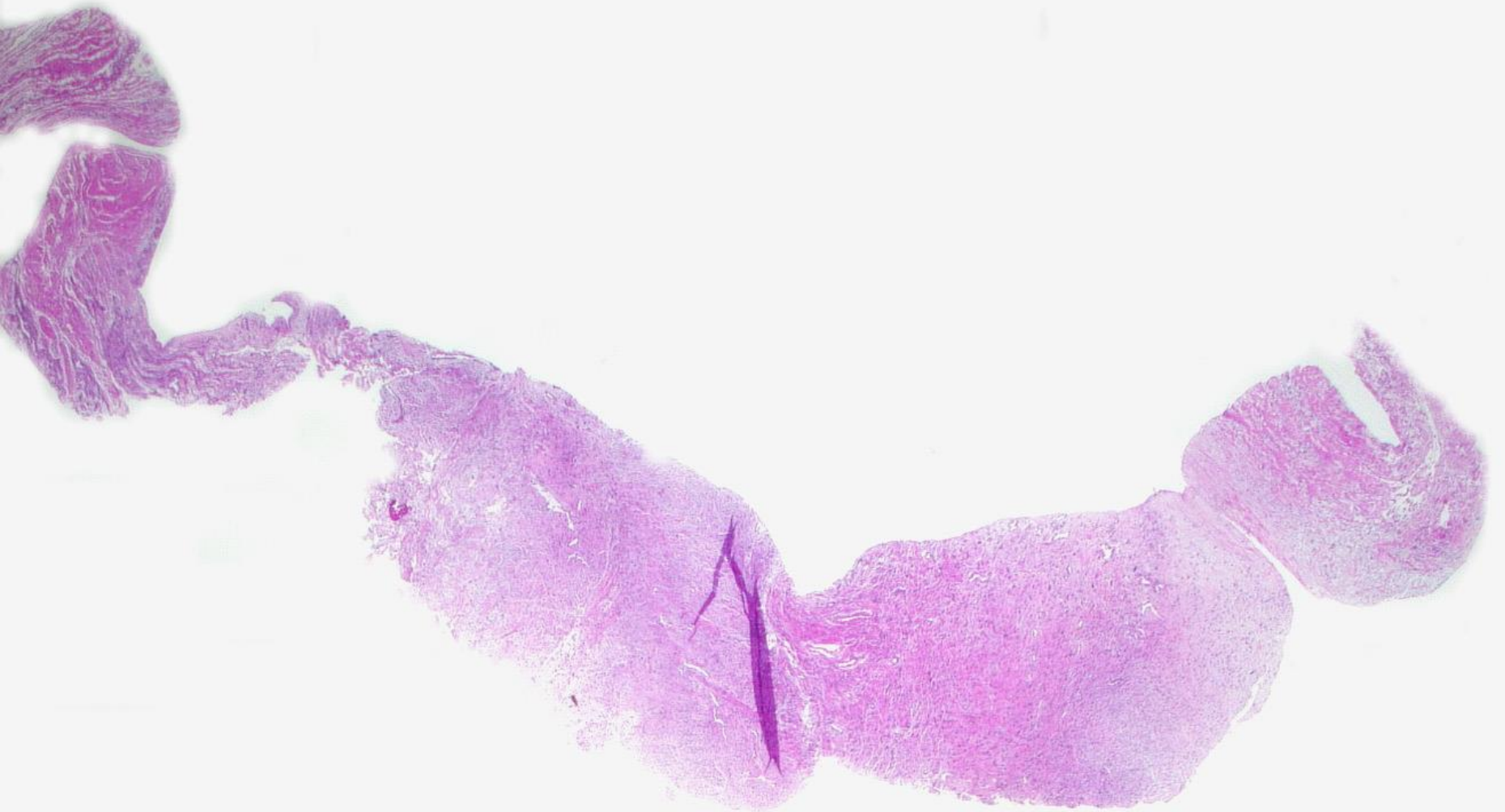


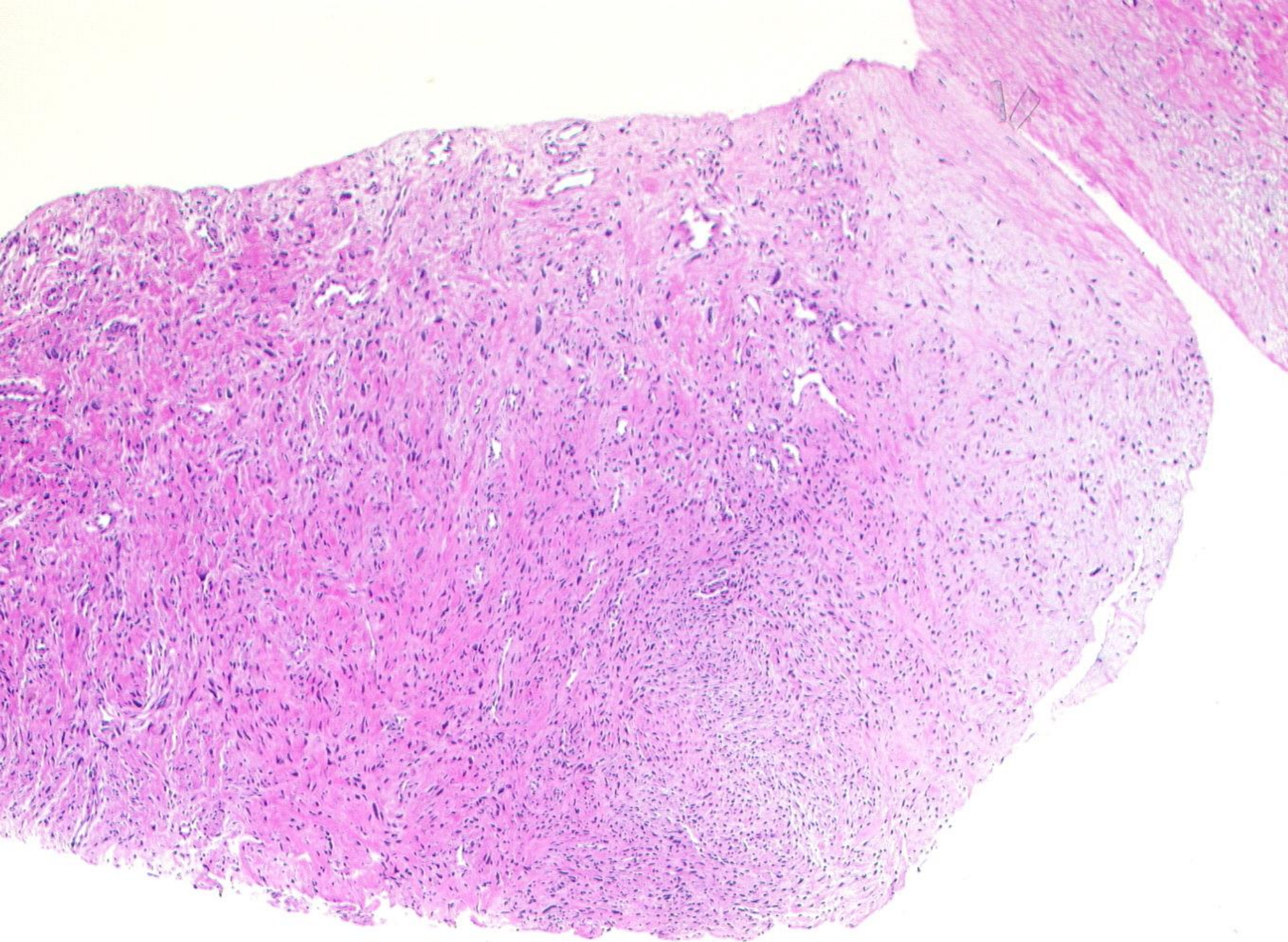


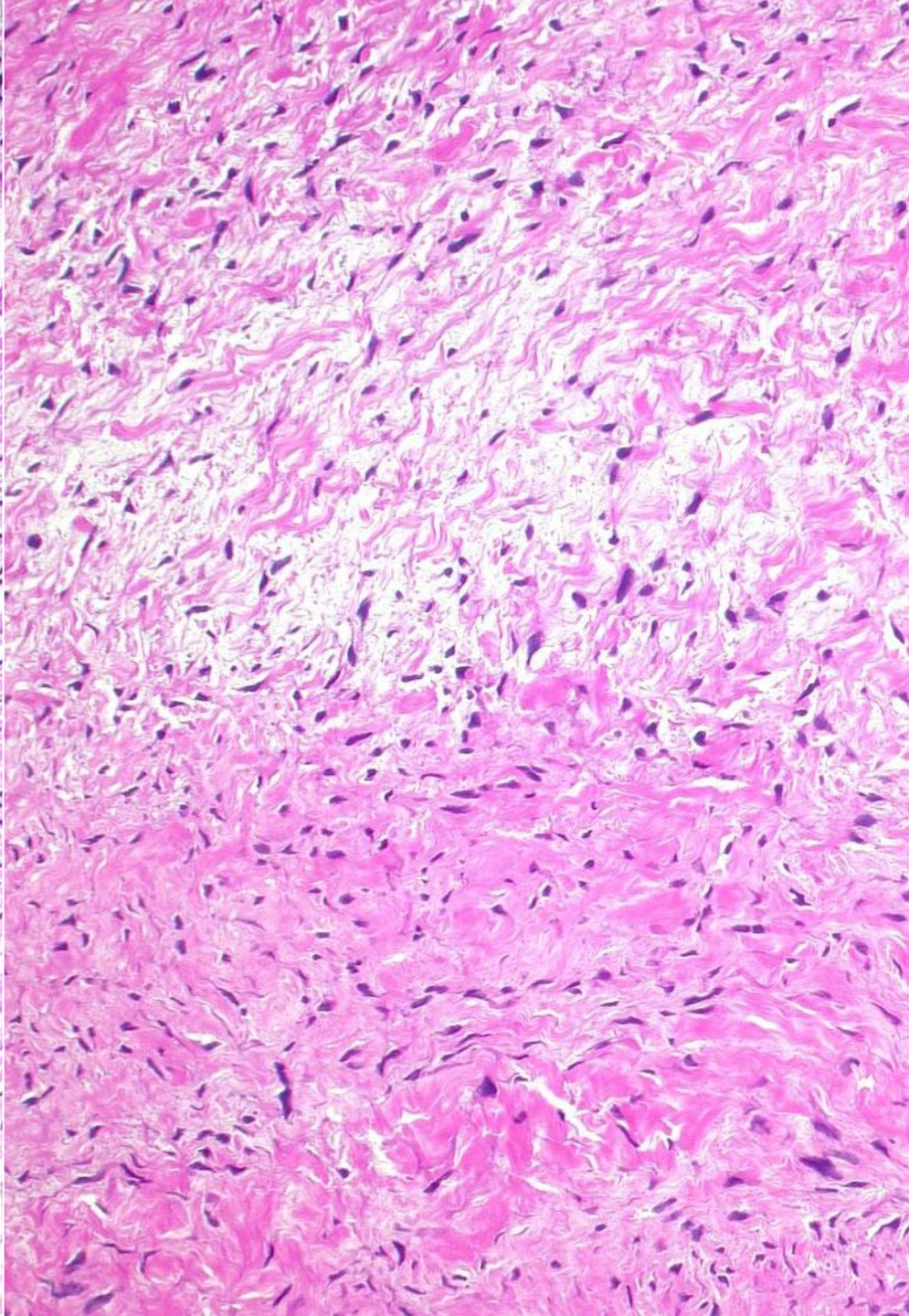
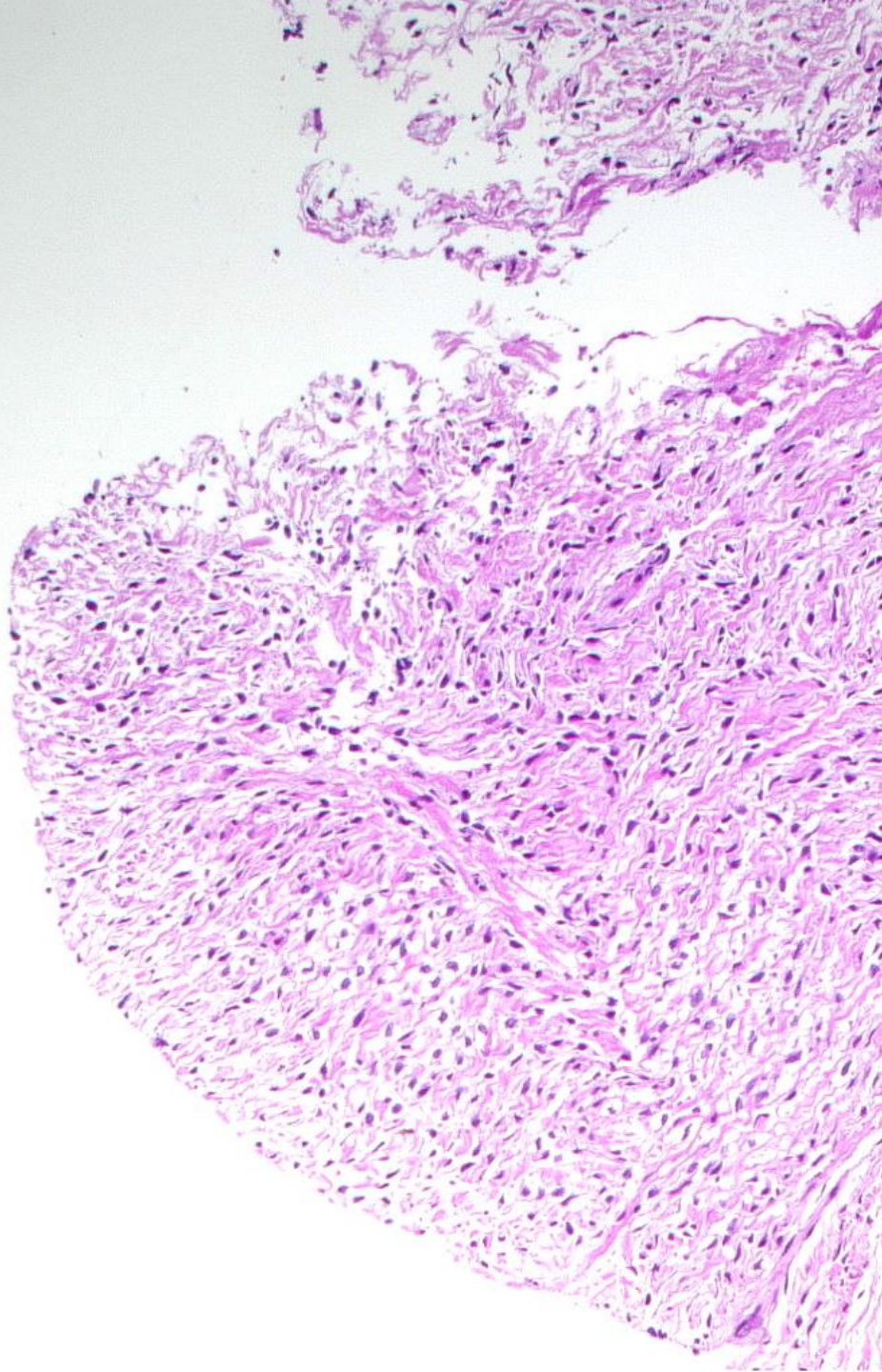
Cervix, partial, uterine

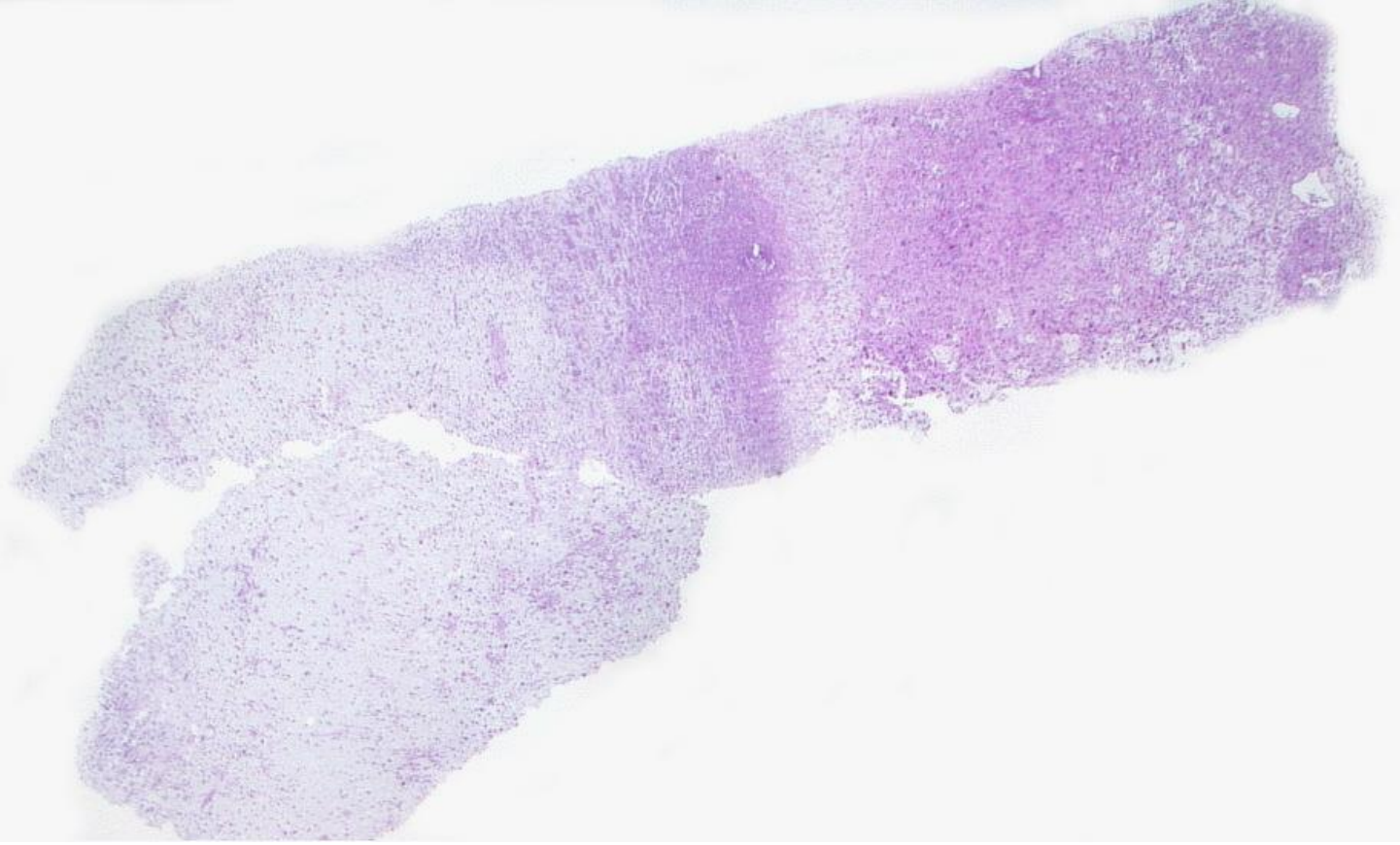


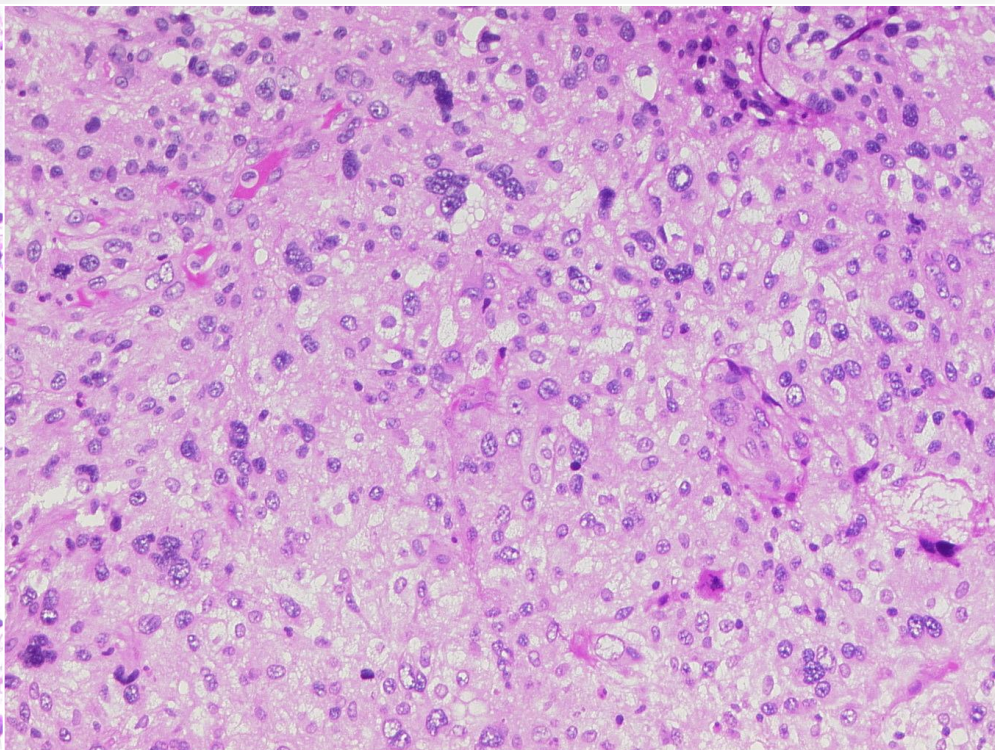
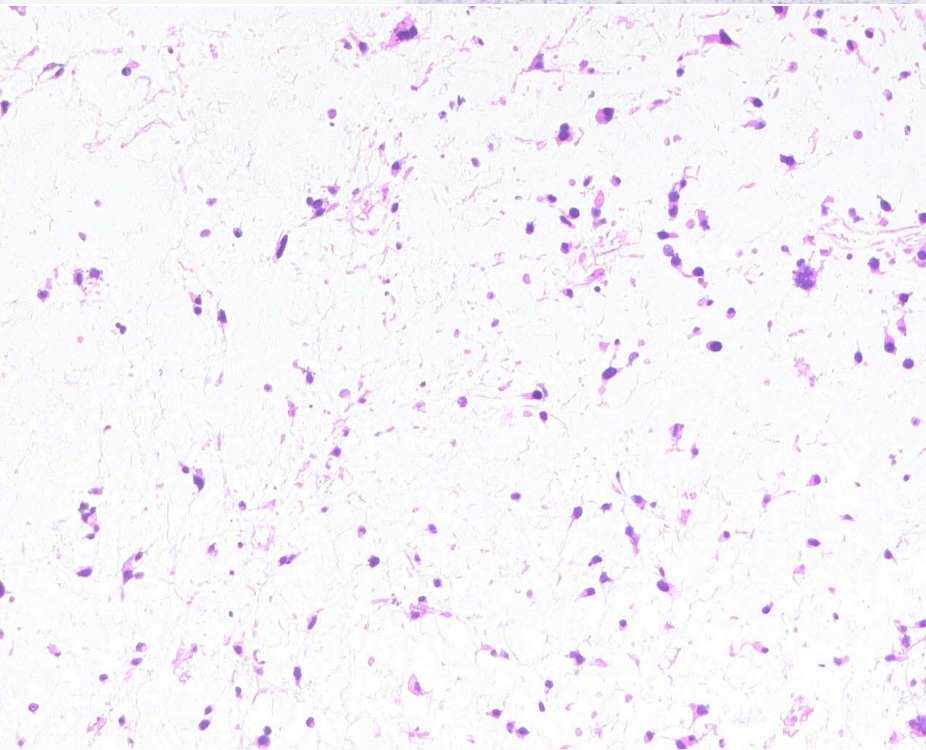
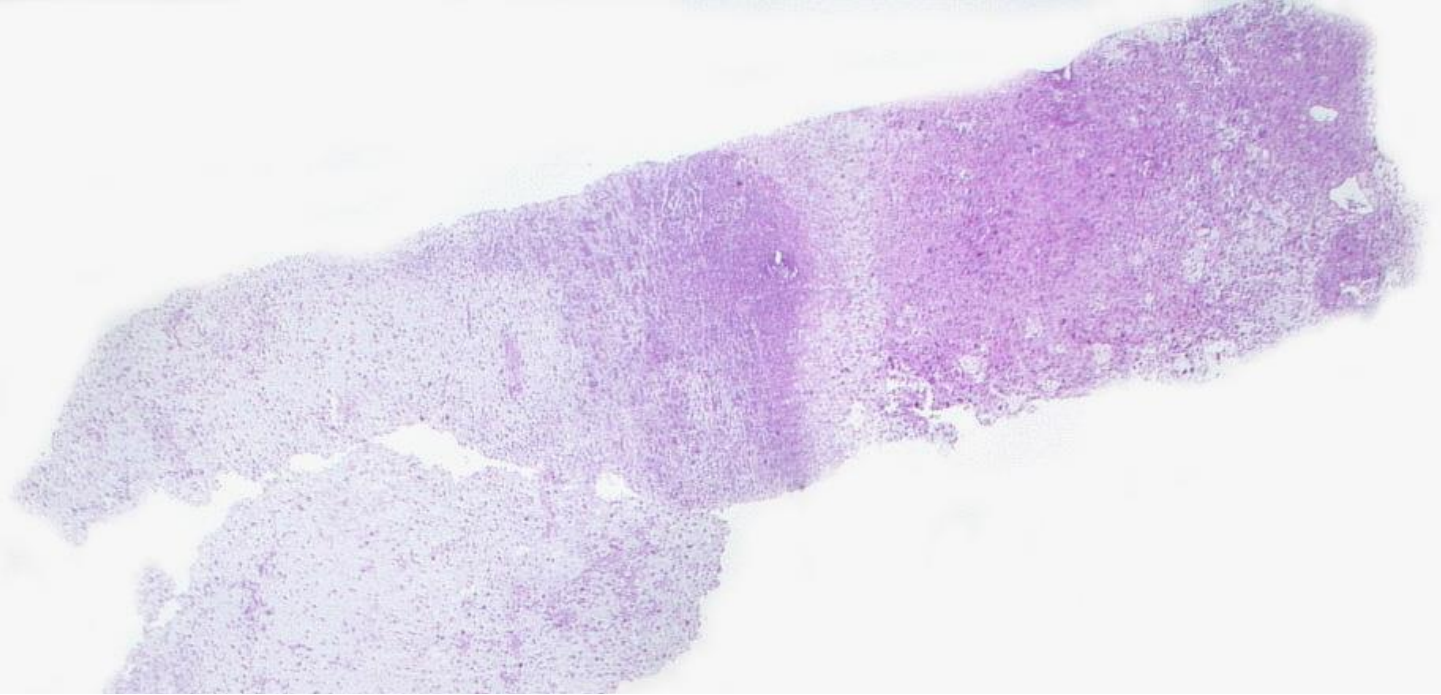
B2008-30311-1

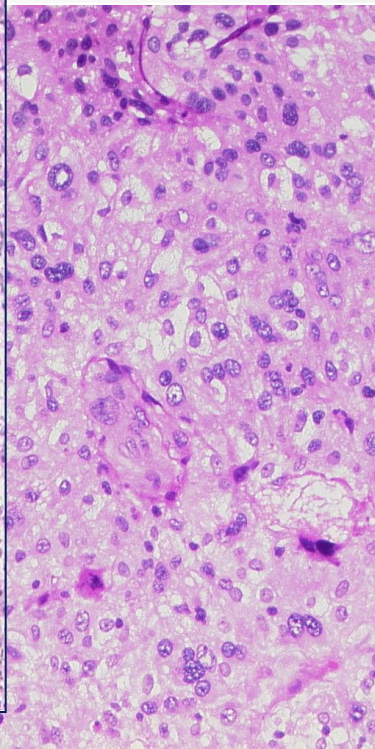
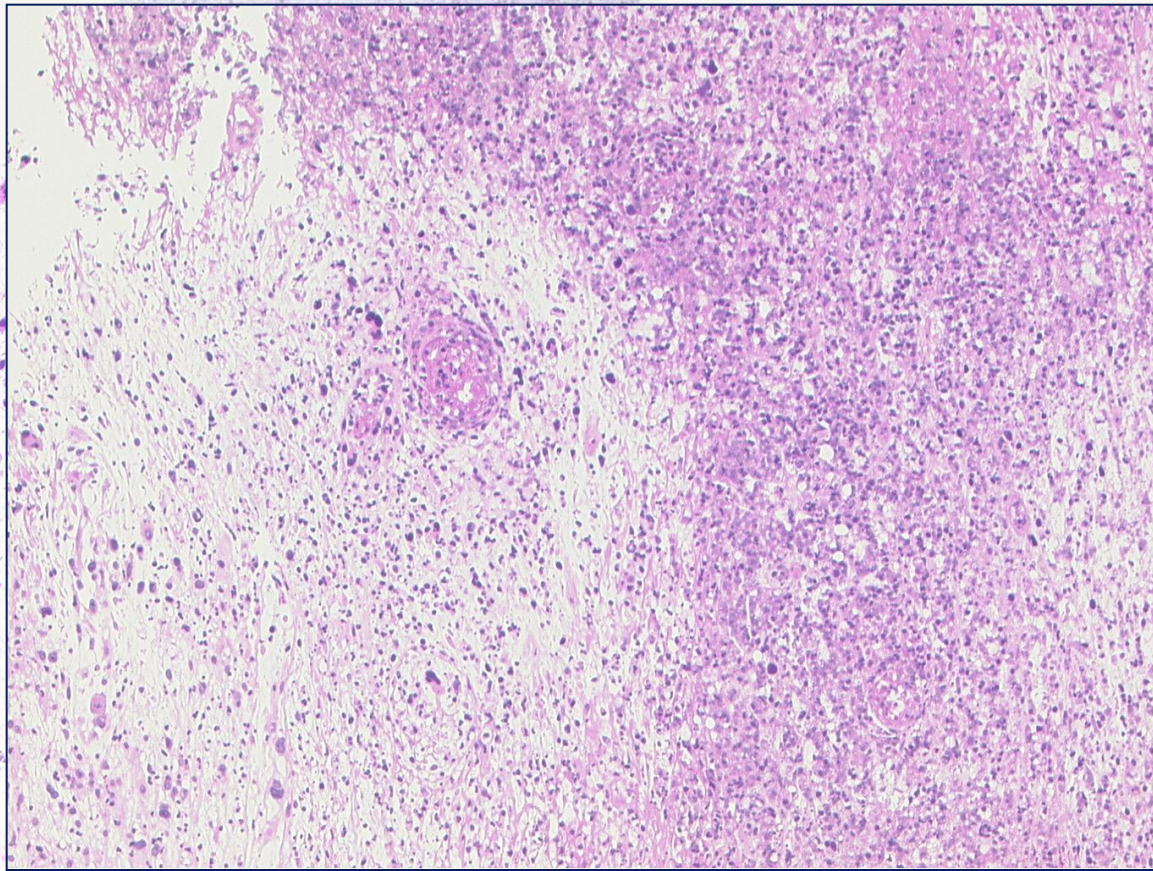
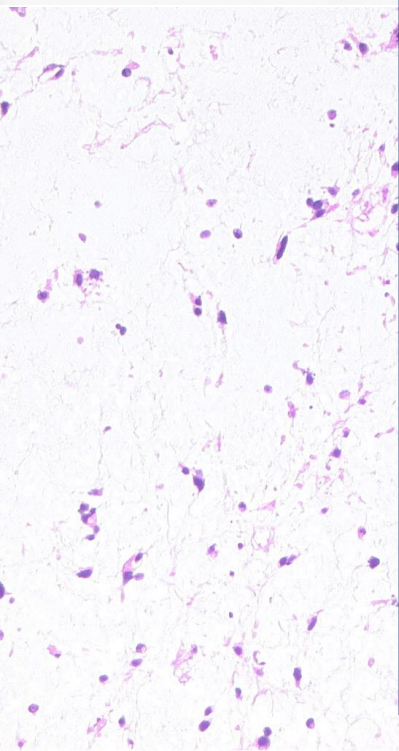
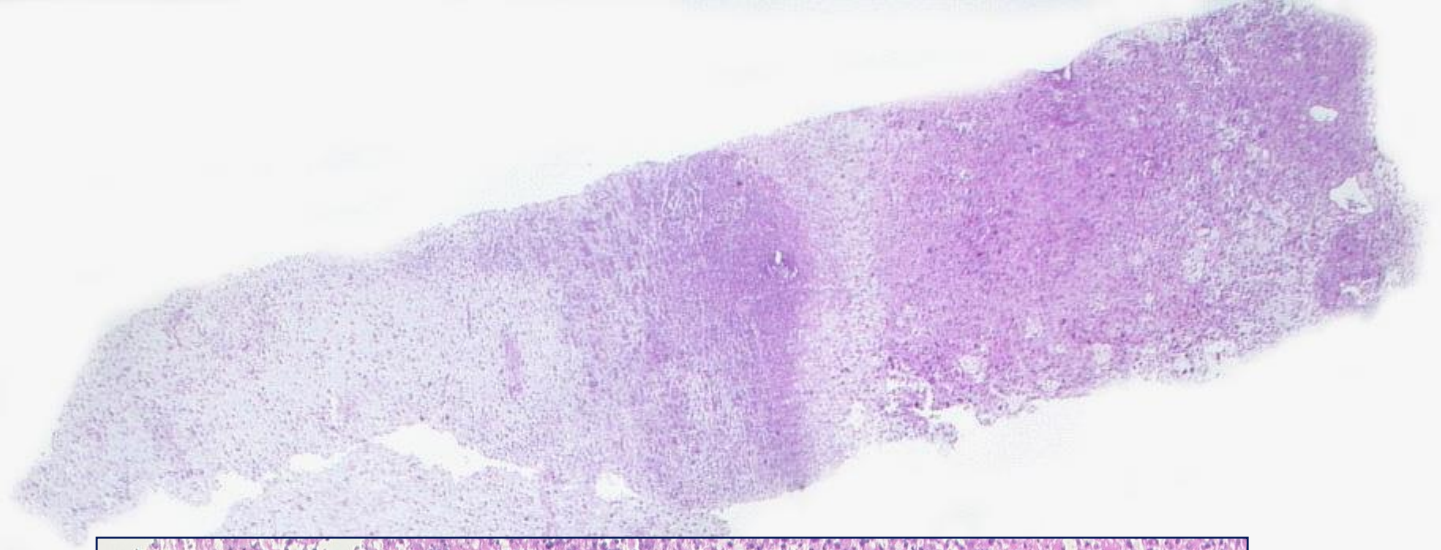


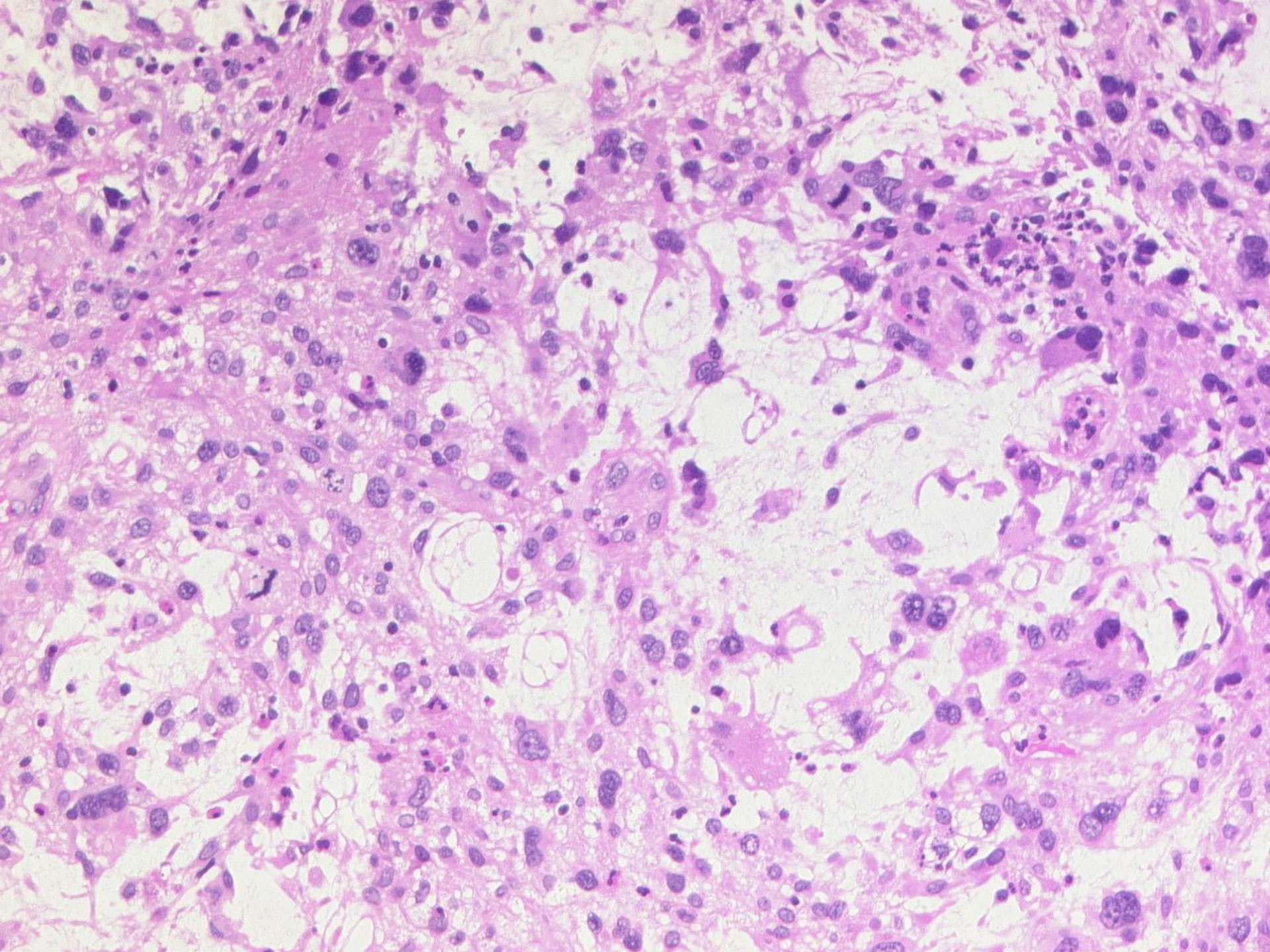


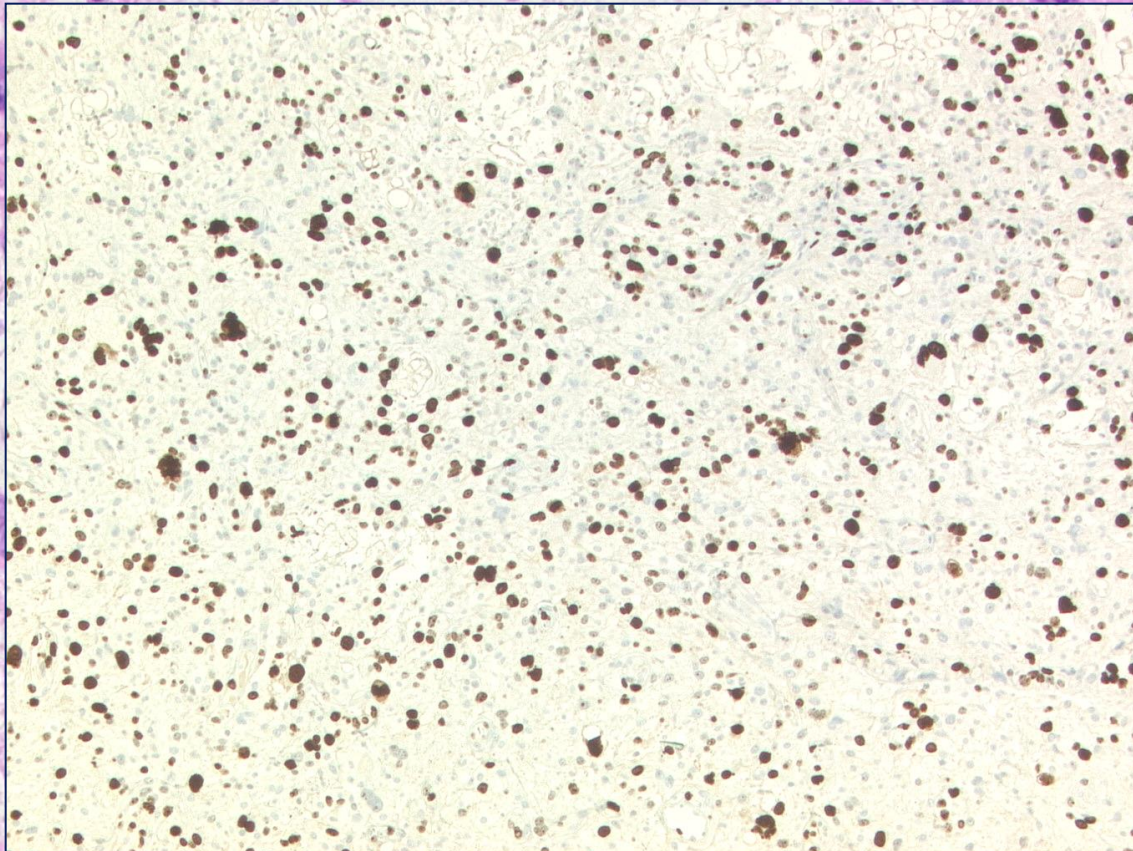
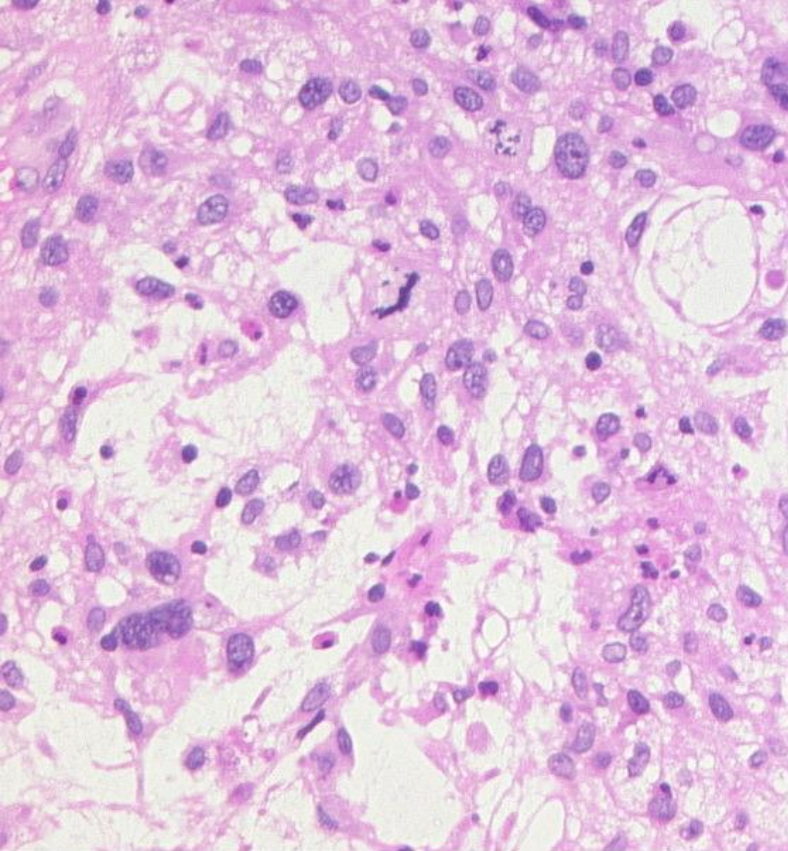
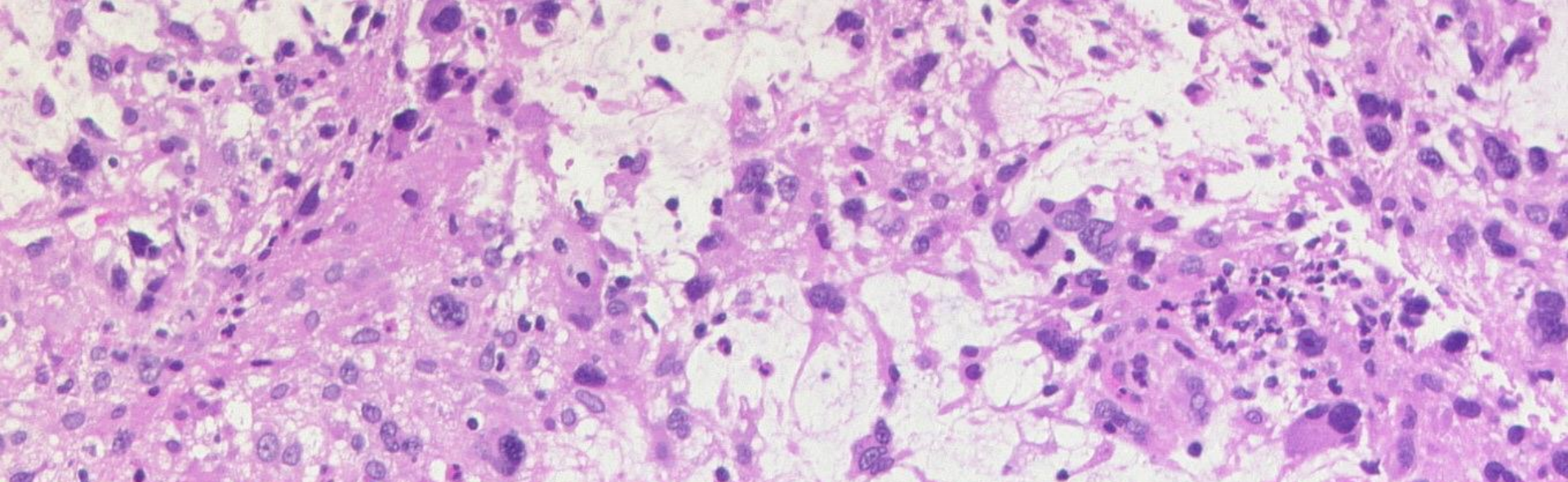




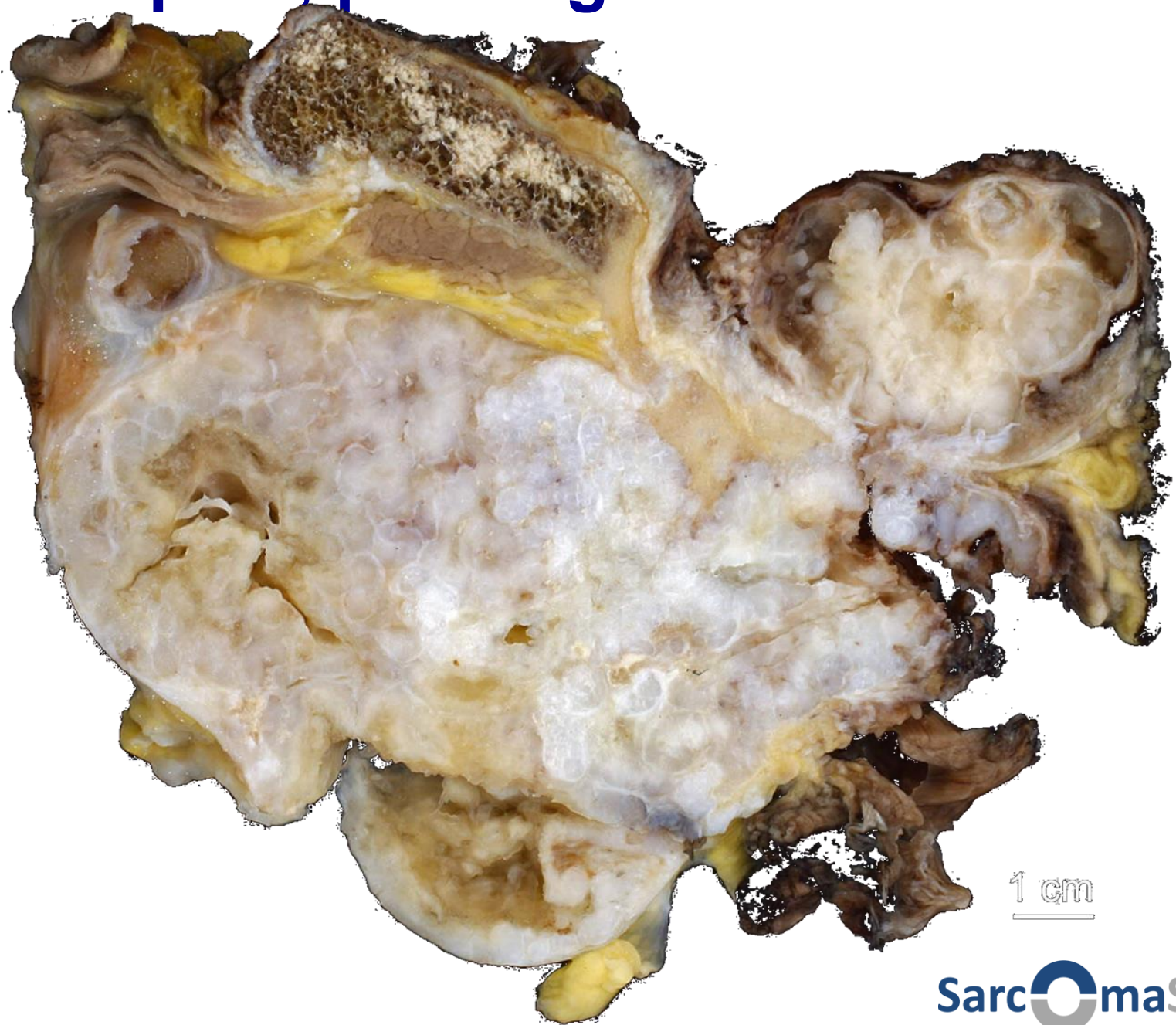




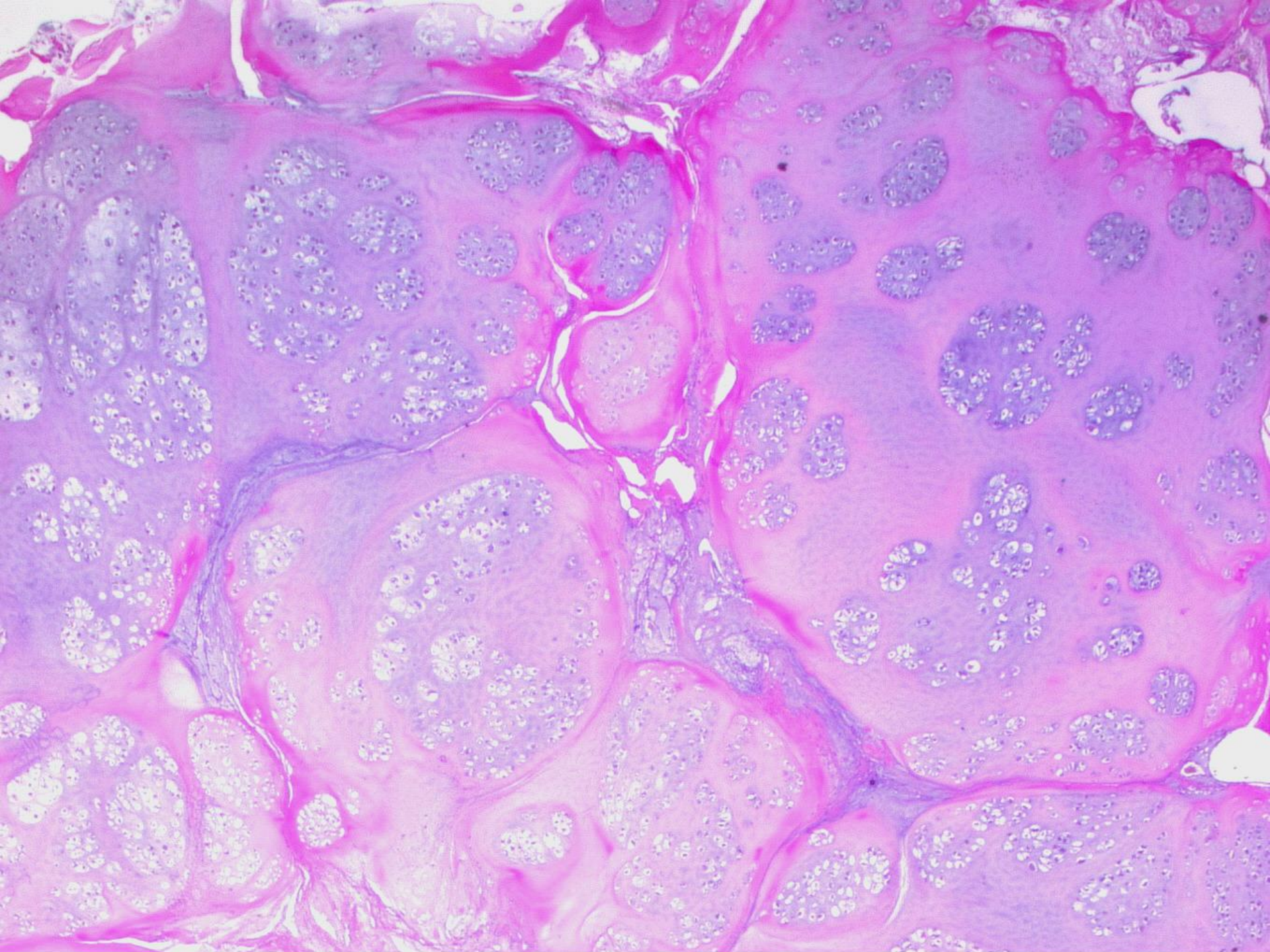


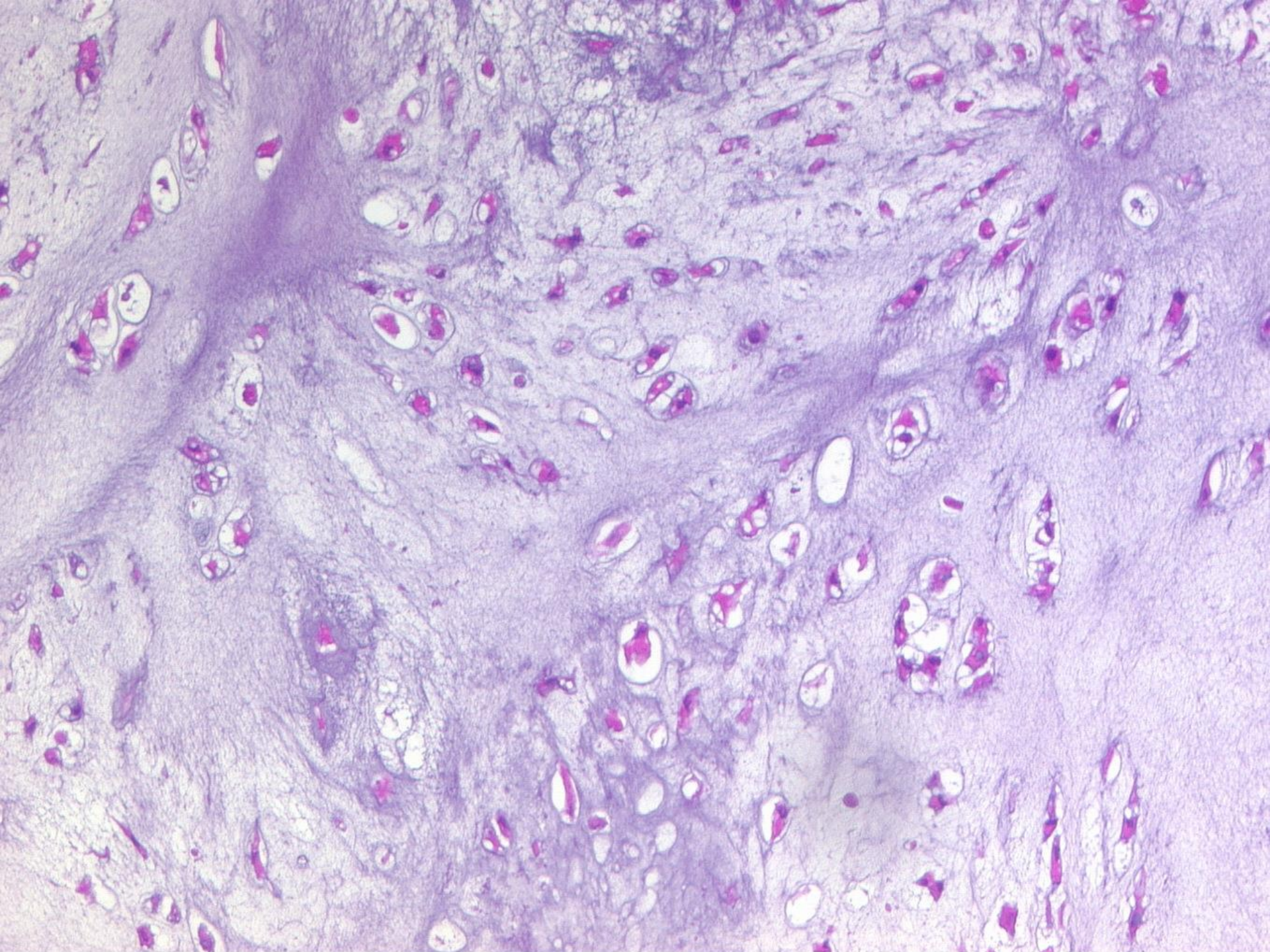


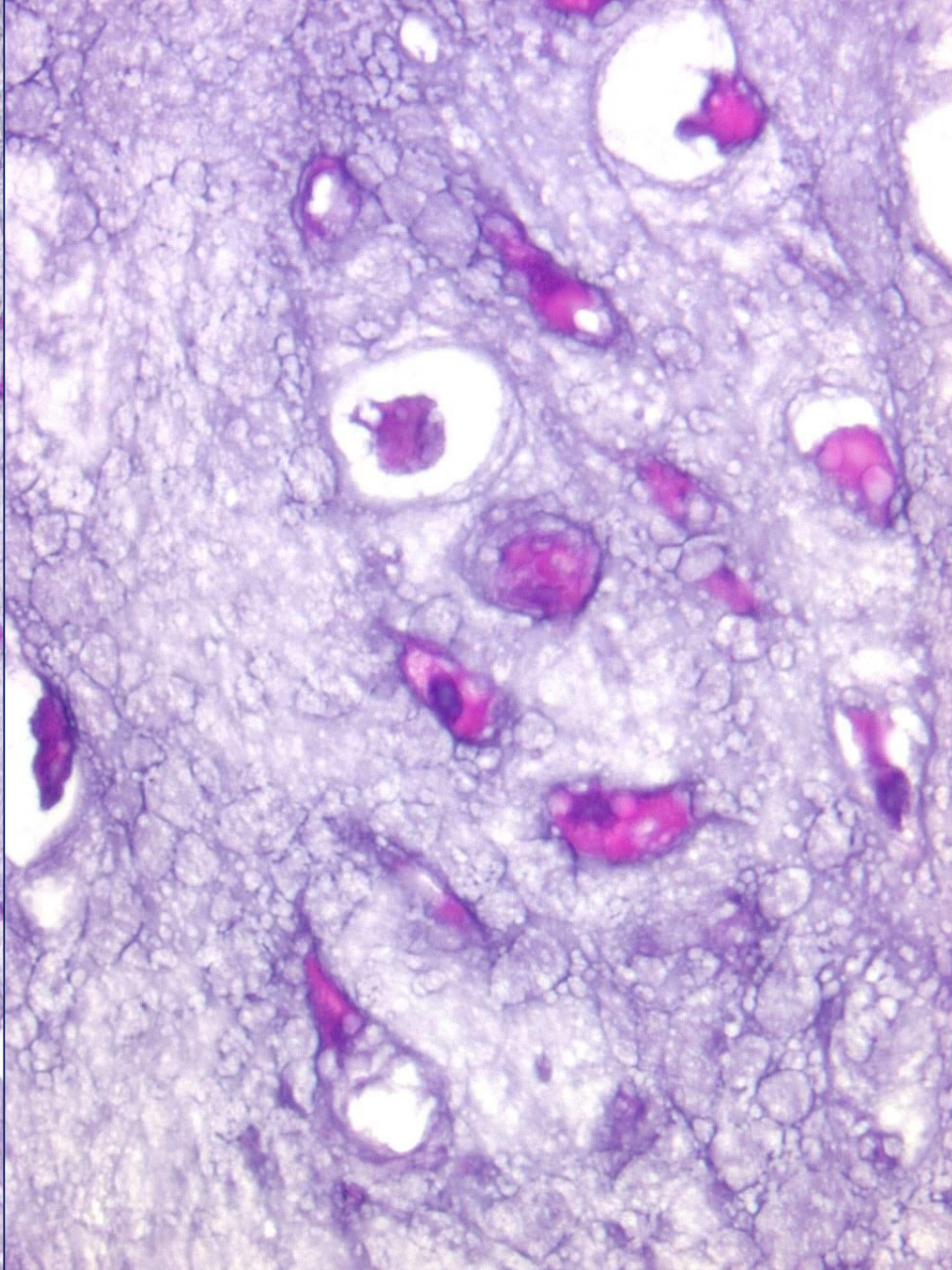
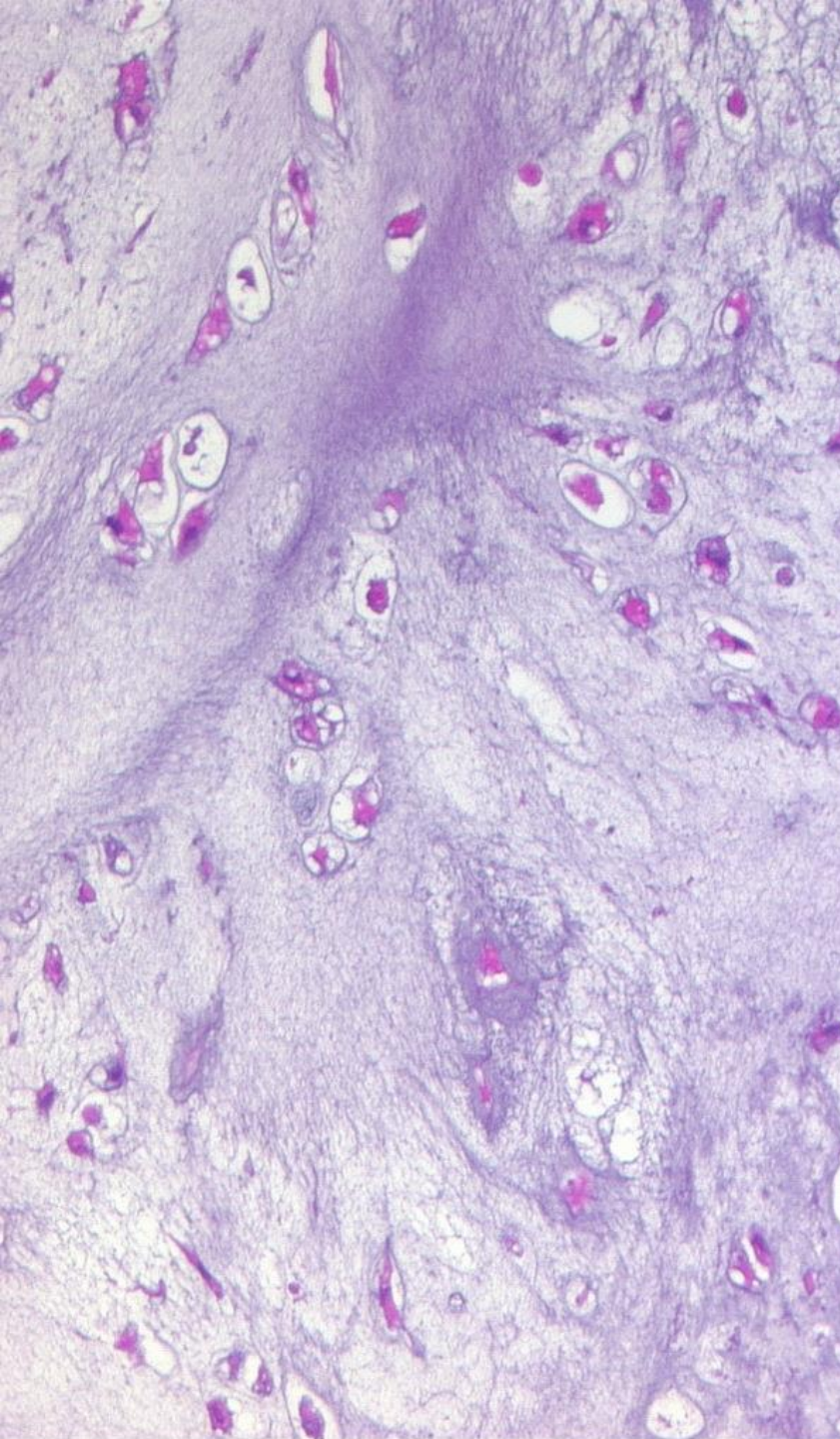
Scapula; partial glenoid resection

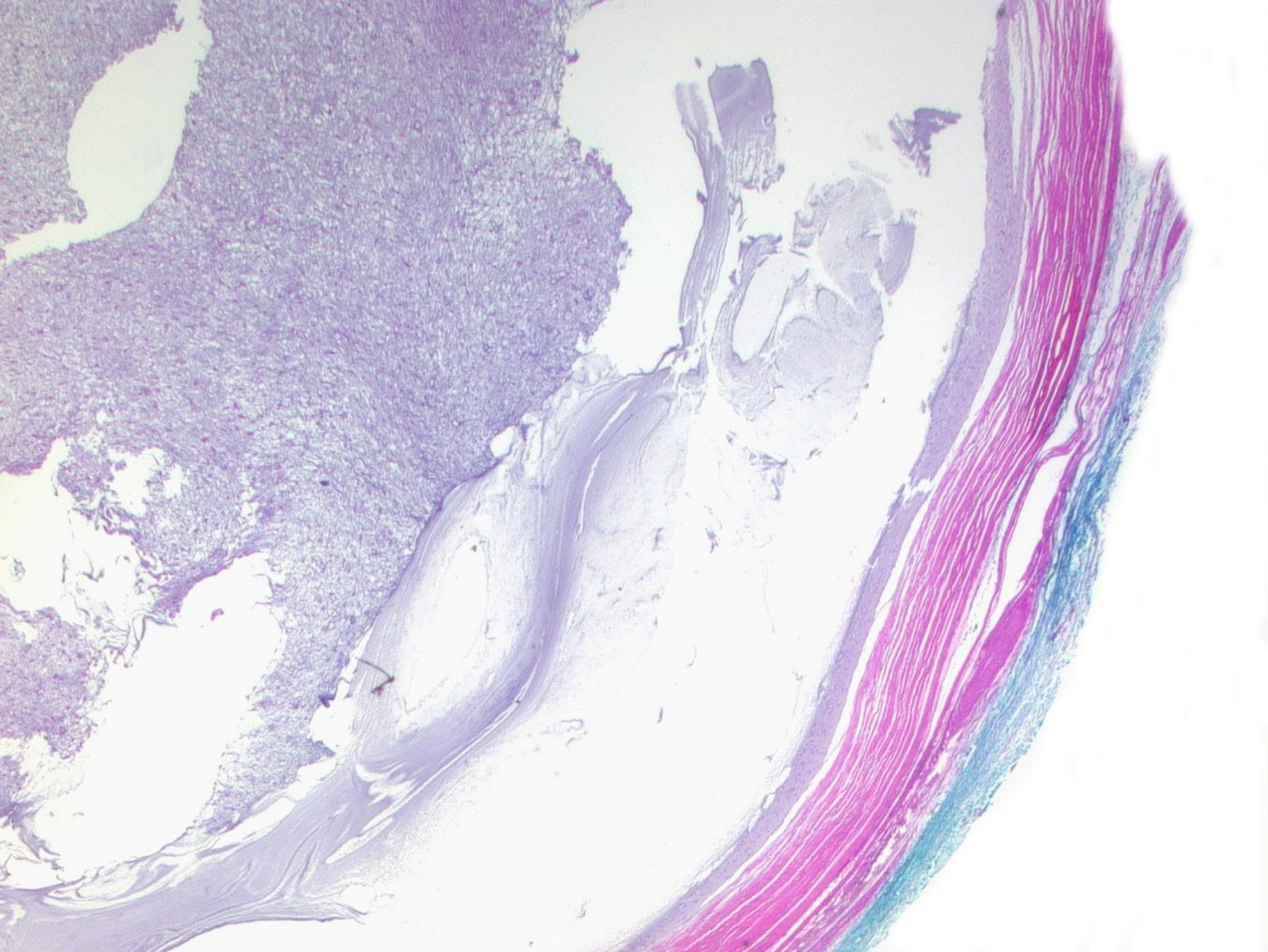


1 cm



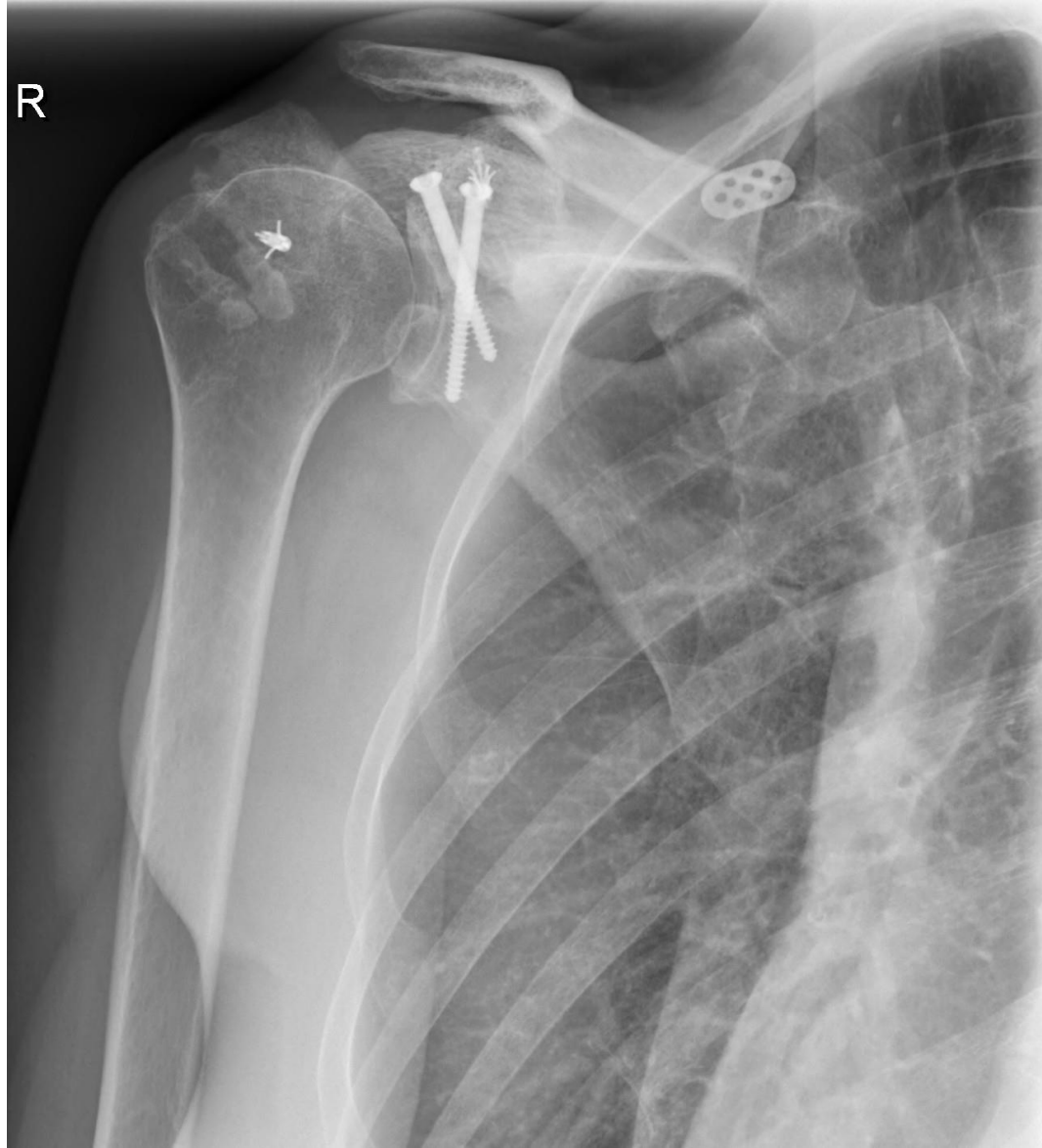






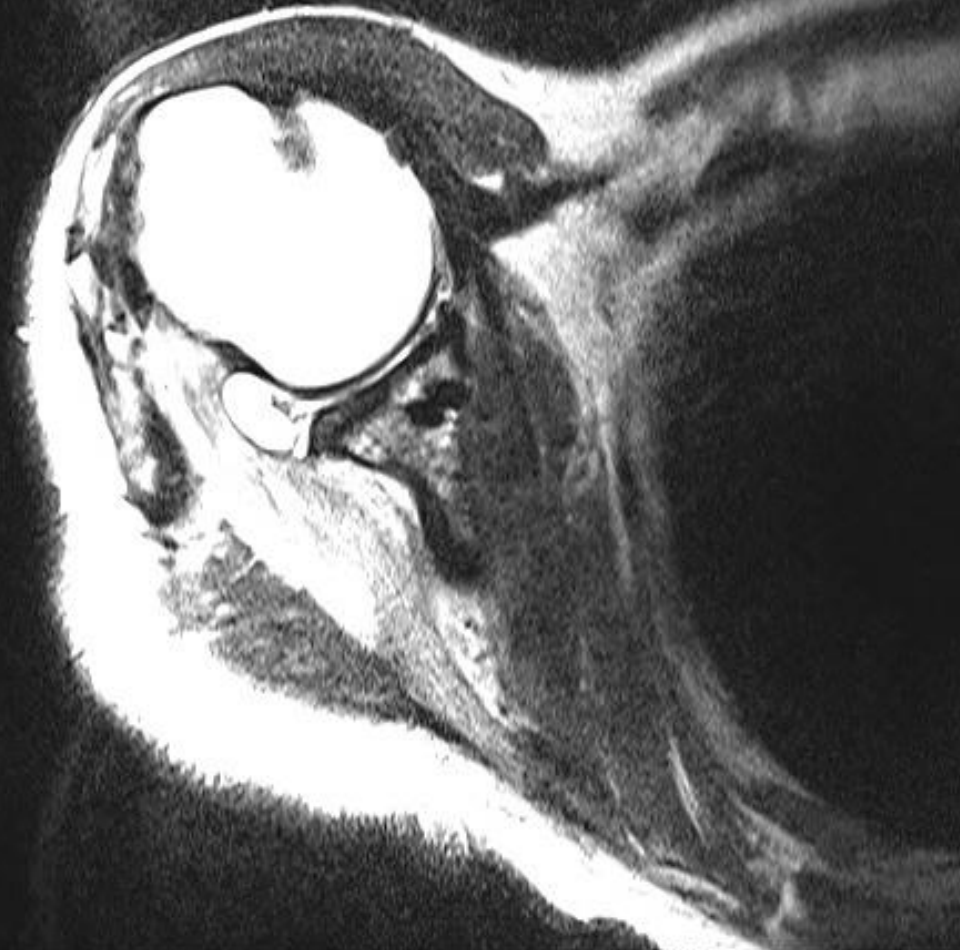
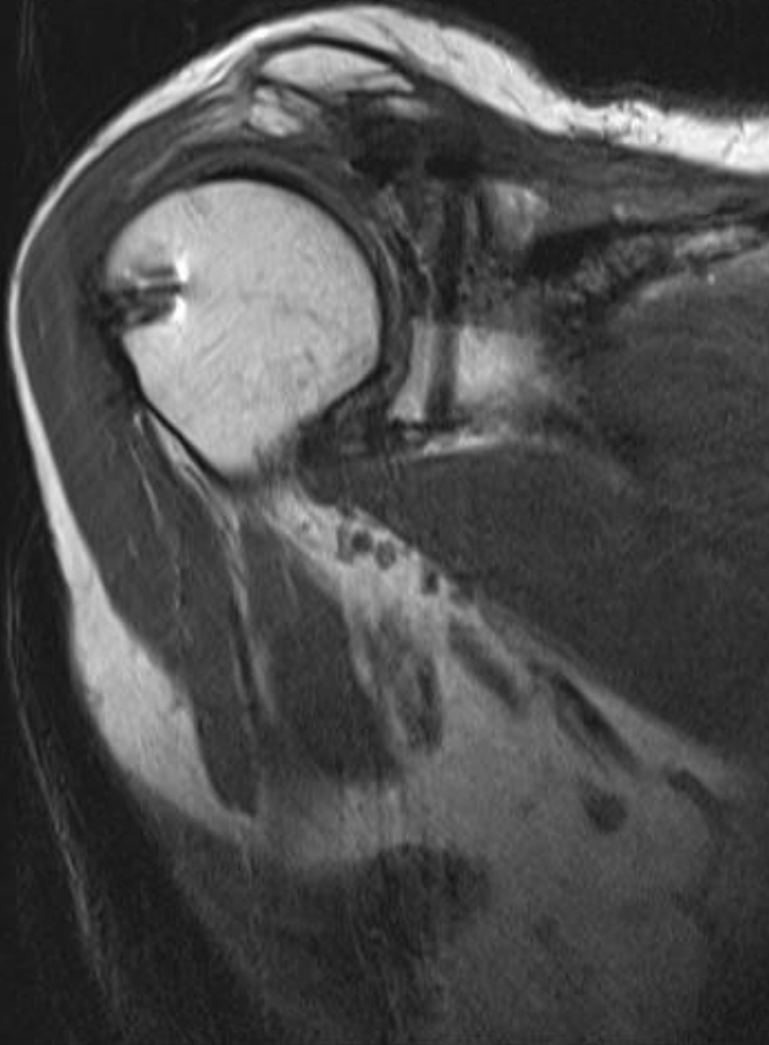
Scapula; partial glenoid resection

Xray shoulder, June 02, 2010

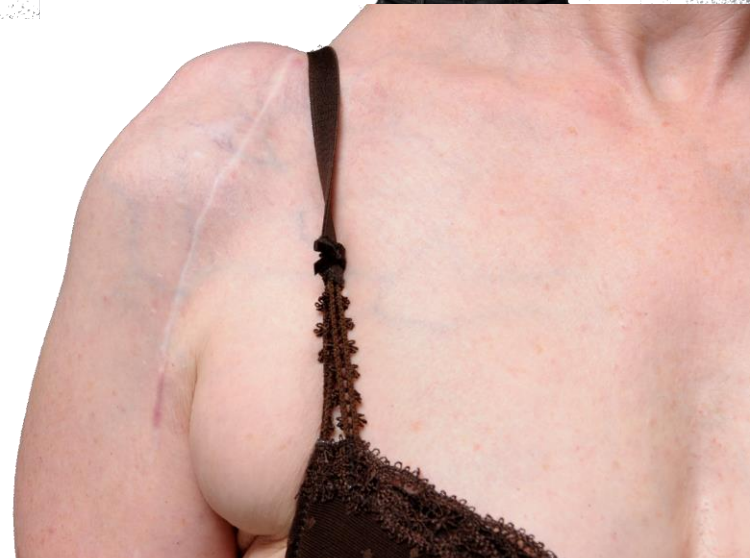
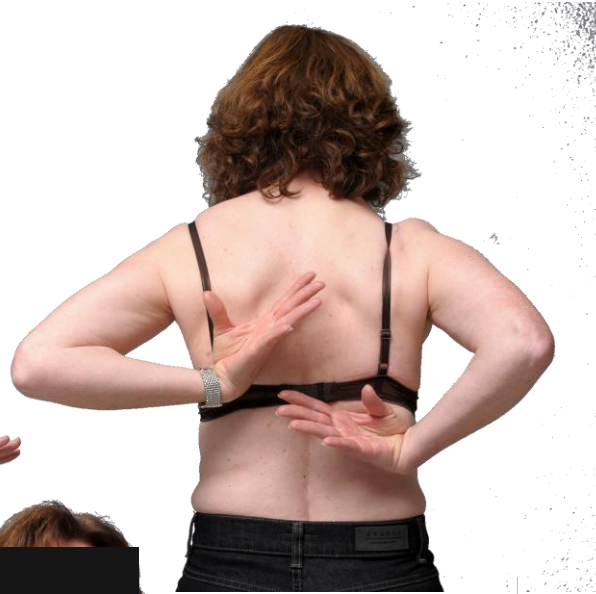


Scapula; partial glenoid resection

MRI shoulder, Dec 07, 2011



Scapula; partial glenoid resection 3 ½ years post surgery, Dec 07, 2011



Scapula; partial glenoid resection 3 1/2 years post surgery, Dec 07, 2011

