

Shoulder; extraarticular; arthrodesis

♂ 21 yo

Patient treated outside

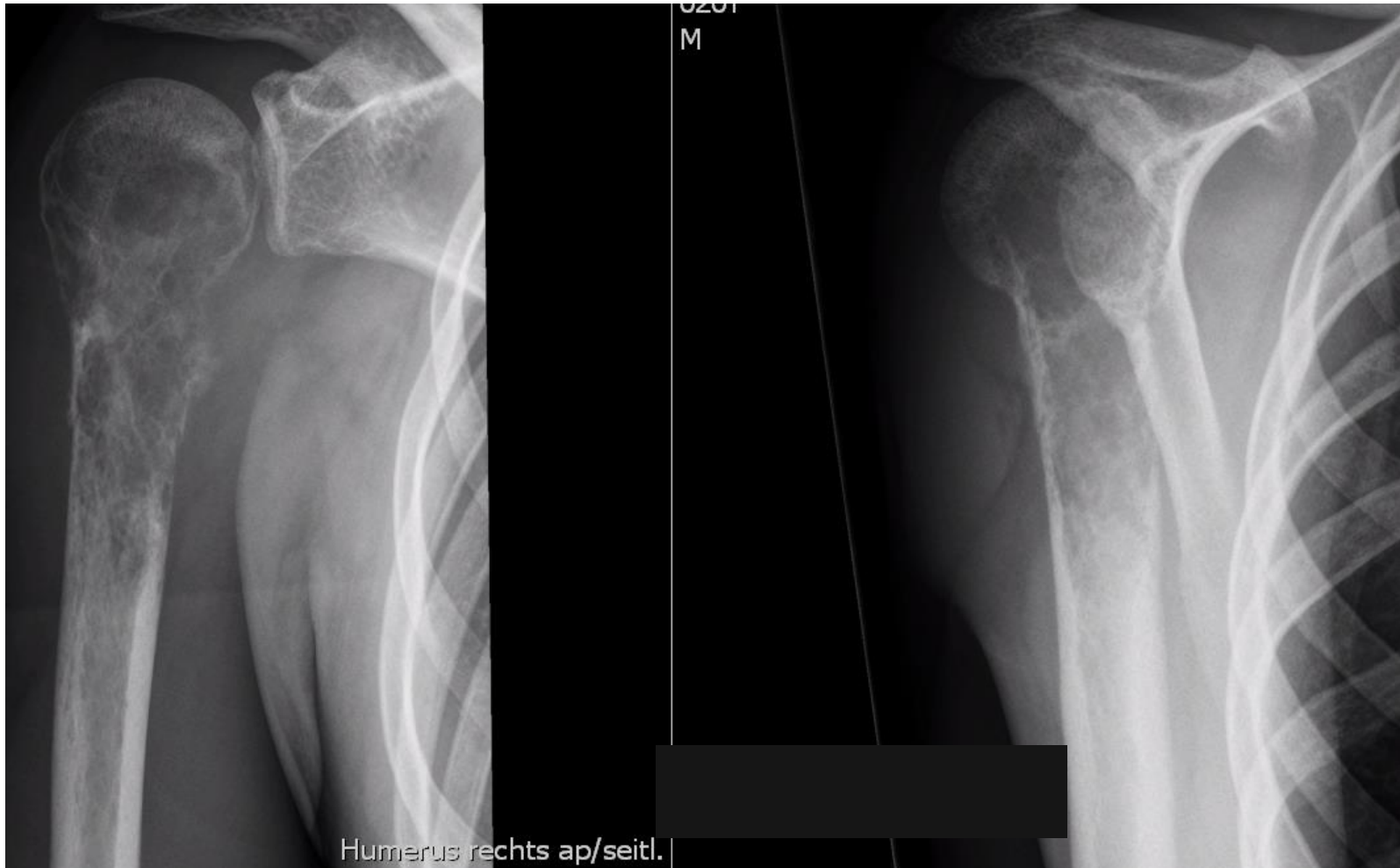
PMH:

High-grade osteosarcoma of right humerus

- 1st imaging in St. Gallen in dec '12 (MRI,CT,RX on dec 27th, 2012): no signs for locoregional or distant Mx
- CT-guided biopsy on dec 28th, 2012: high-grade osteosarcoma
- s/p sperm-cryoconservation on Jan 3rd, 2013
- s/p port-a-cath on Jan 9th, 2013
- Jan 10th, 2013: start of chemotherapy EURAMOS (AP)
- **Feb 15th 2013: start of 2nd cycle (MAP)**

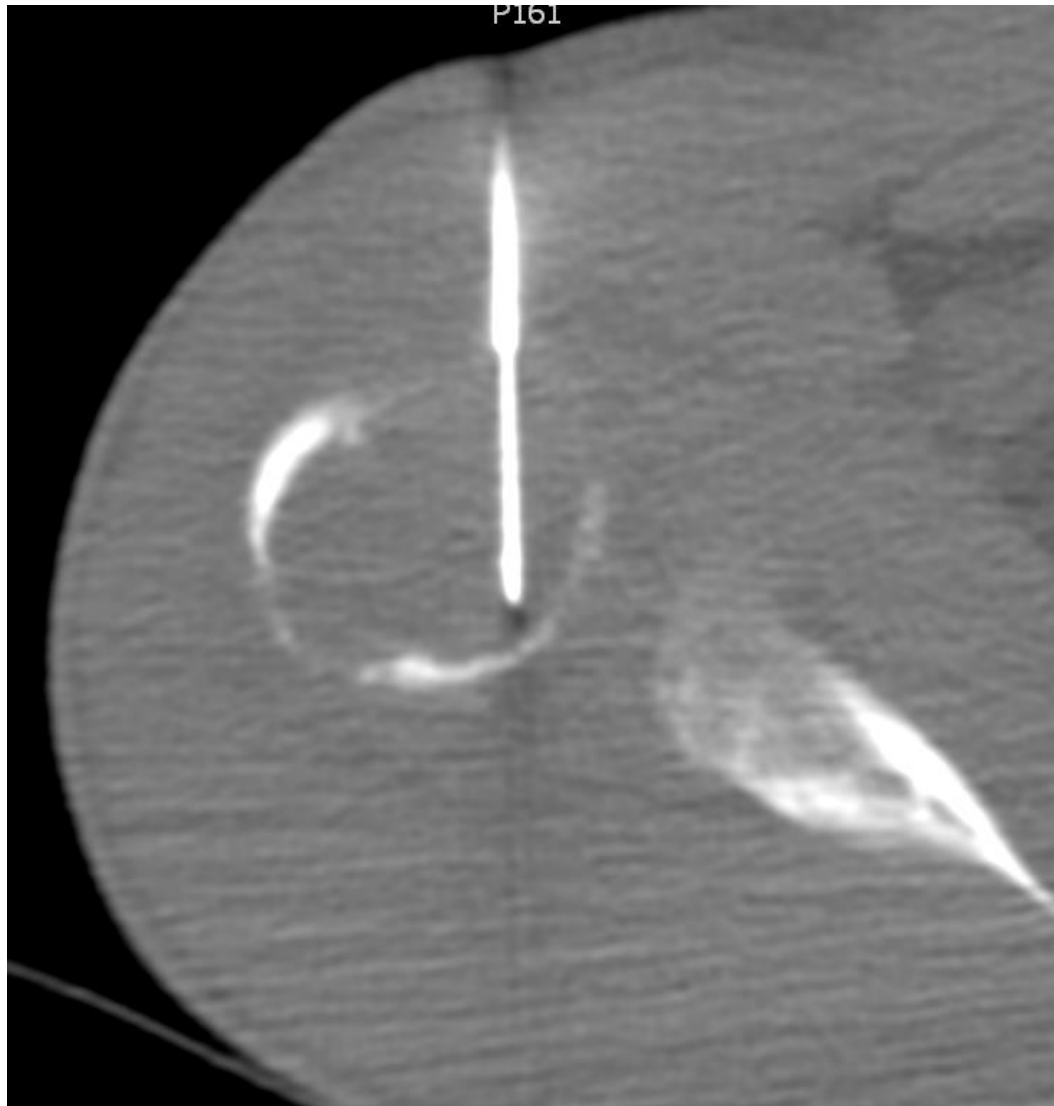
Shoulder; extraarticular; arthrodesis

Rx right shoulder: Dec 28th, 2012



Shoulder; extraarticular; arthrodesis

Biopsy (outside): Dec 28th, 2012



Shoulder; extraarticular; arthrodesis

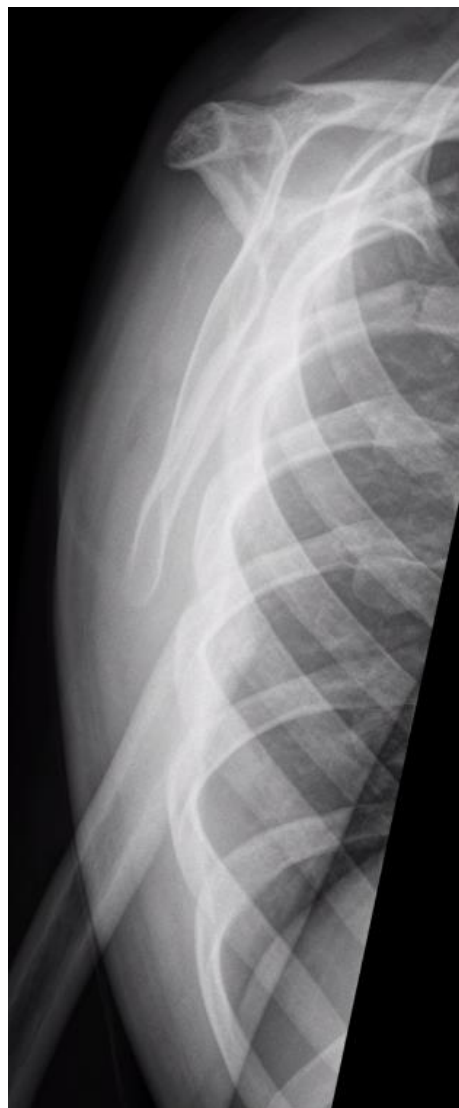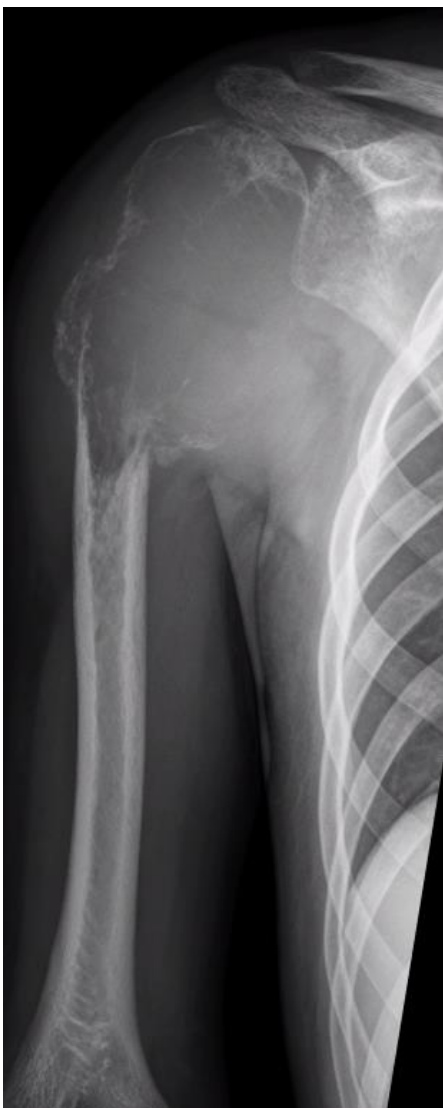♂ 21 yo

Treatment so far:

- Jan 10th, 2013: start of chemotherapy EURAMOS (AP)
- Feb 15th 2013: start of 2nd cycle (MAP)

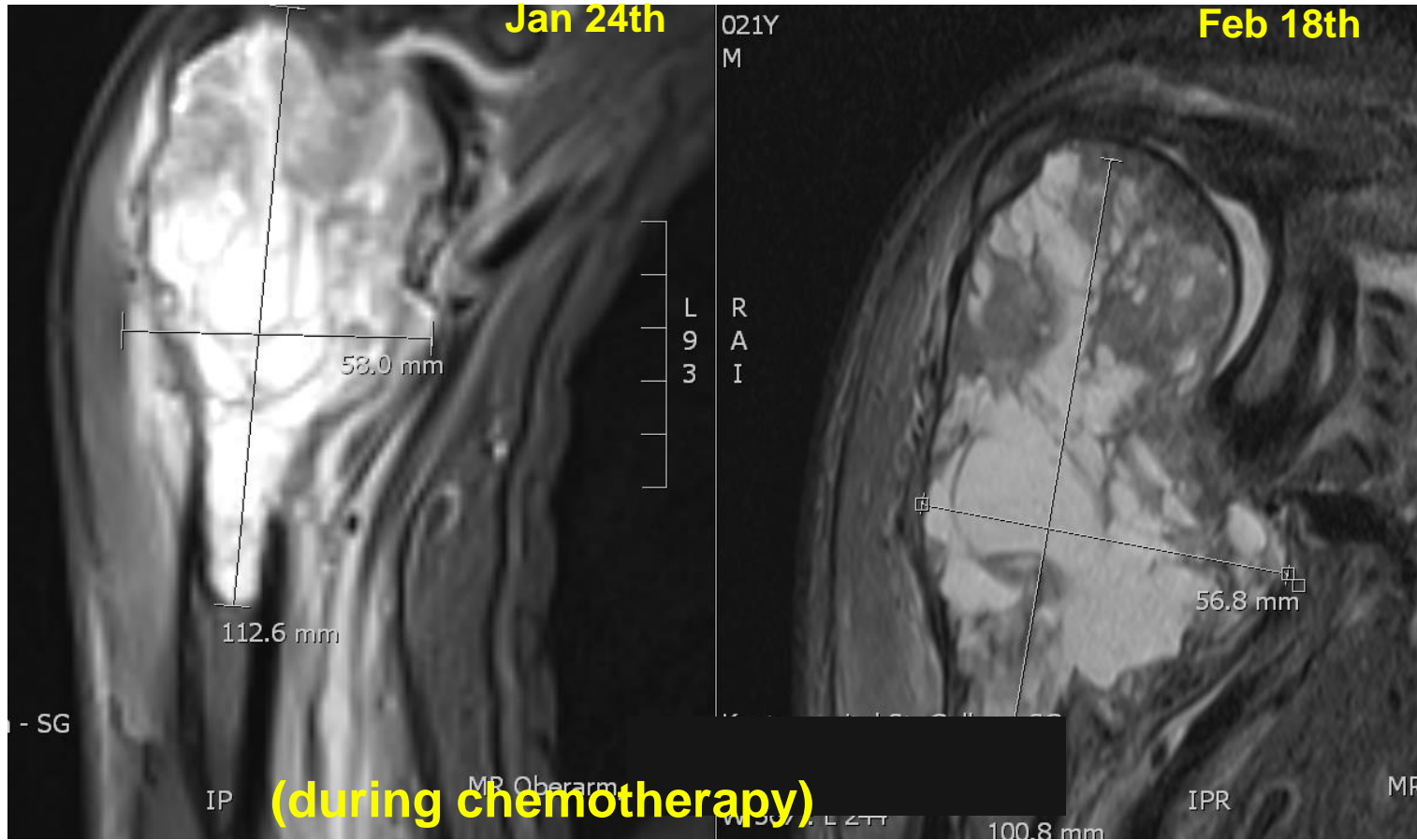
Shoulder; extraarticular; arthrodesis

X-Ray : Feb 15th, 2013



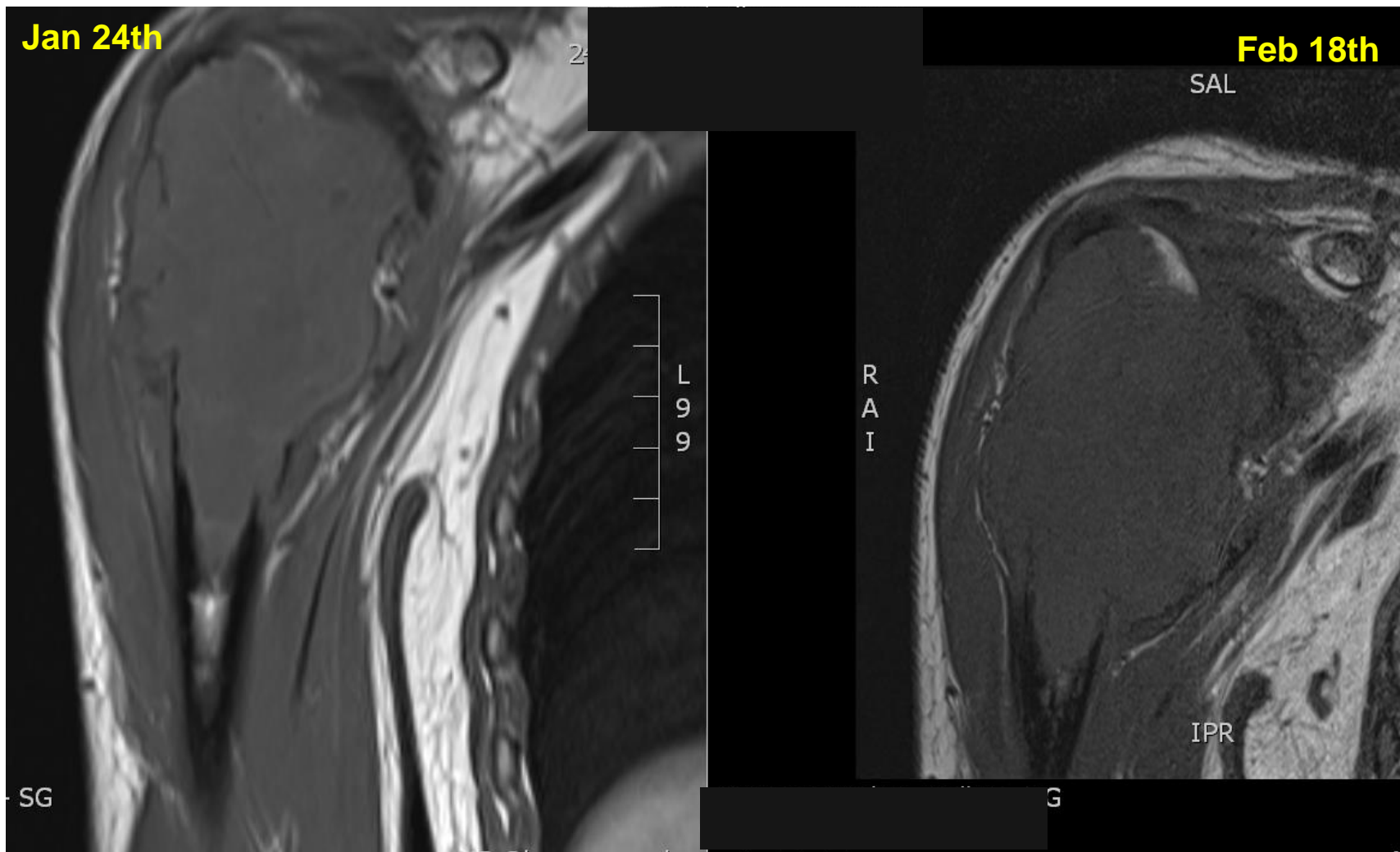
Shoulder; extraarticular; arthrodesis

MRI : Jan 24th vs. Feb 18th, 2013



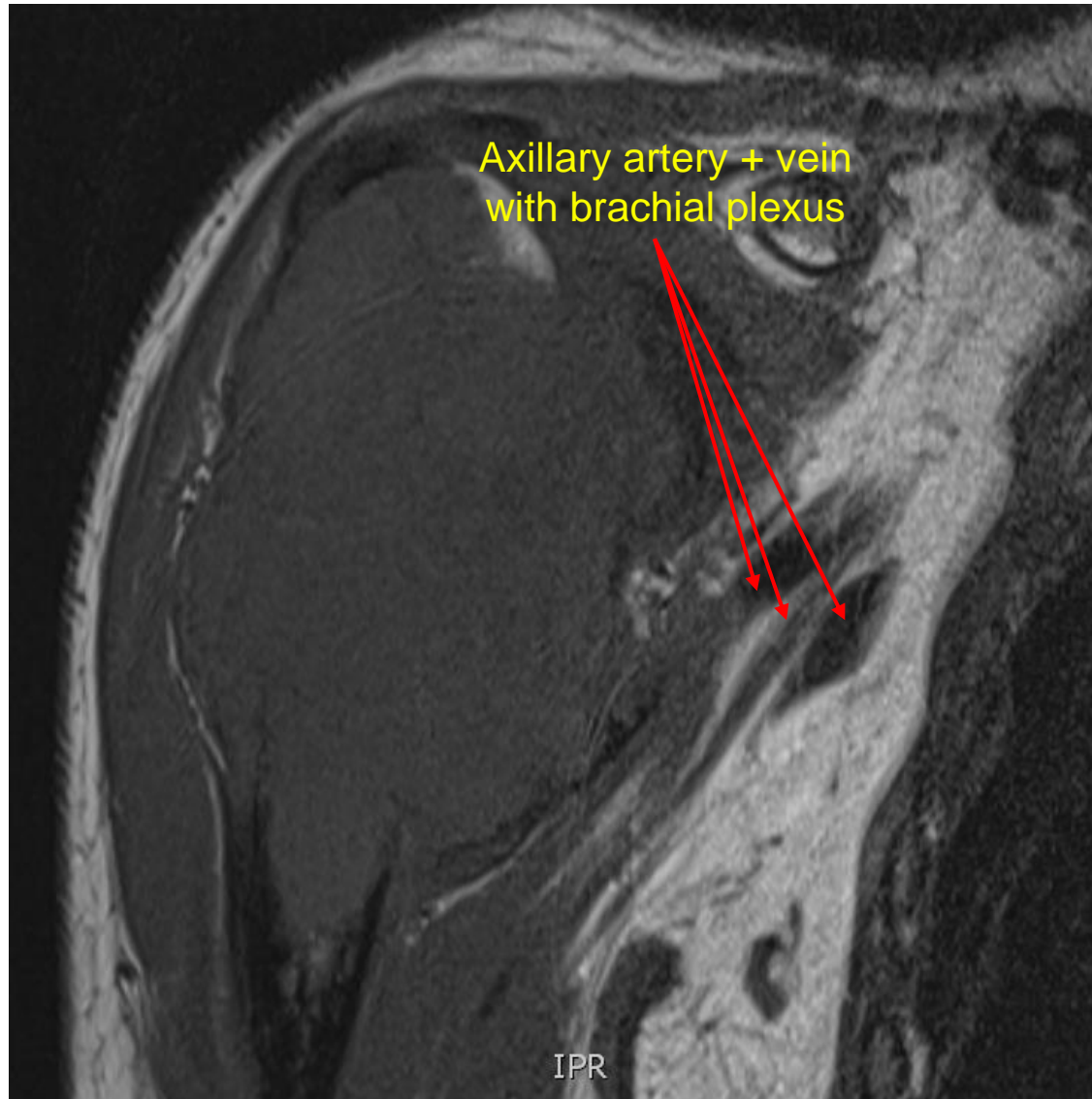
Shoulder; extraarticular; arthrodesis

MRI : Jan 24th vs. Feb 18th, 2013



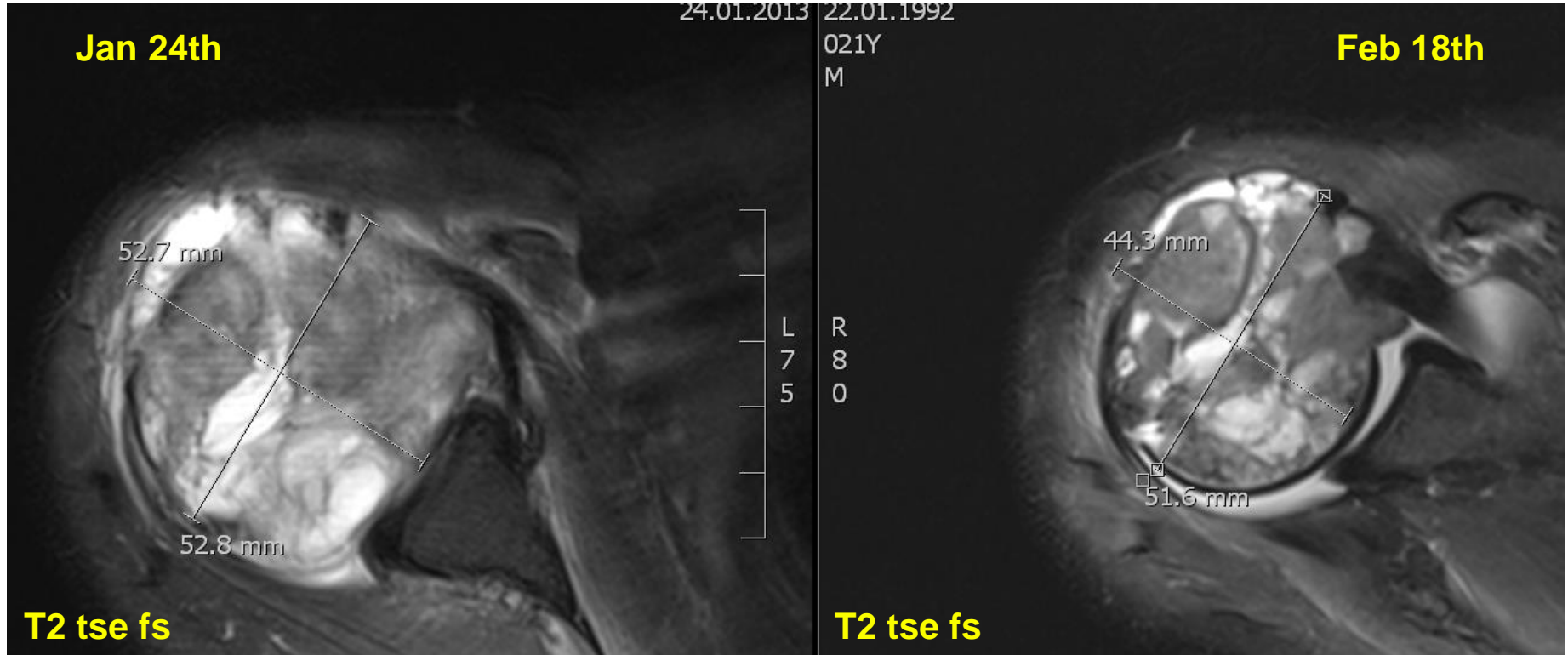
Shoulder; extraarticular; arthrodesis

MRI : Jan 24th vs. Feb 18th, 2013



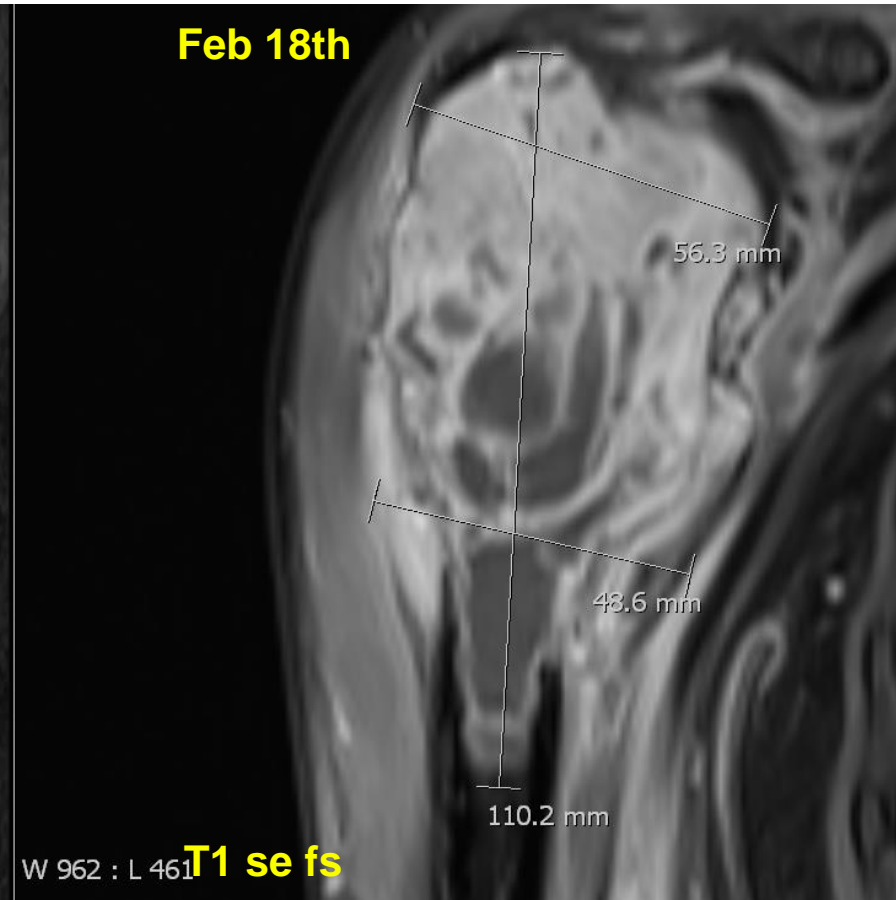
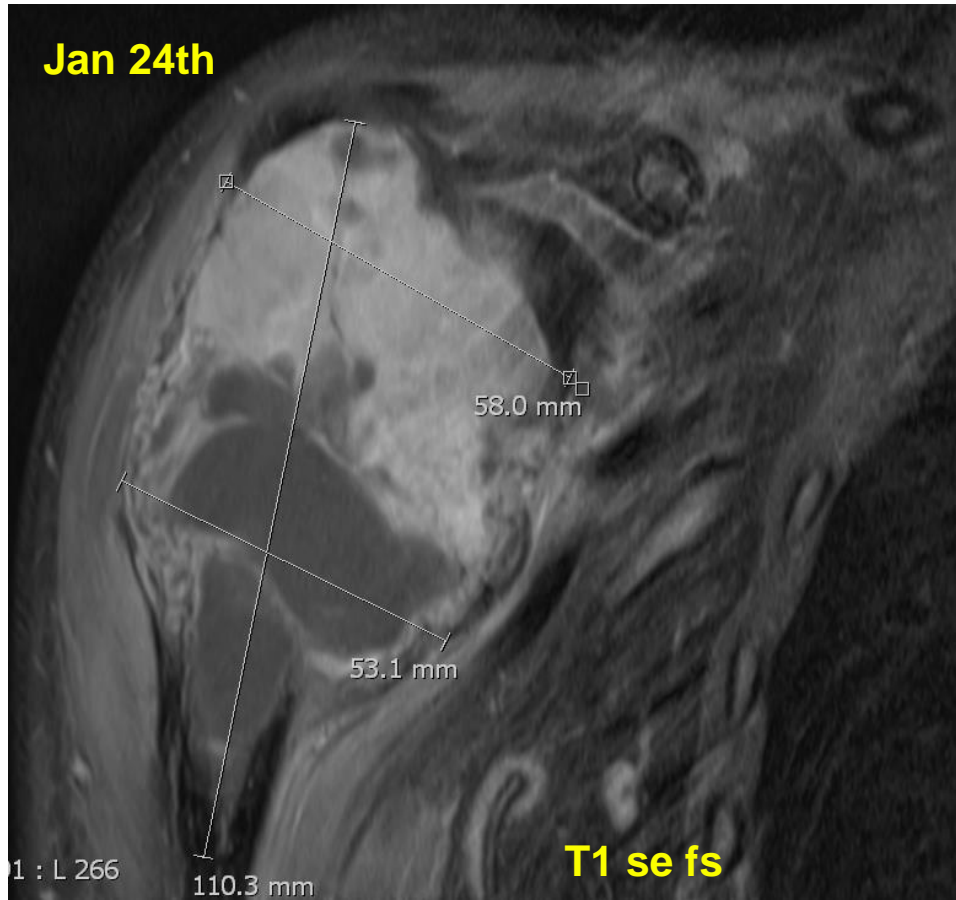
Shoulder; extraarticular; arthrodesis

MRI : Jan 24th vs. Feb 18th, 2013



Shoulder; extraarticular; arthrodesis

MRI : Jan 24th vs. Feb 18th, 2013



Shoulder; extraarticular; arthrodesis

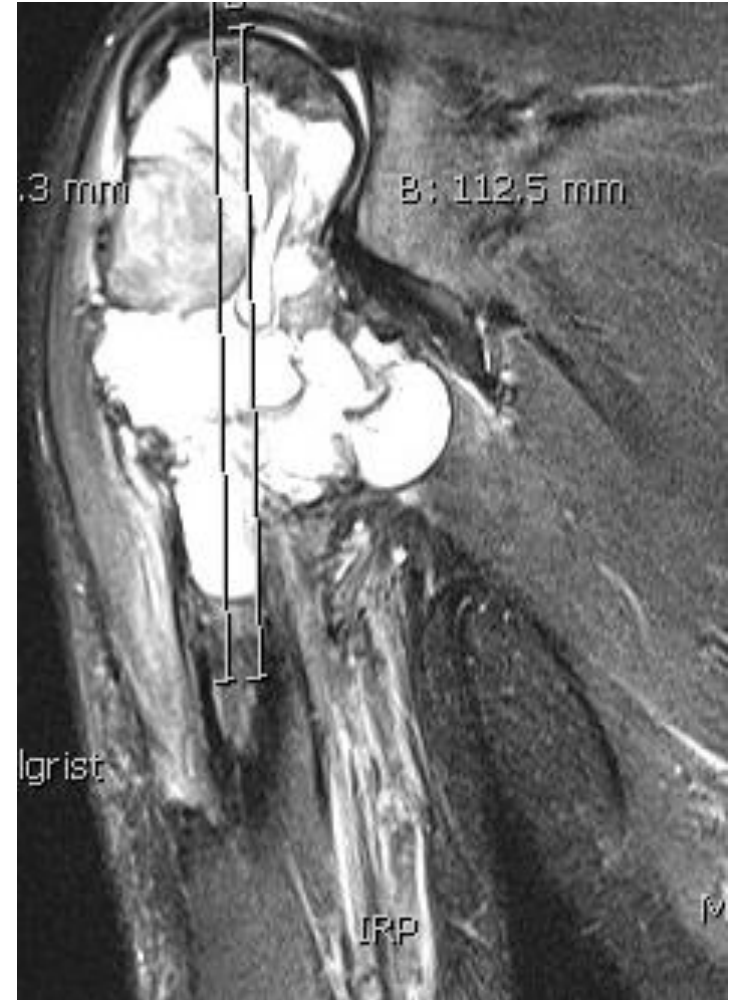
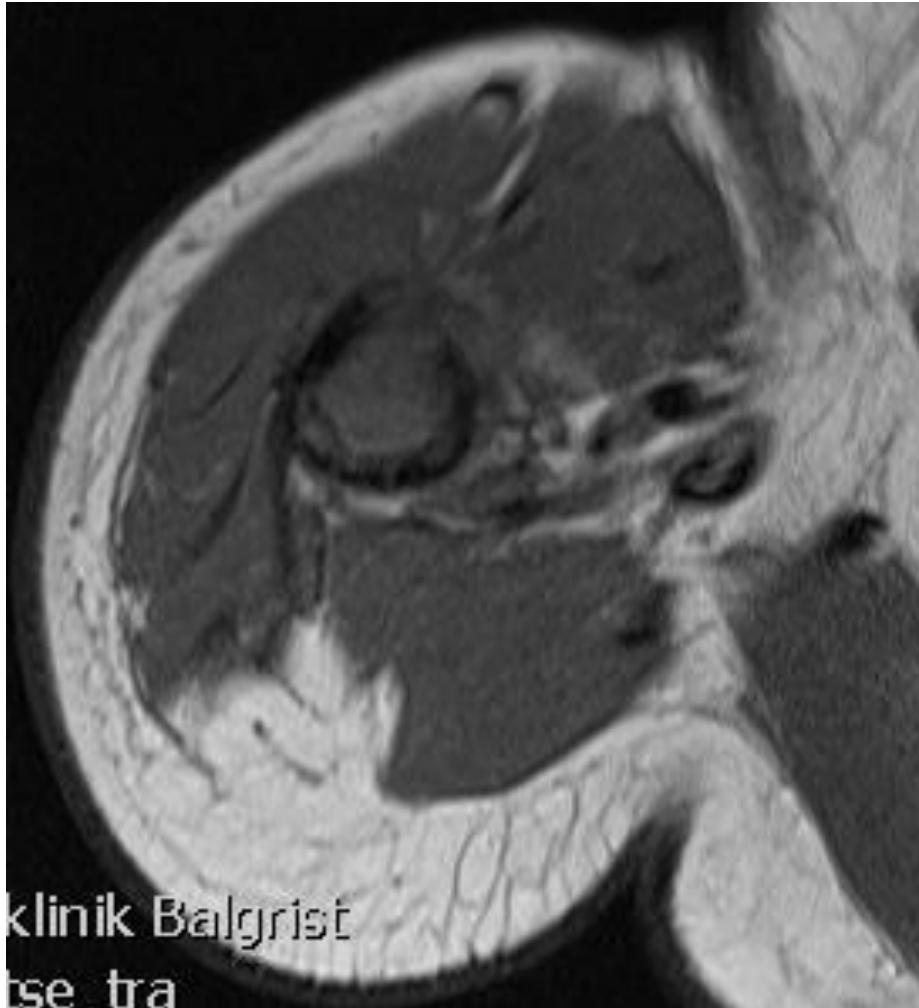Sarcoma- Board: Feb 28th, 2013

Therapeutic decisions:

- **Completion of neoadjuvant chemotherapy**
- **Surgery scheduled for March 19th, 2013**

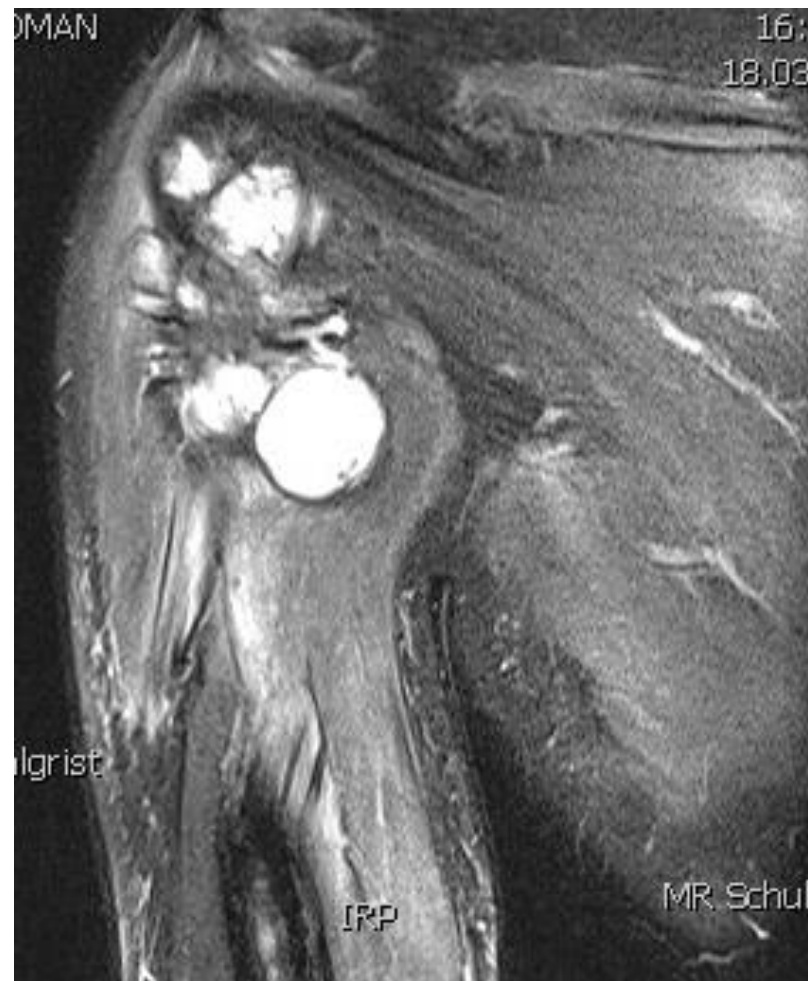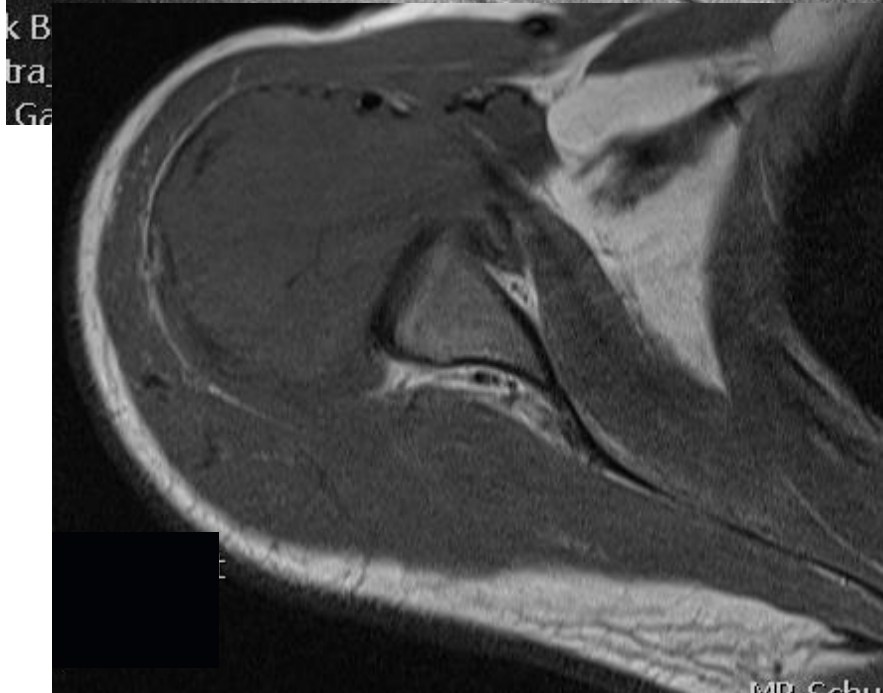
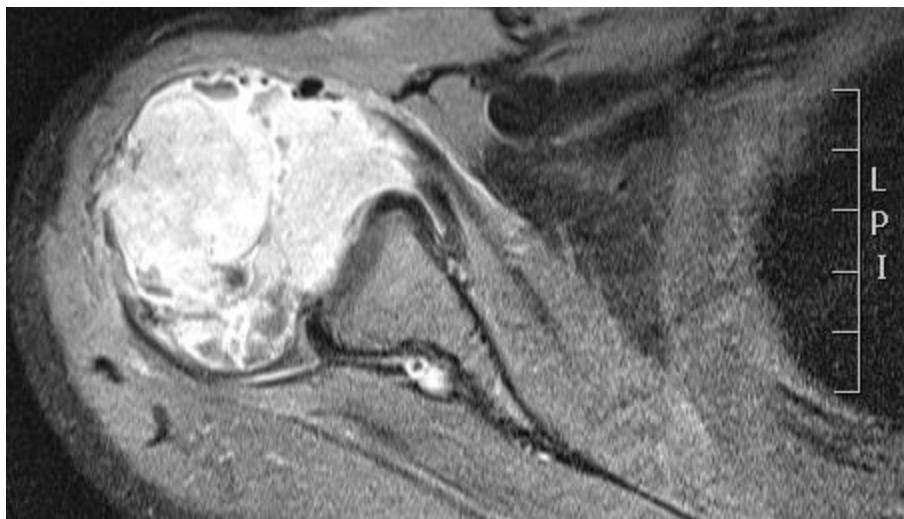
Shoulder; extraarticular; arthrodesis

MRI: March 18th, 2013



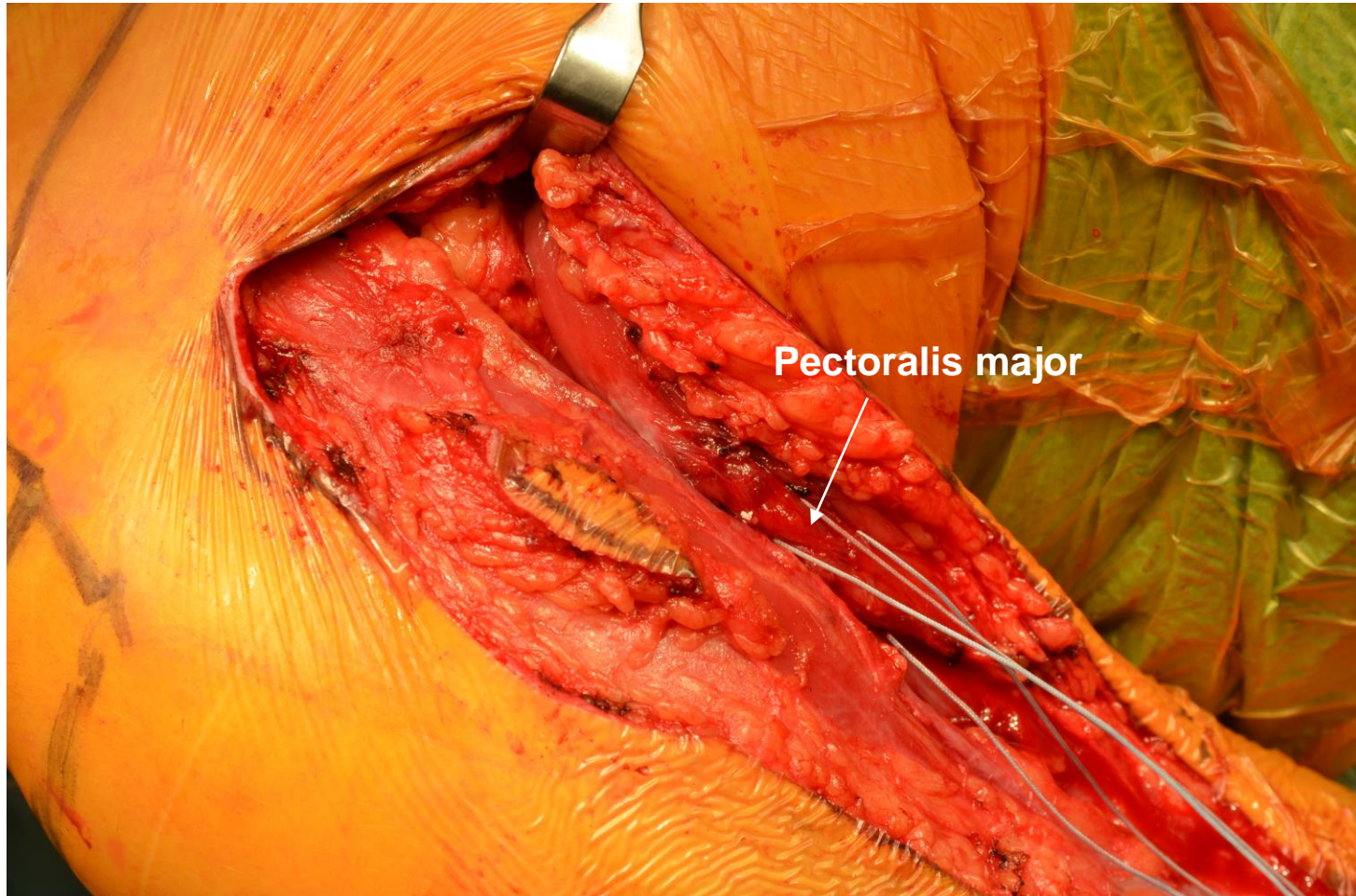
Shoulder; extraarticular; arthrodesis

MRI: March 18th, 2013



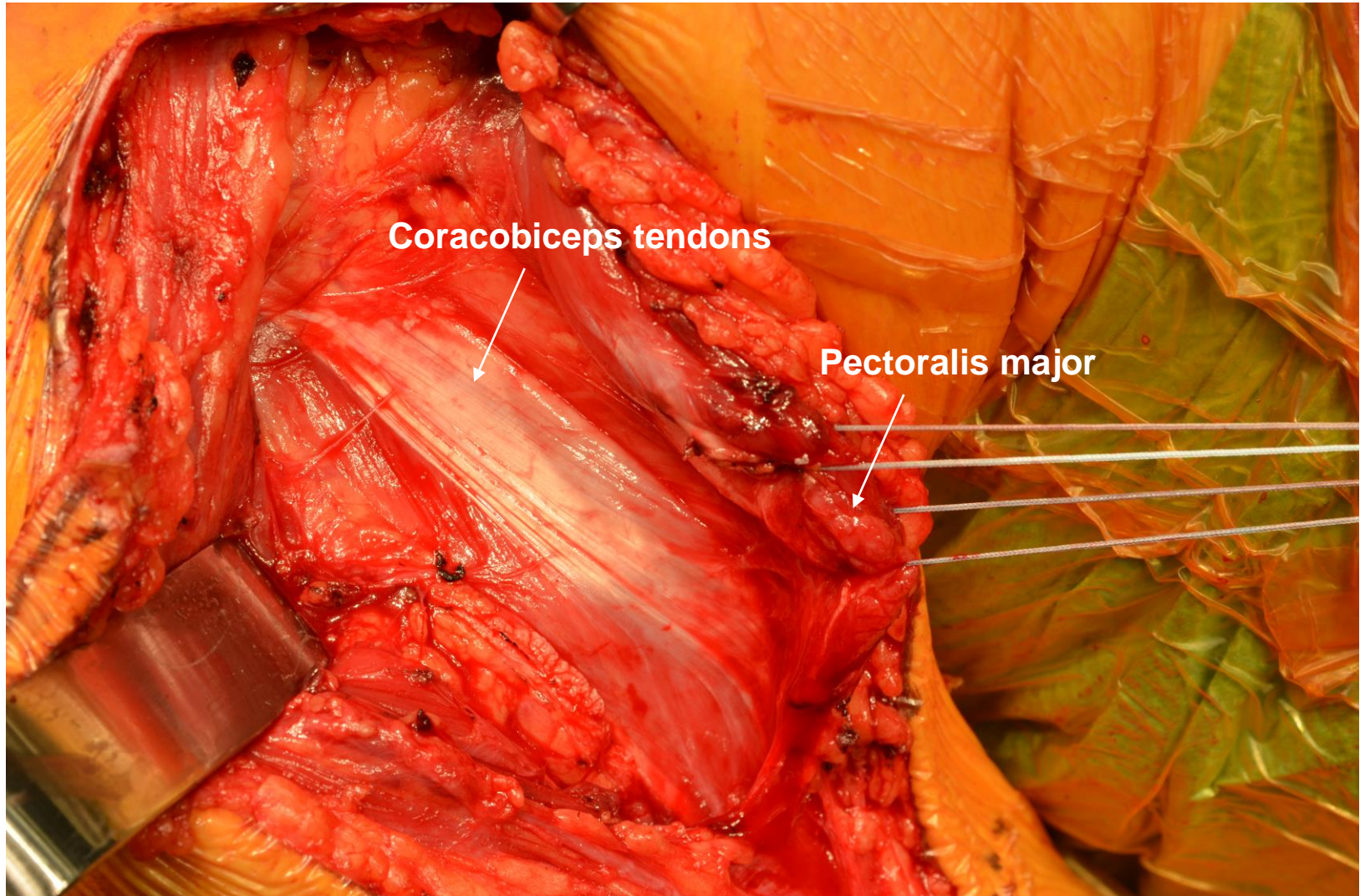
Shoulder; extraarticular; arthrodesis

Surgery: March 19th, 2013



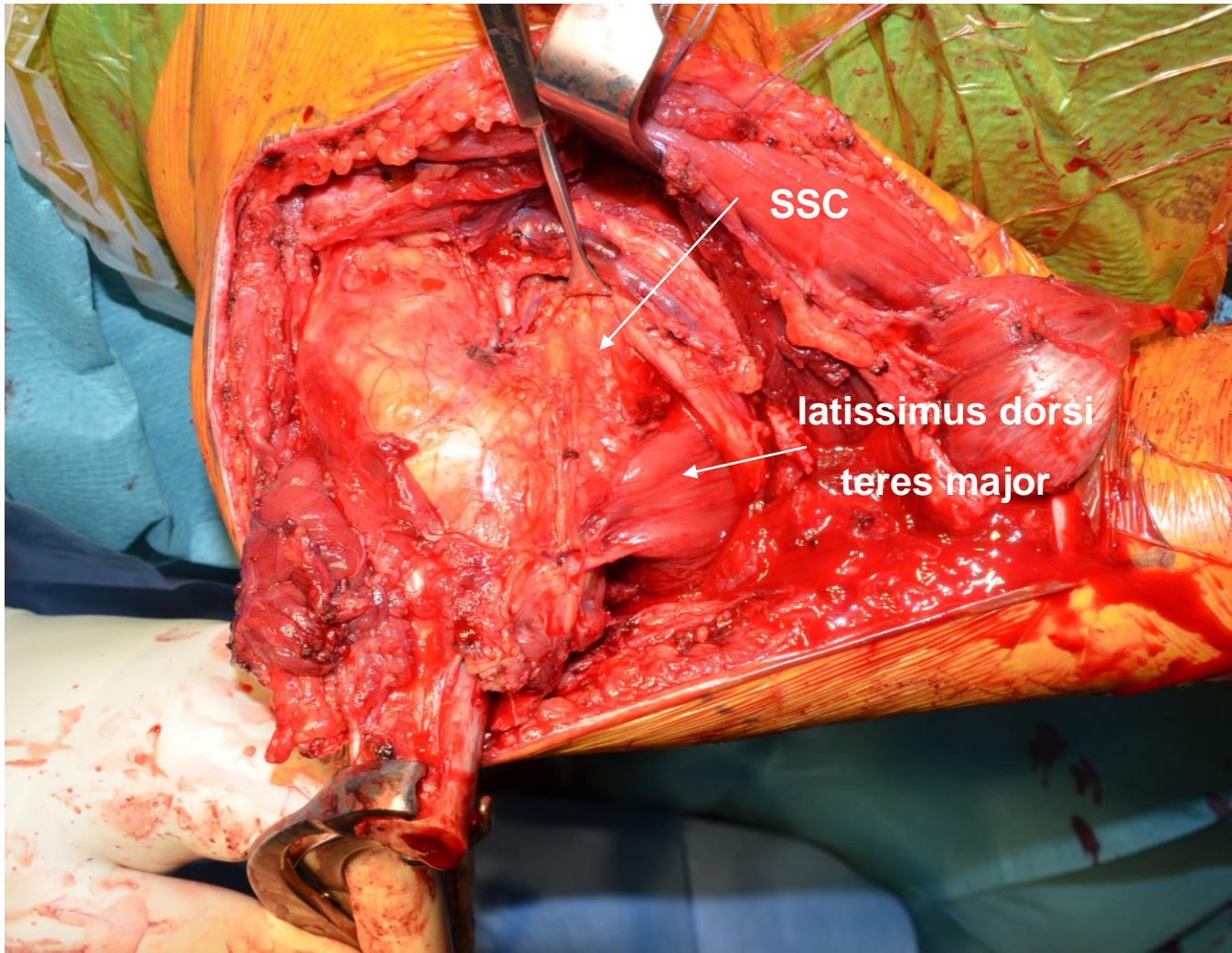
Shoulder; extraarticular; arthrodesis

Surgery: March 19th, 2013



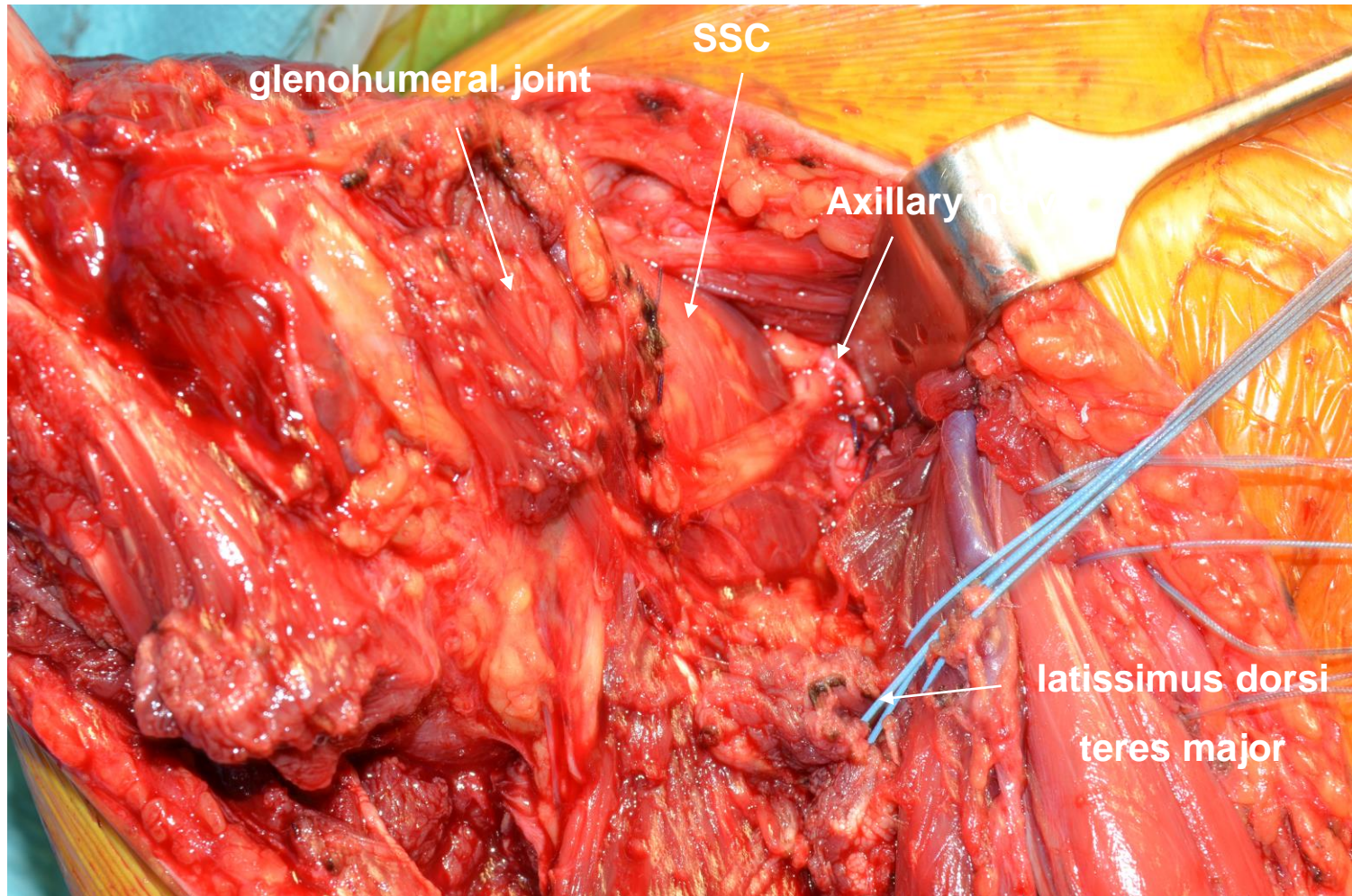
Shoulder; extraarticular; arthrodesis

Surgery: March 19th, 2013



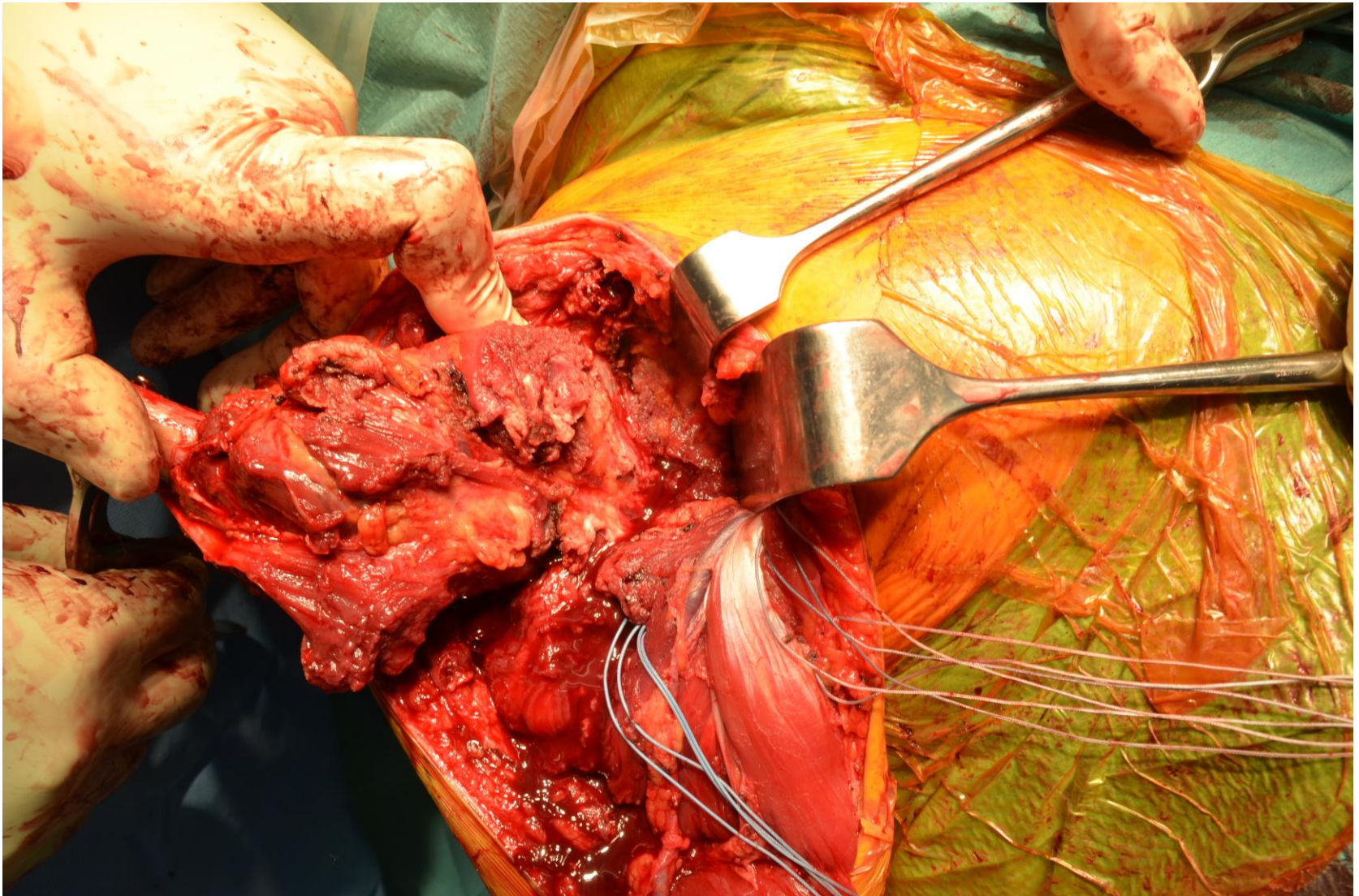
Shoulder; extraarticular; arthrodesis

Surgery: March 19th, 2013



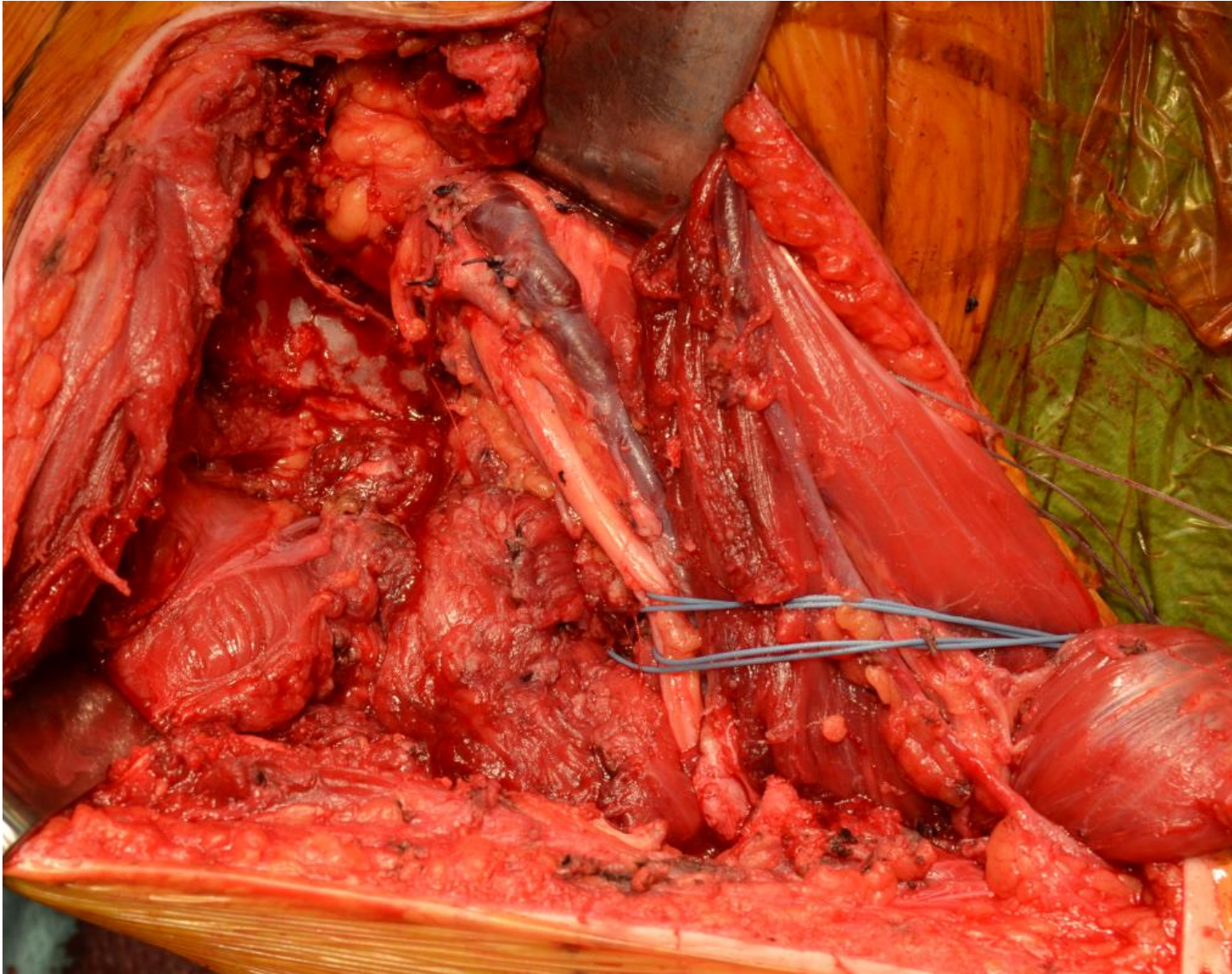
Shoulder; extraarticular; arthrodesis

Surgery: March 19th, 2013



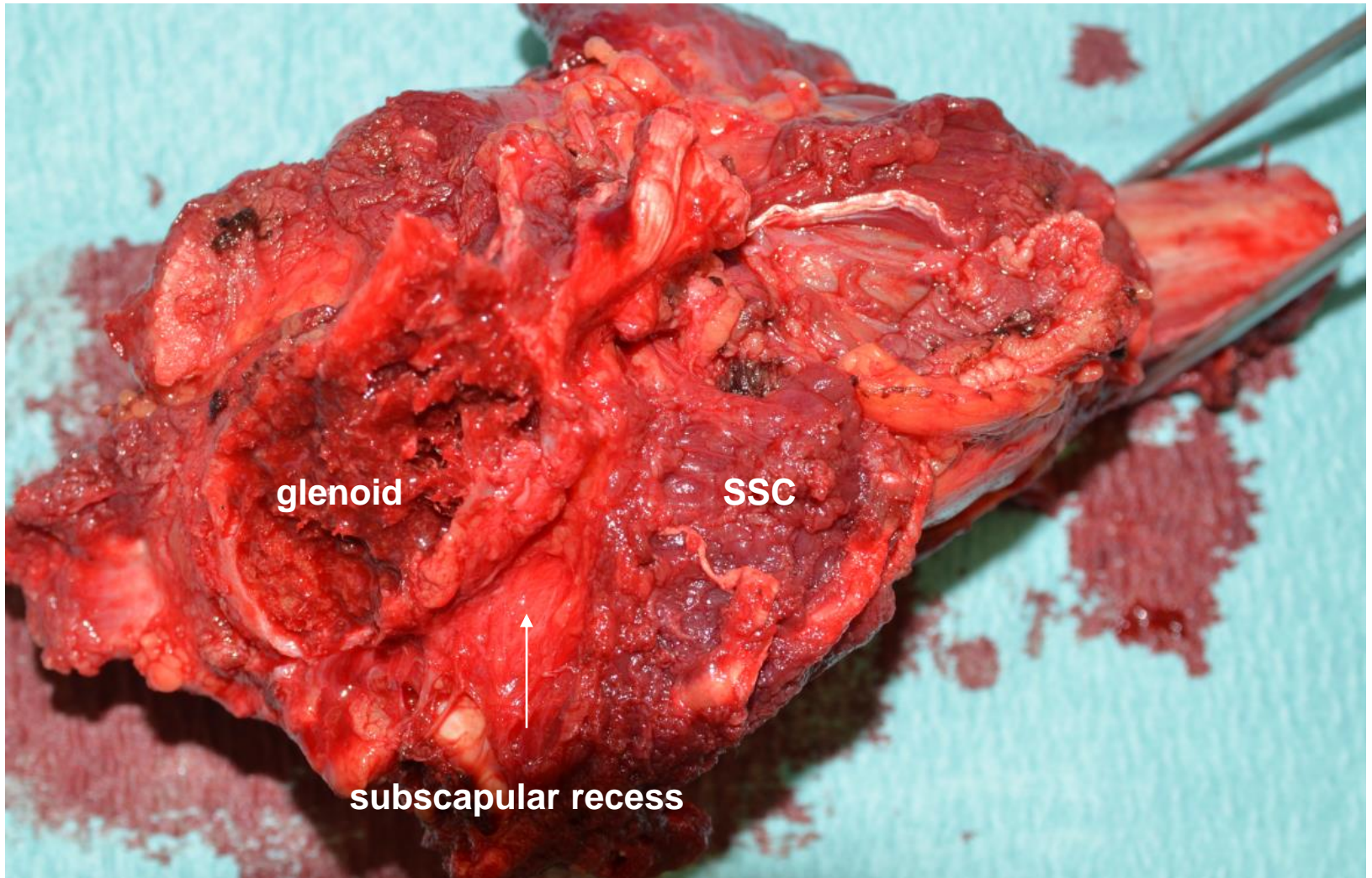
Shoulder; extraarticular; arthrodesis

Surgery: March 19th, 2013



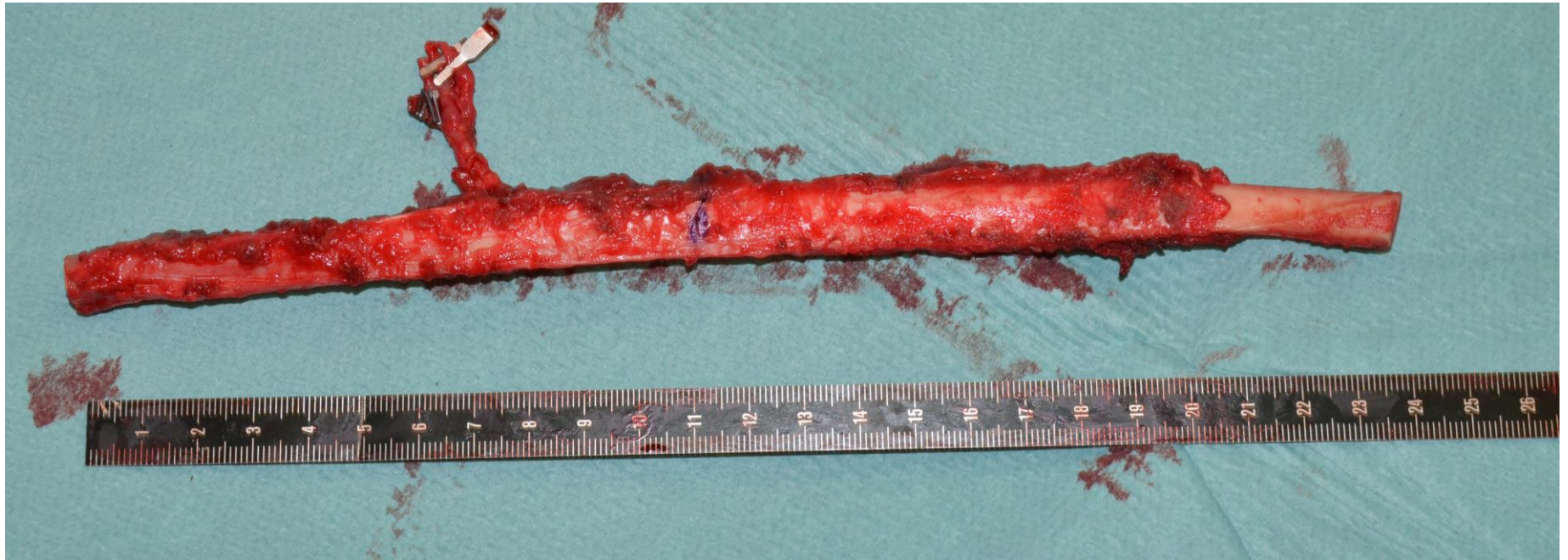Shoulder; extraarticular; arthrodesis

Surgery: March 19th, 2013



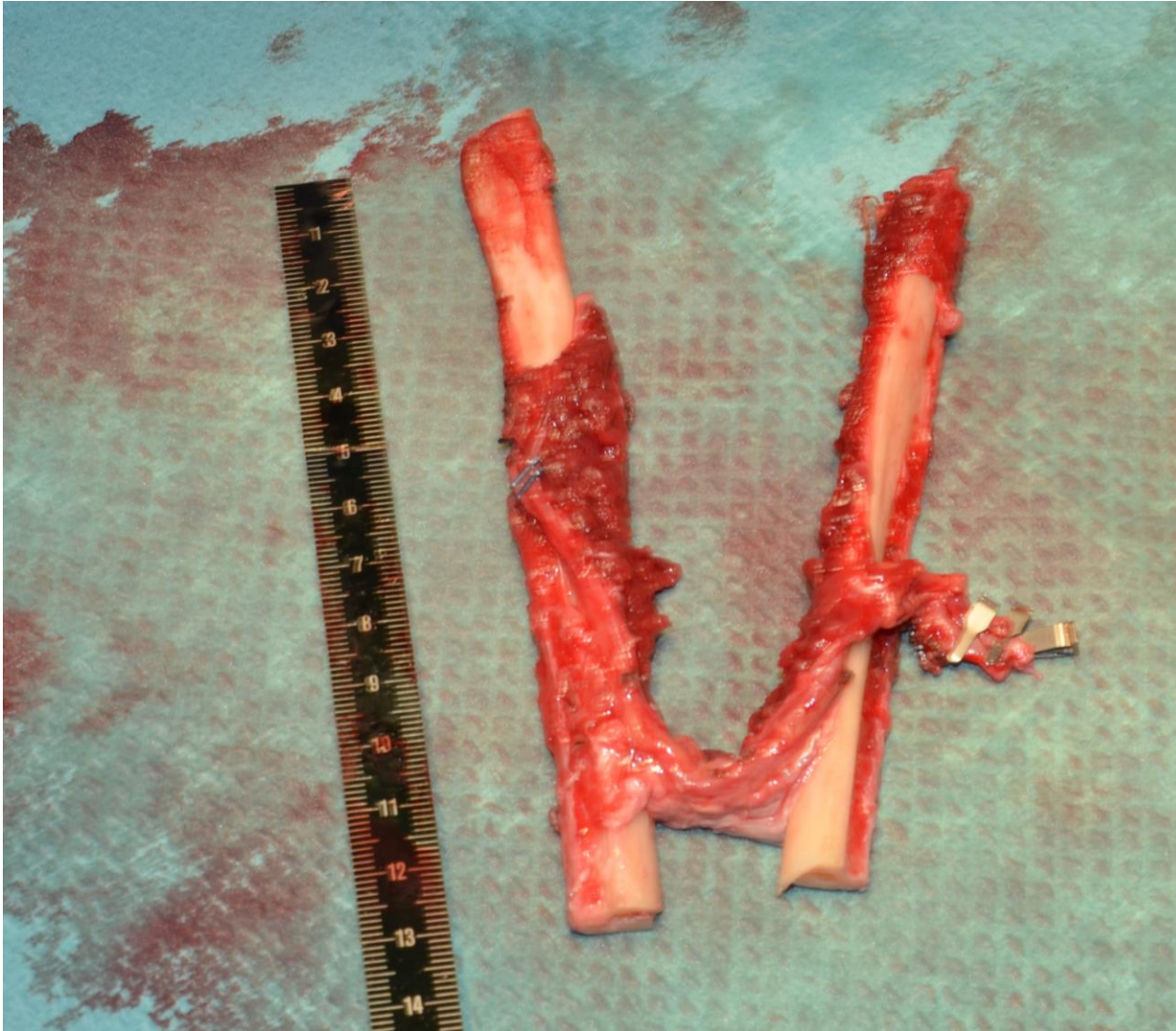
Shoulder; extraarticular; arthrodesis

Surgery: March 19th, 2013



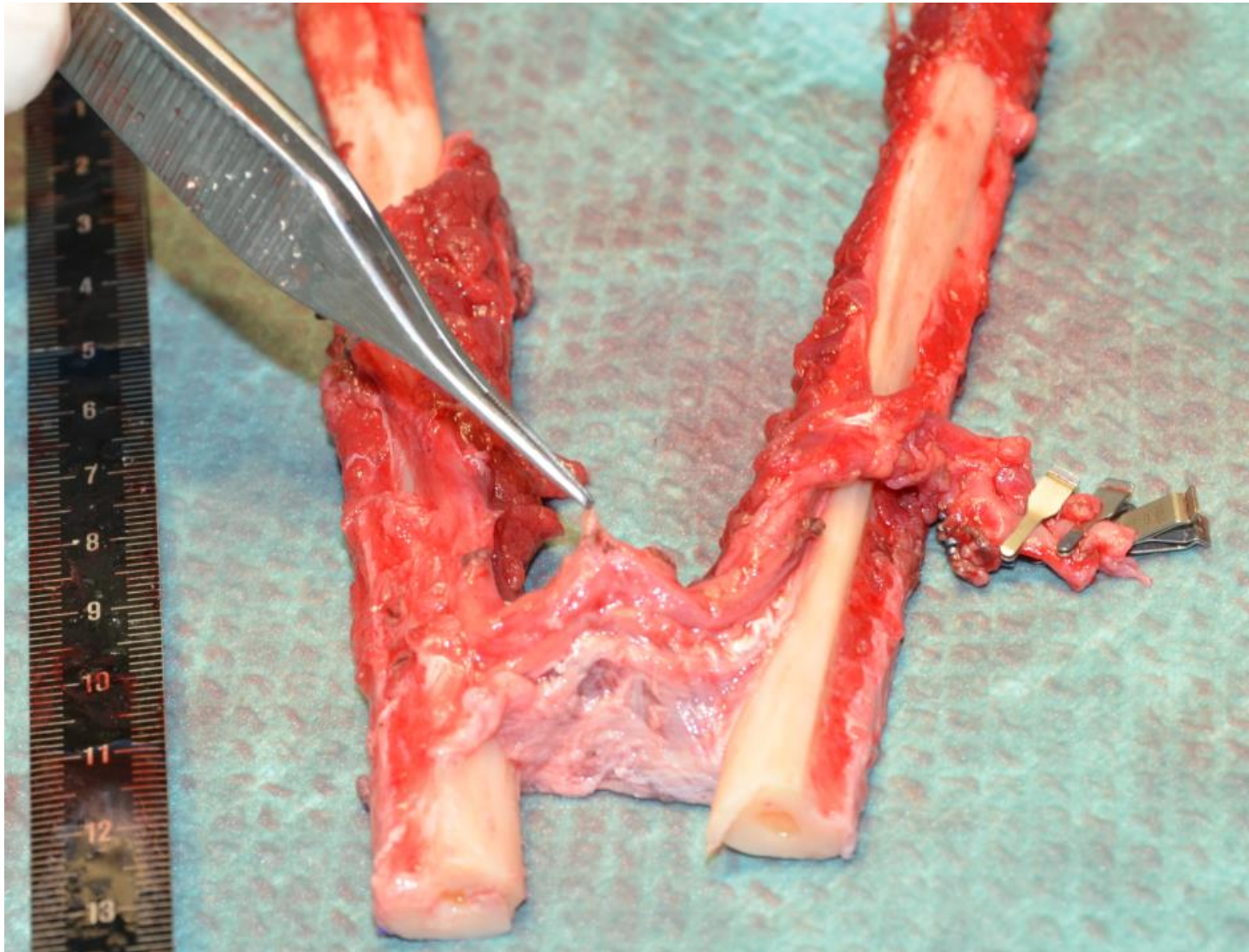
Shoulder; extraarticular; arthrodesis

Surgery: March 19th, 2013



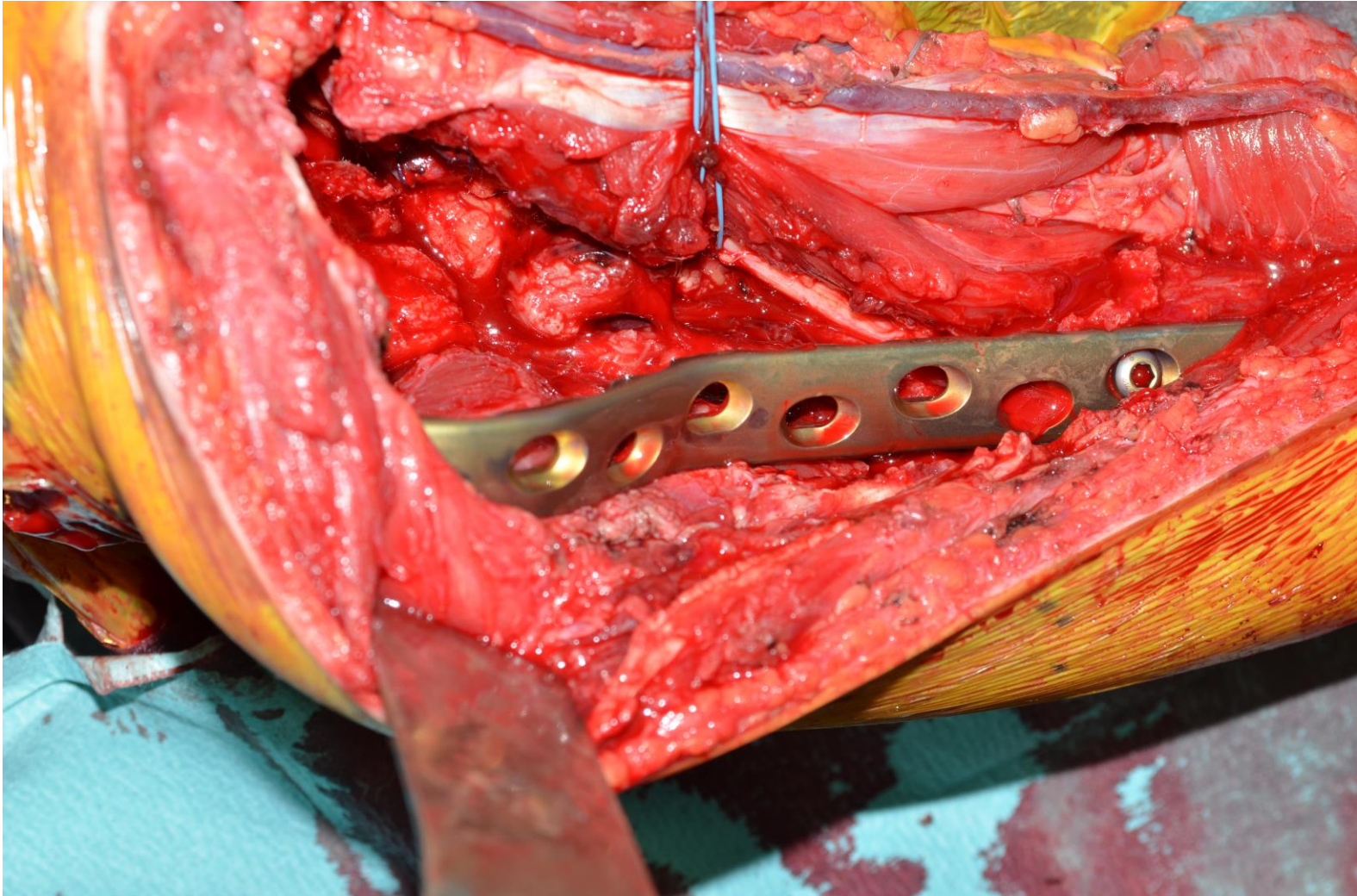
Shoulder; extraarticular; arthrodesis

Surgery: March 19th, 2013



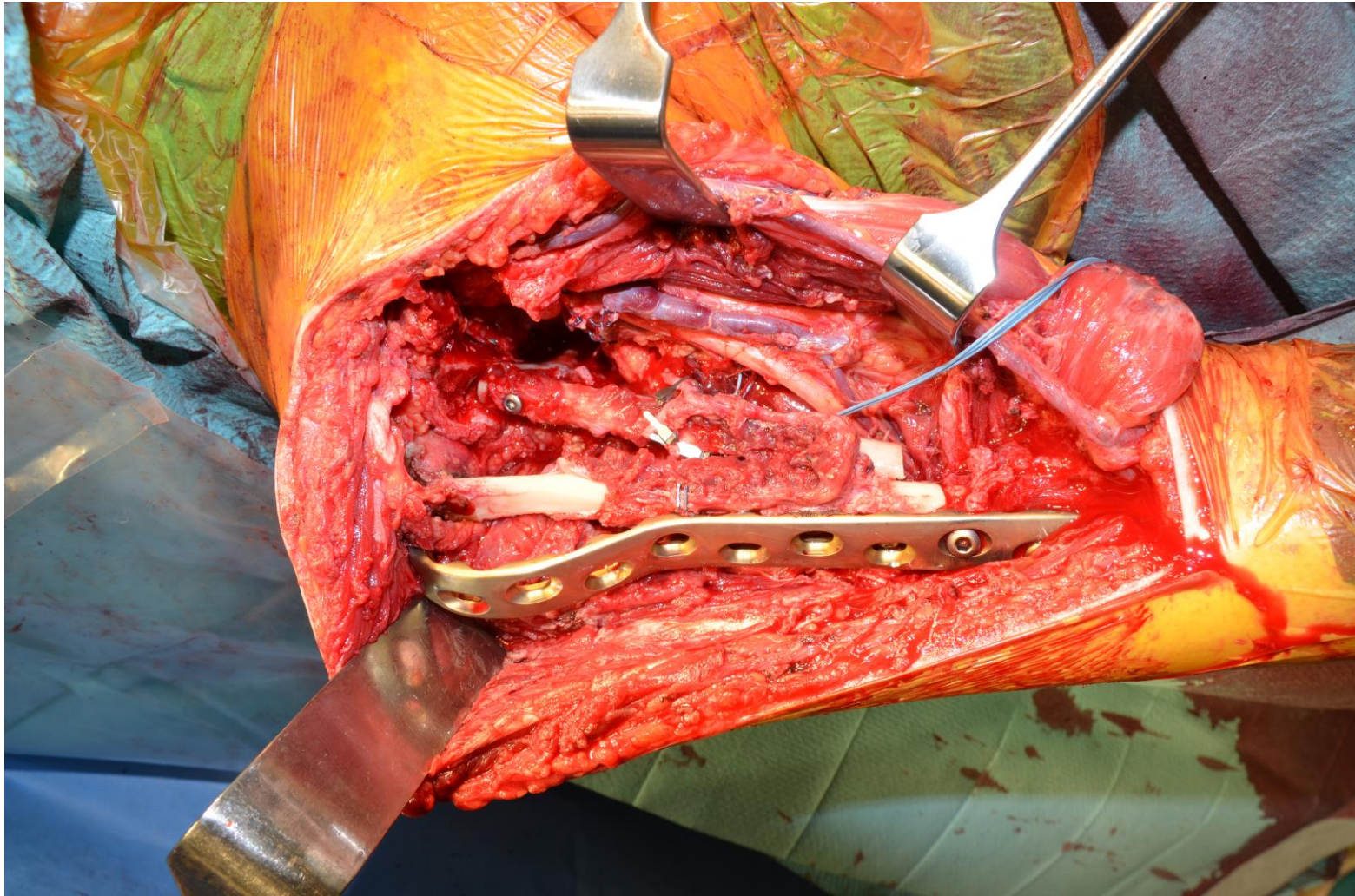
Shoulder; extraarticular; arthrodesis

Surgery: March 19th, 2013



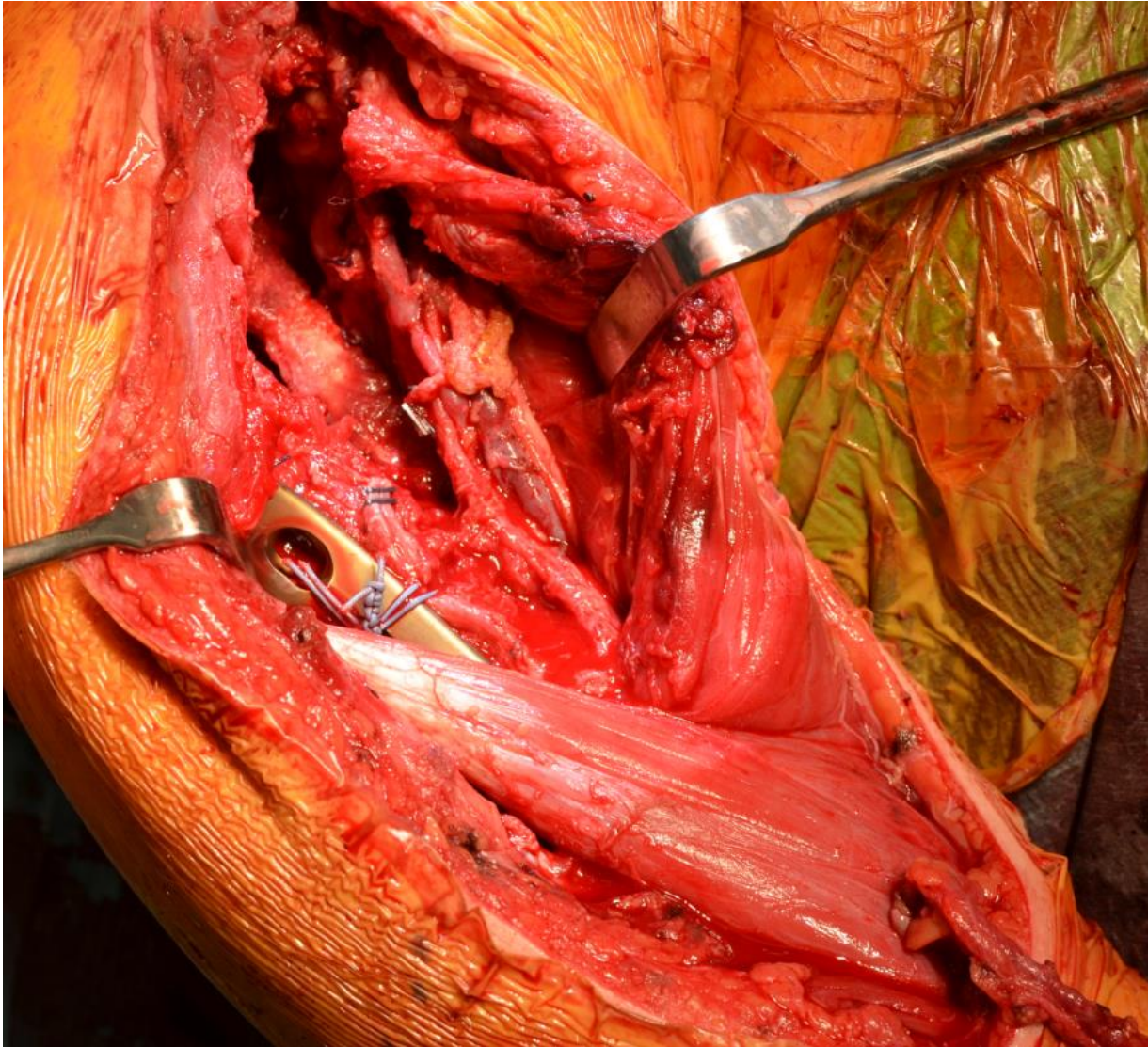
Shoulder; extraarticular; arthrodesis

Surgery: March 19th, 2013



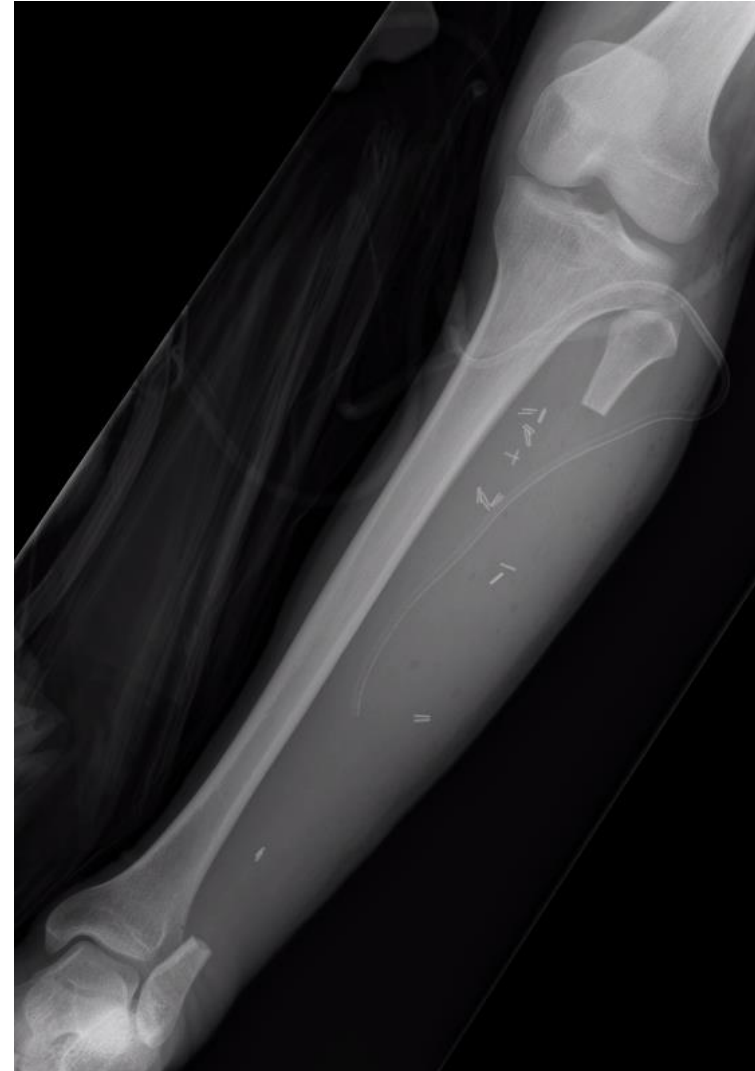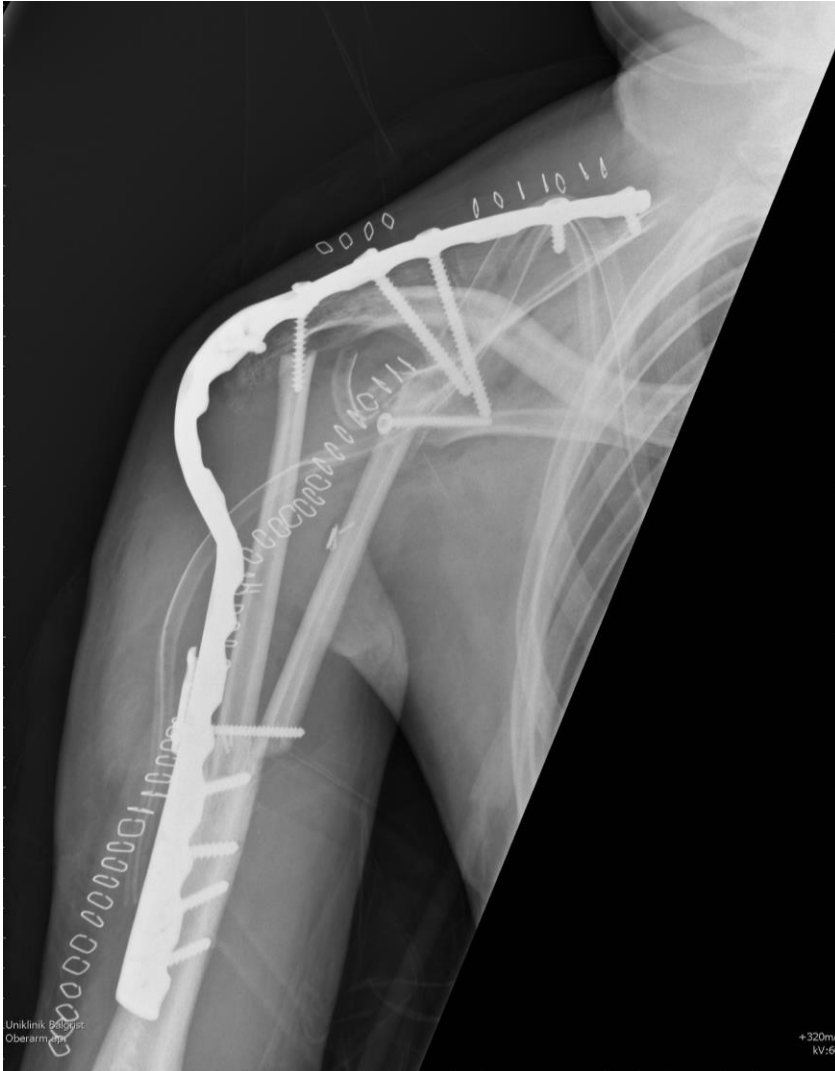Shoulder; extraarticular; arthrodesis

Surgery: March 19th, 2013



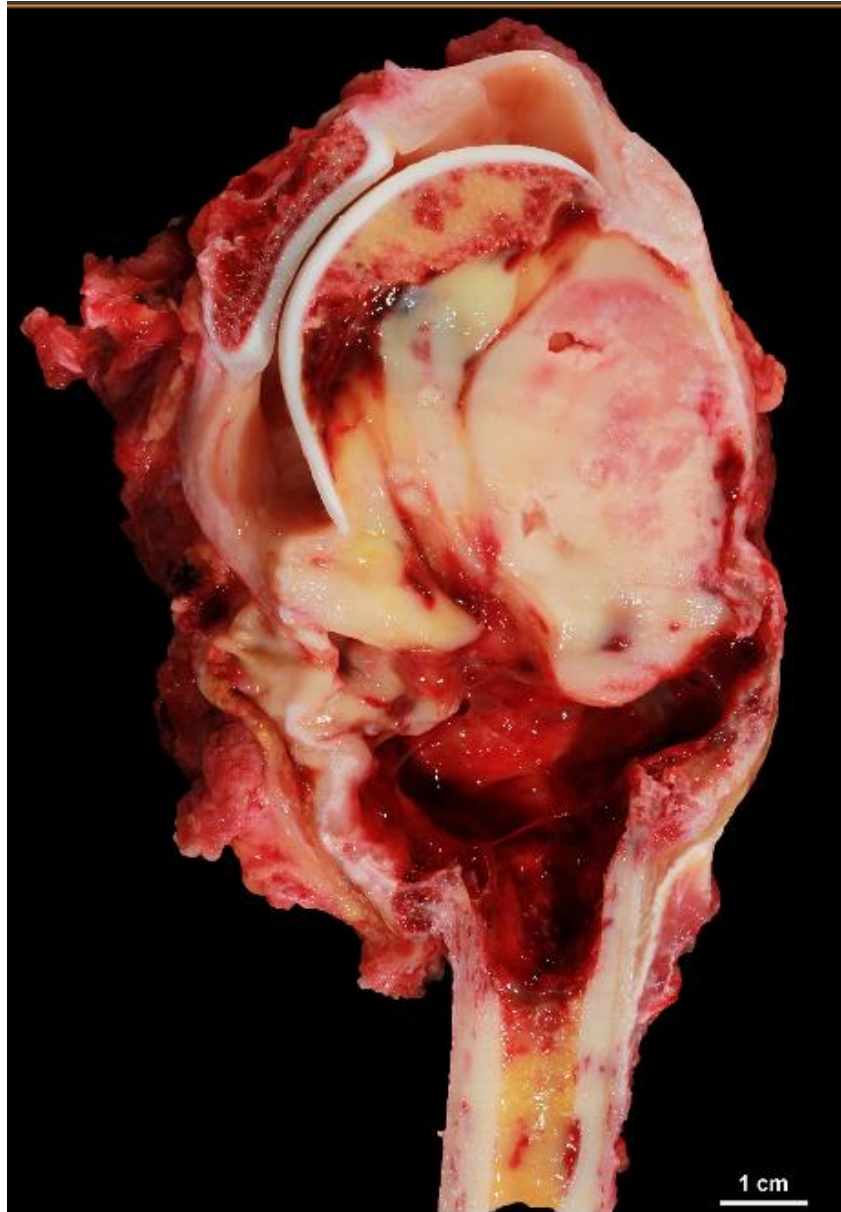
Shoulder; extraarticular; arthrodesis

Postop X-Ray: March 19th, 2013



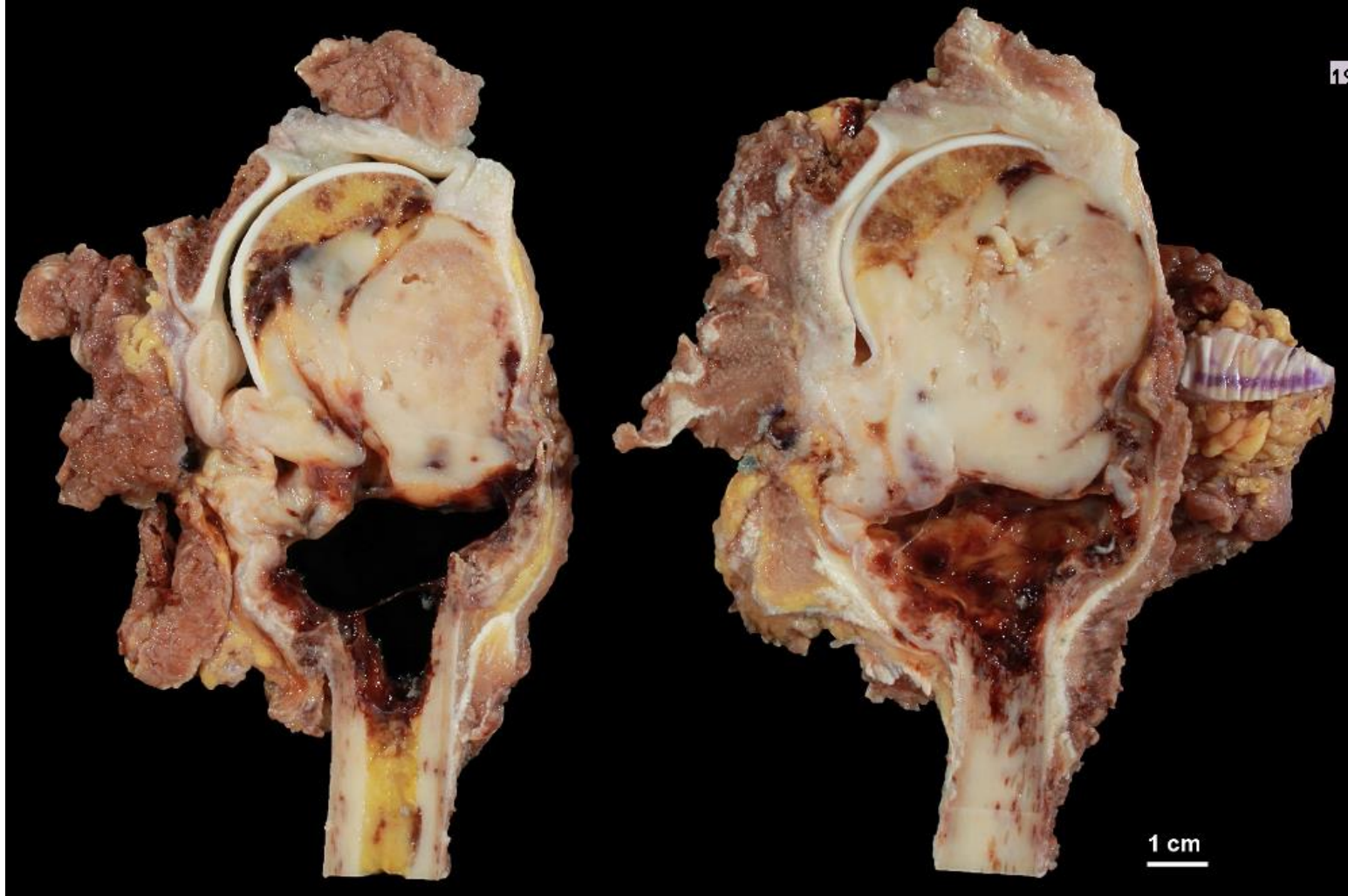
Shoulder; extraarticular; arthrodesis

Result: Surgery: March 19th, 2013




Shoulder; extraarticular; arthrodesis

Result: Surgery: March 19th, 2013



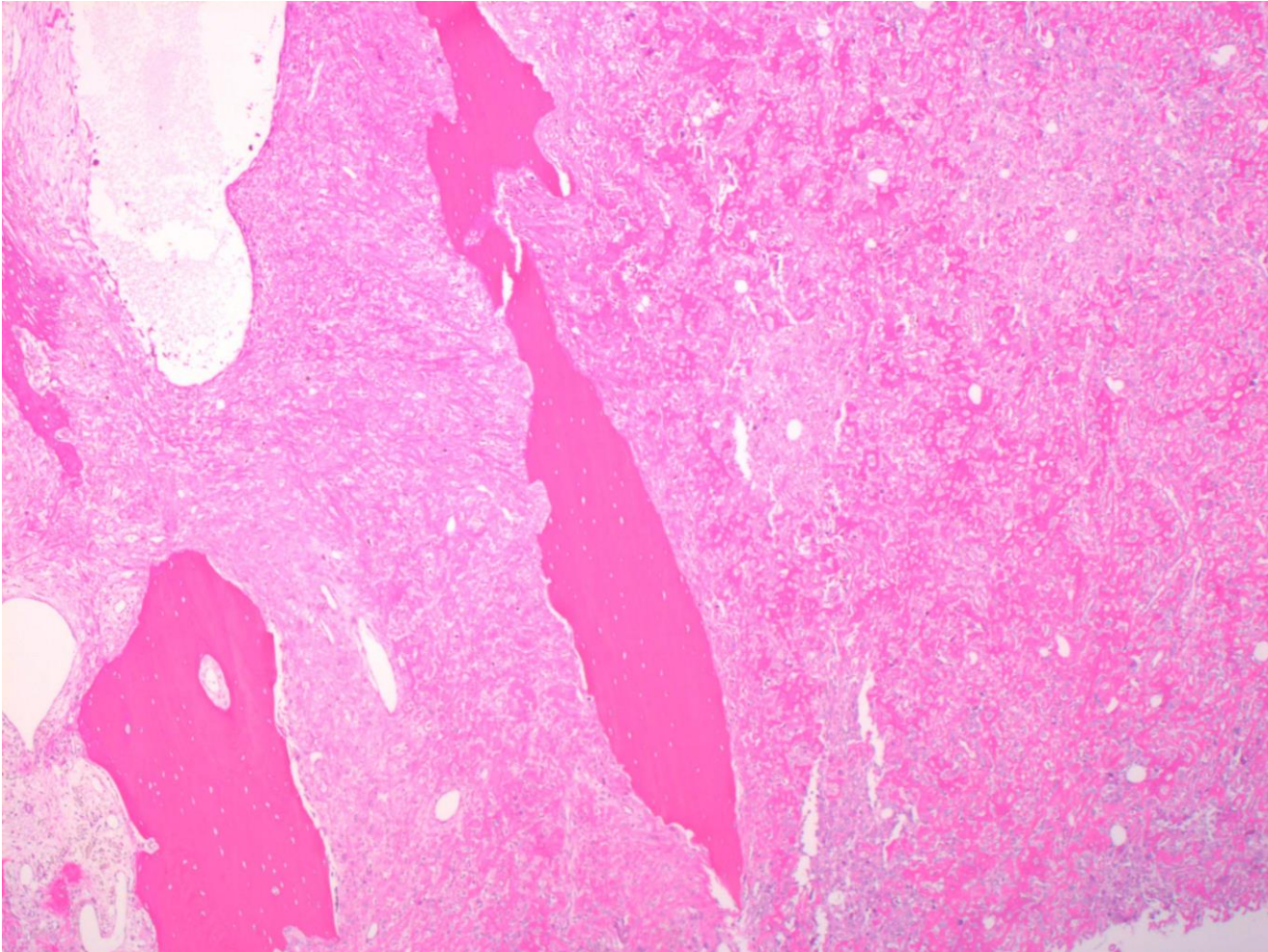
Shoulder; extraarticular; arthrodesis

Result: Surgery: March 19th, 2013



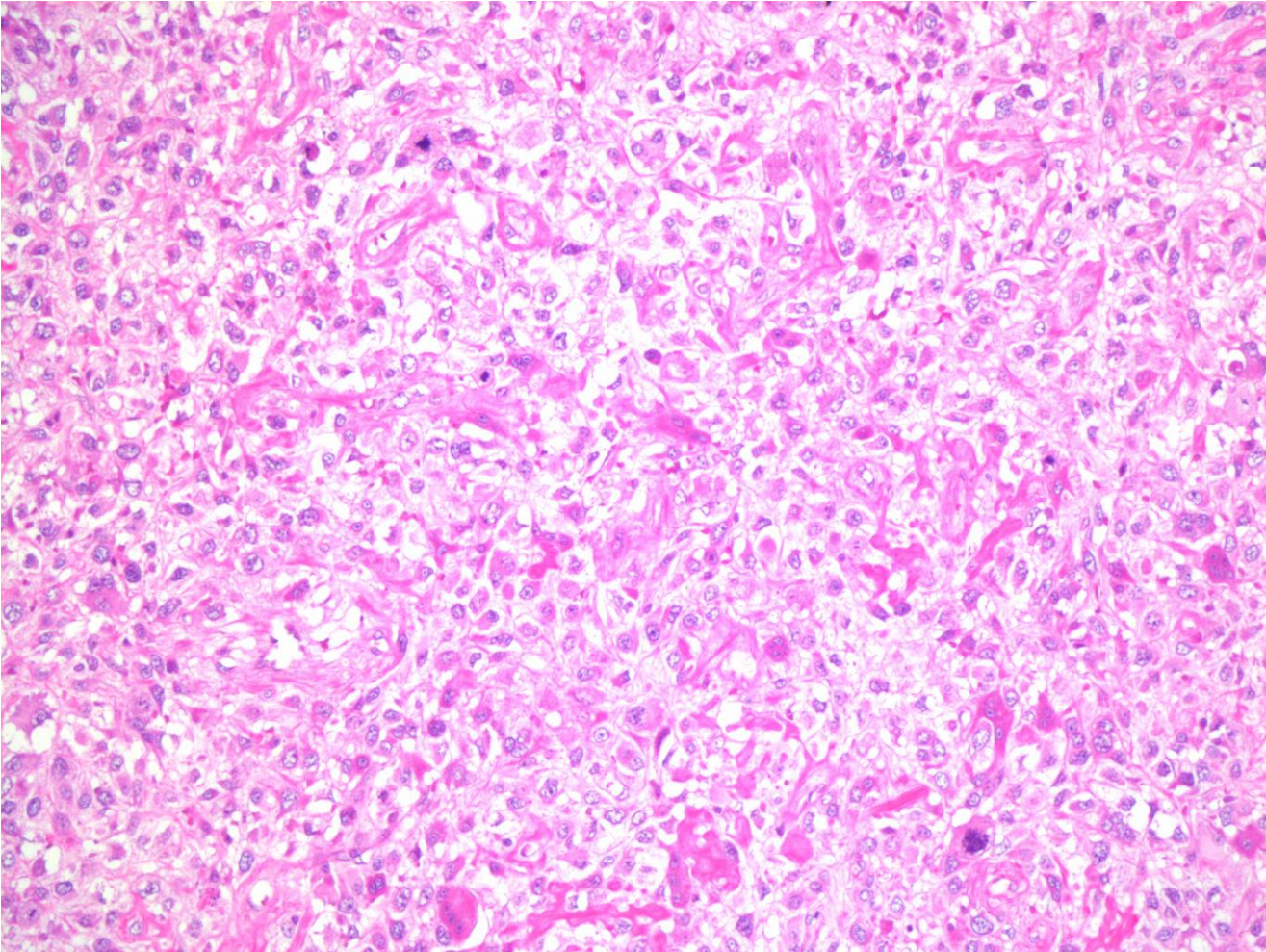
Shoulder; extraarticular; arthrodesis

Result: Surgery: March 19th, 2013



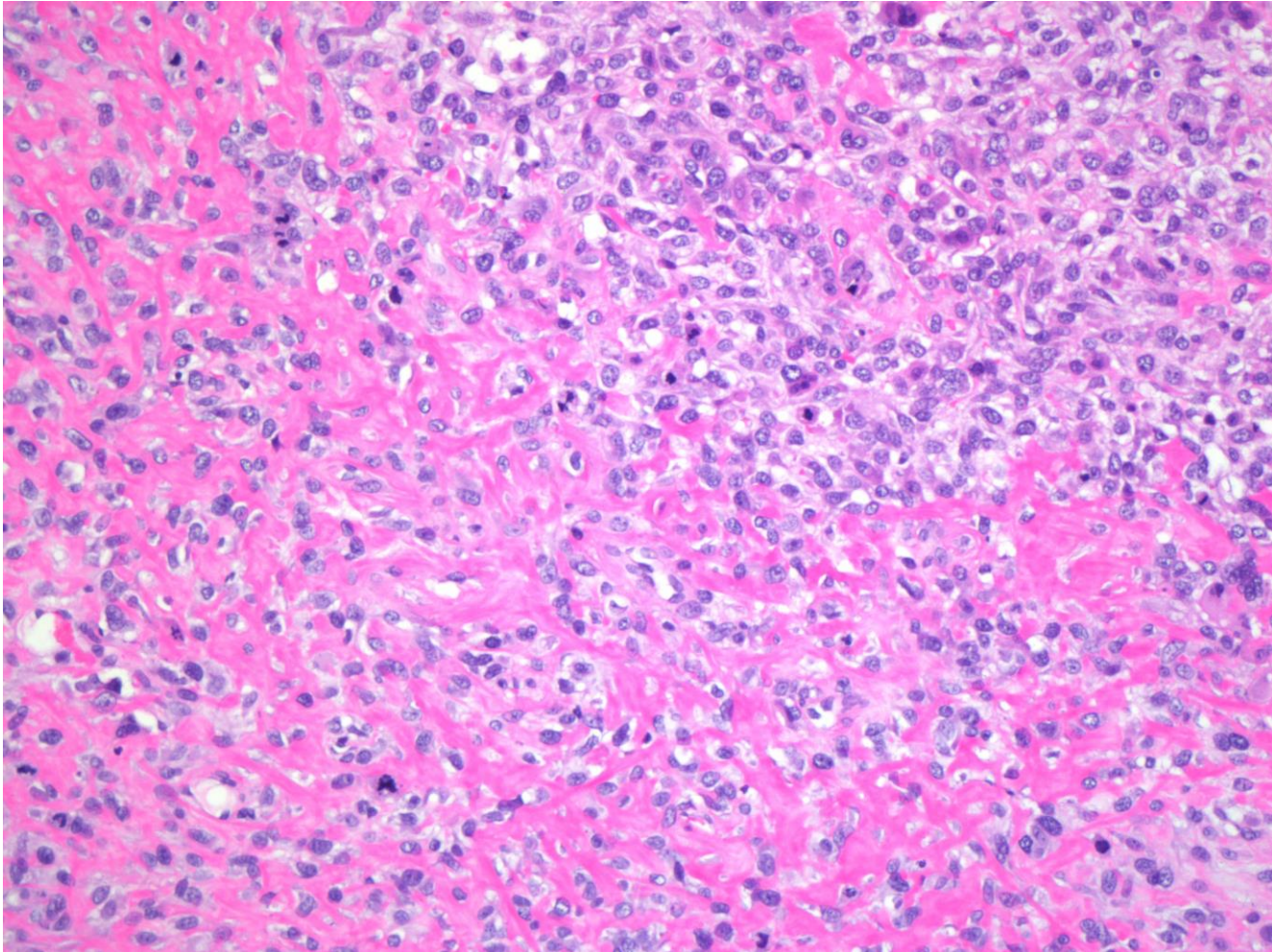
Shoulder; extraarticular; arthrodesis

Result: Surgery: March 19th, 2013



Shoulder; extraarticular; arthrodesis

Result: Surgery: March 19th, 2013



Shoulder; extraarticular; arthrodesis

Result: Surgery: March 19th, 2013

Definitiver Bericht (inkl. Beurteilung des ossären Resektatrandes)

Diagnose

Proximales Humerusteilresektat von rechts: Intraossäres Osteosarkom high grade der Metaphyse bei Status nach neoadjuvanter Chemotherapie. 60-70% vitaler Tumoranteil (Grad V nach Salzer-Kuntschik; Non-Responder). Maximaler Tumordurchmesser 8,5 cm. Durchbruch durch den Gelenkknorpel. Durchbruch in das angrenzende Weichteilgewebe: Am medialen, gelenksnahen Präparatrand reicht der Tumor über eine Strecke von 2 mm unmittelbar an den zirkumferentiellen Präparatrand heran. Kein Tumornachweis an den übrigen zirkumferentiellen Präparaträndern und an den intraossären Resektaträndern: Mindestabstand nach dorsal 2 mm, nach lateral 4 mm und nach ventral 7 mm. Tumorfreier Stichkanal. Vgl. Kommentar.


Kommentar

Die Schnittpräparate zum ossären Resektatrand konnten nach Entkalkung nun ebenfalls untersucht werden, es lässt sich kein Tumor in den ossären (intraossär Humerus und Skapula) nachweisen.

Shoulder; extraarticular; arthrodesis

21 yo farmer

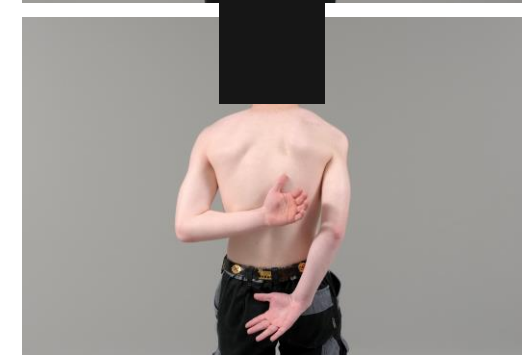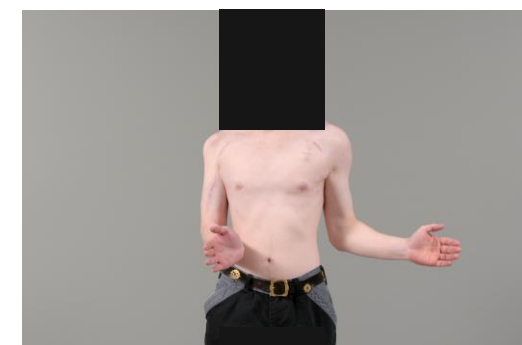
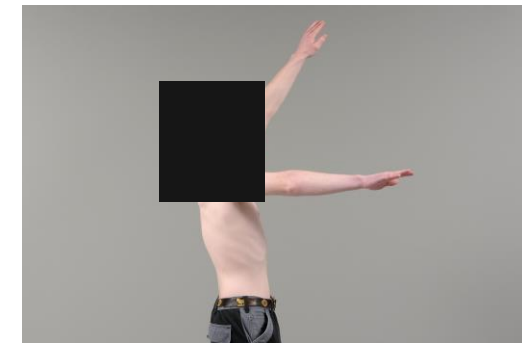
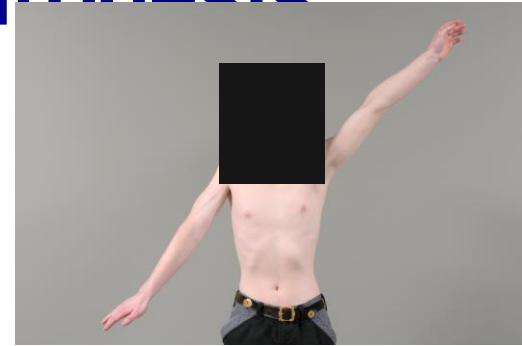
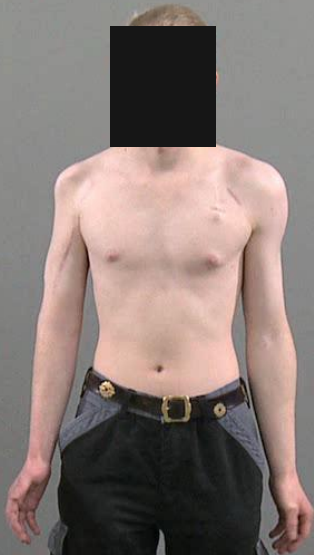
25. September 2013



Shoulder; extraarticular; arthrodesis

21 yo farmer

05 February 2014



Shoulder; extraarticular; arthrodesis

OP 26. Februar 2014



Shoulder; extraarticular; arthrodesis

28 February 2014

Tragic work accident

in the field:

Patient gets squeezed
between tractor and crane

