

# shoulder; extra-articular; arthrodesis

♂ 21 yo

Patient outside

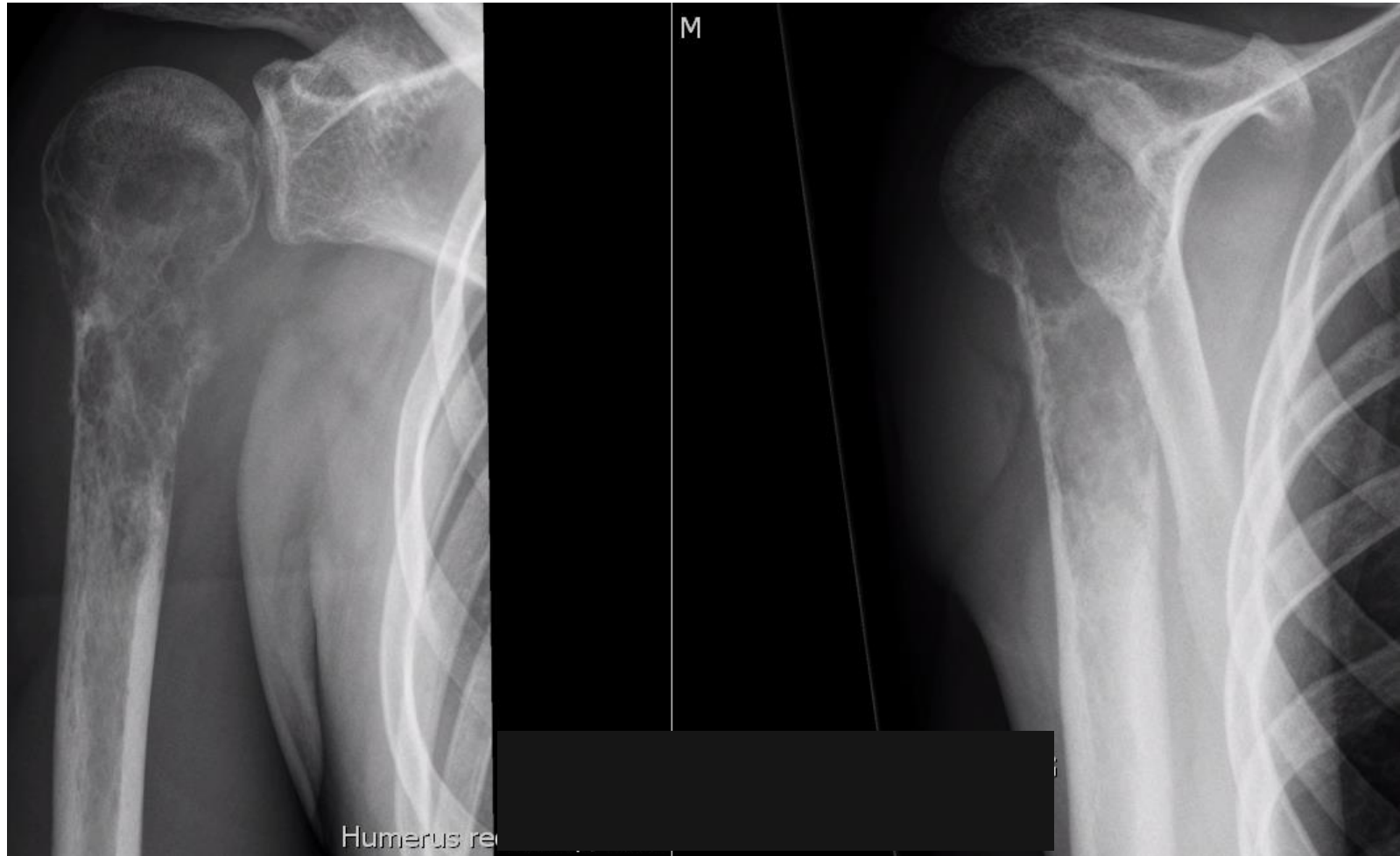
## PMH:

### High-grade osteosarcoma of right humerus

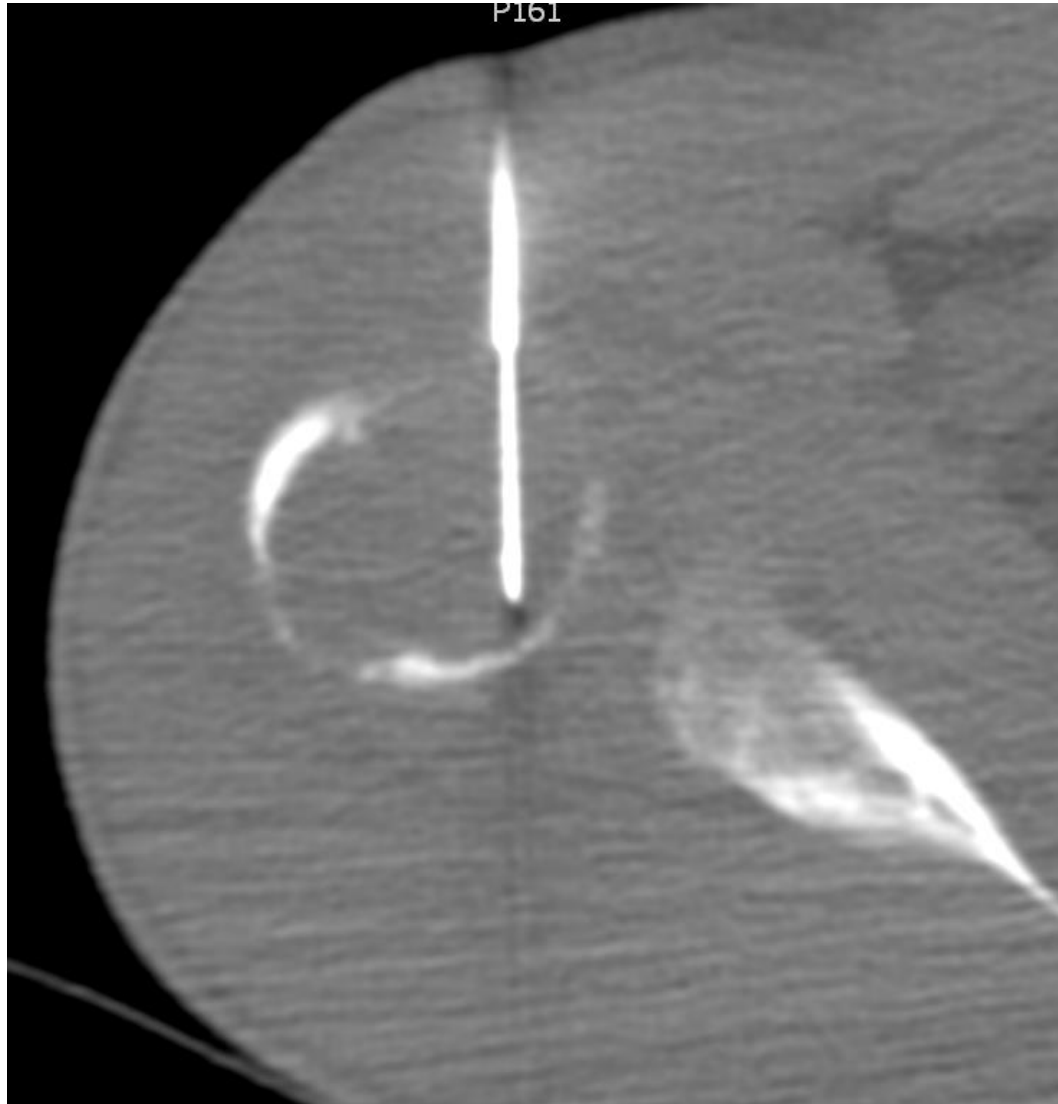
- 1st imaging in St. Gallen in dec ´12 (MRI,CT,RX on dec 27th, 2012): no signs for locoregional or distant Mx
- CT-guided biopsy on dec 28th, 2012: high-grade osteosarcoma
- s/p sperm-cryoconservation on Jan 3rd, 2013
- s/p port-a-cath on Jan 9th, 2013
- Jan 10th, 2013: start of chemotherapy EURAMOS (AP)
- Feb 15th 2013: start of 2nd cycle (MAP)

# shoulder; extra-articular; arthrodesis

Rx right shoulder: Dec 28th, 2012



**shoulder; extra-articular; arthrodesis  
Biopsy (outside): Dec 28th, 2012**

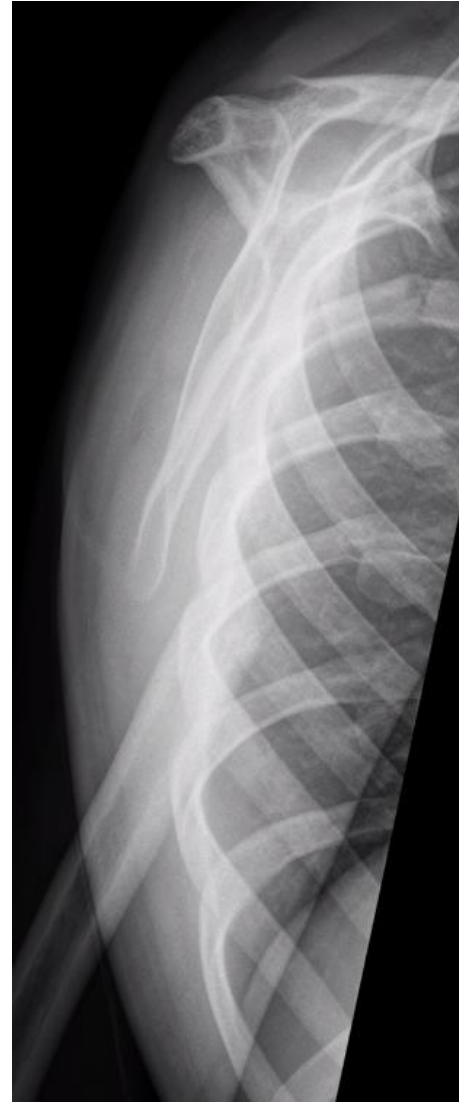
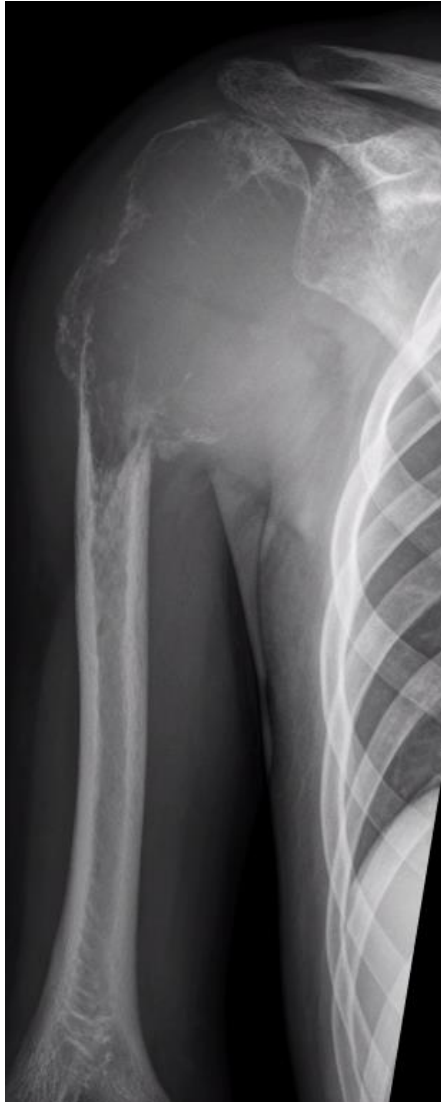
# shoulder; extra-articular; arthrodesis

## Treatment so far:

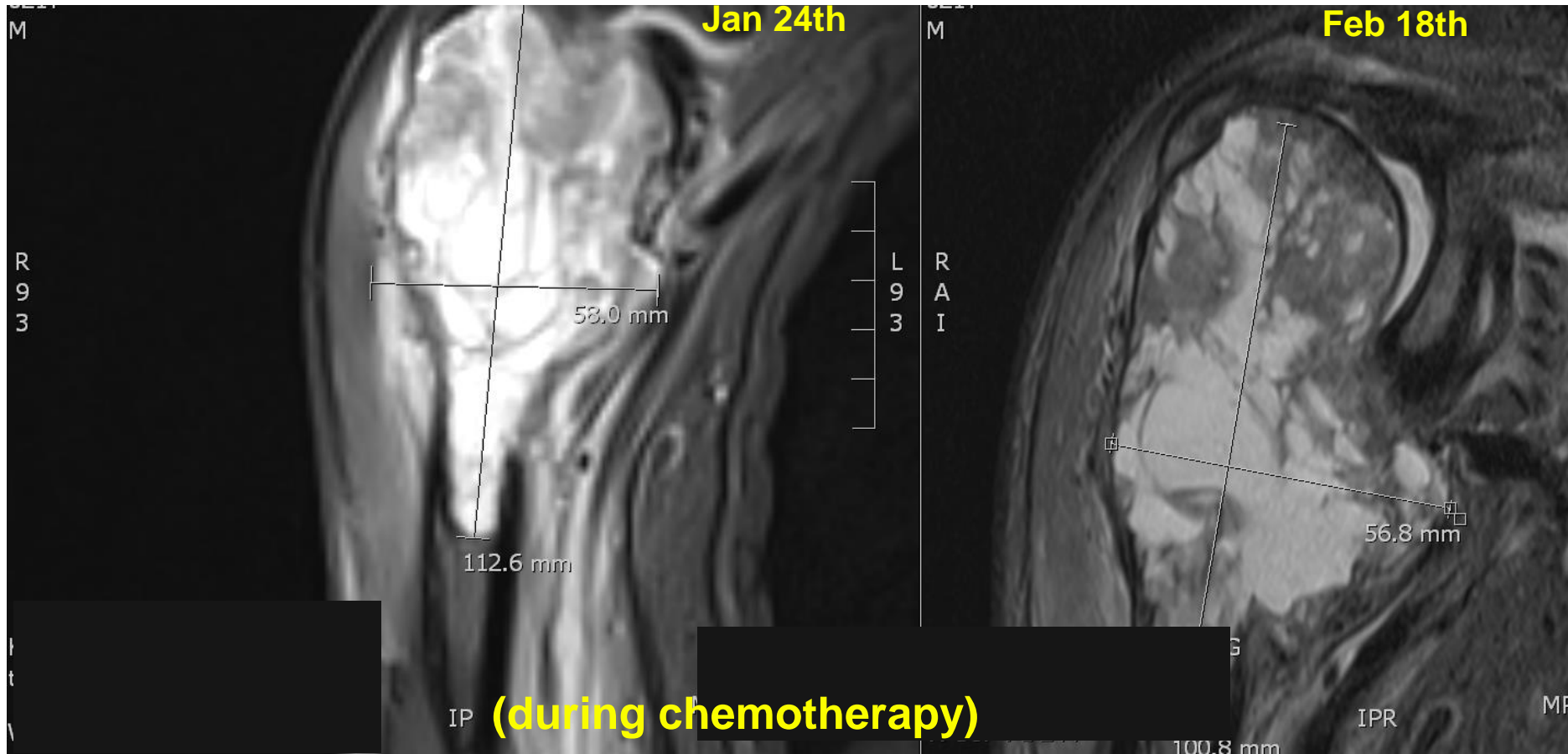
- Jan 10th, 2013: start of chemotherapy EURAMOS (AP)
- Feb 15th 2013: start of 2nd cycle (MAP)

# shoulder; extra-articular; arthrodesis X-Ray : Feb 15th, 2013



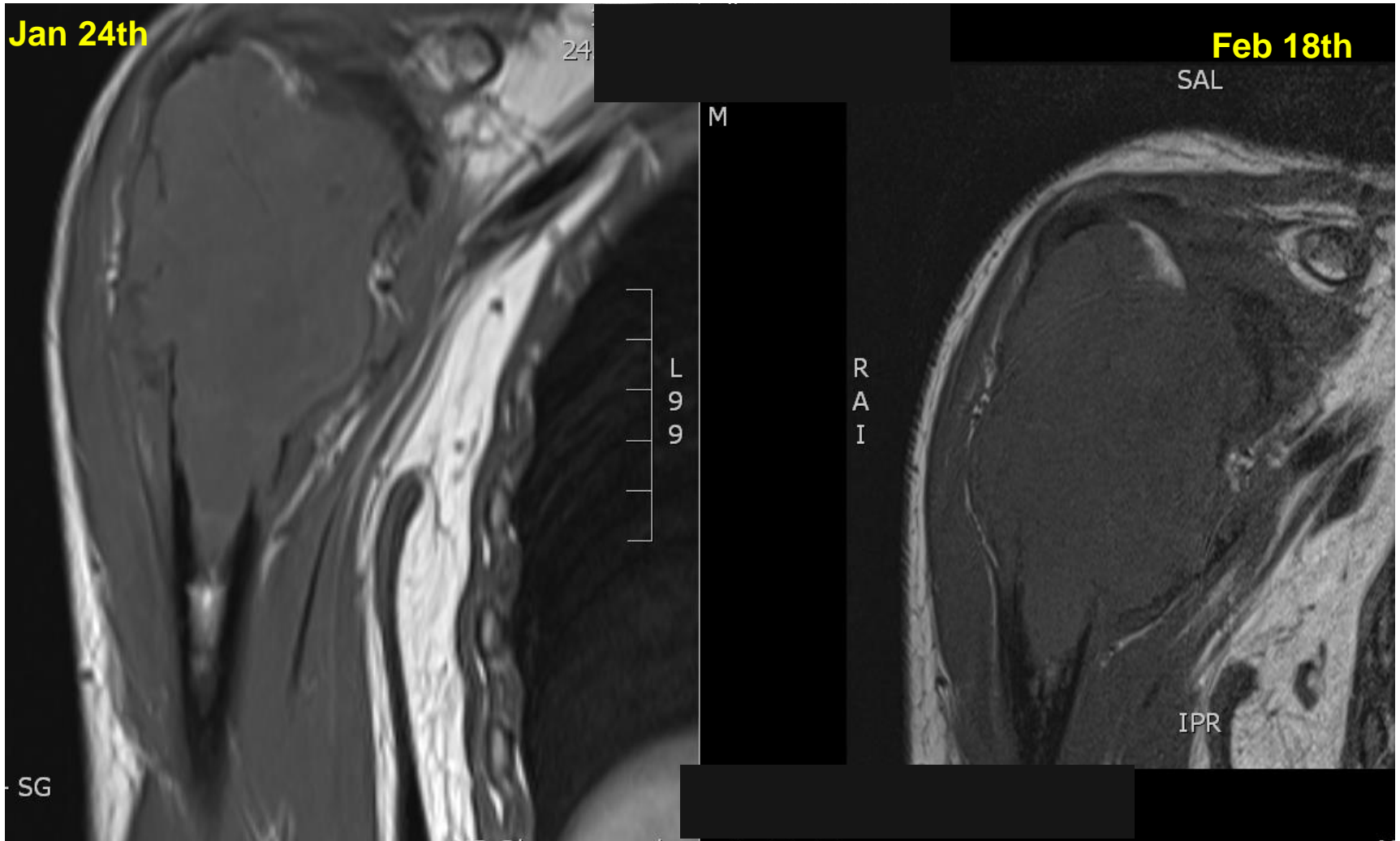
# shoulder; extra-articular; arthrodesis

## MRI : Jan 24th vs. Feb 18th, 2013



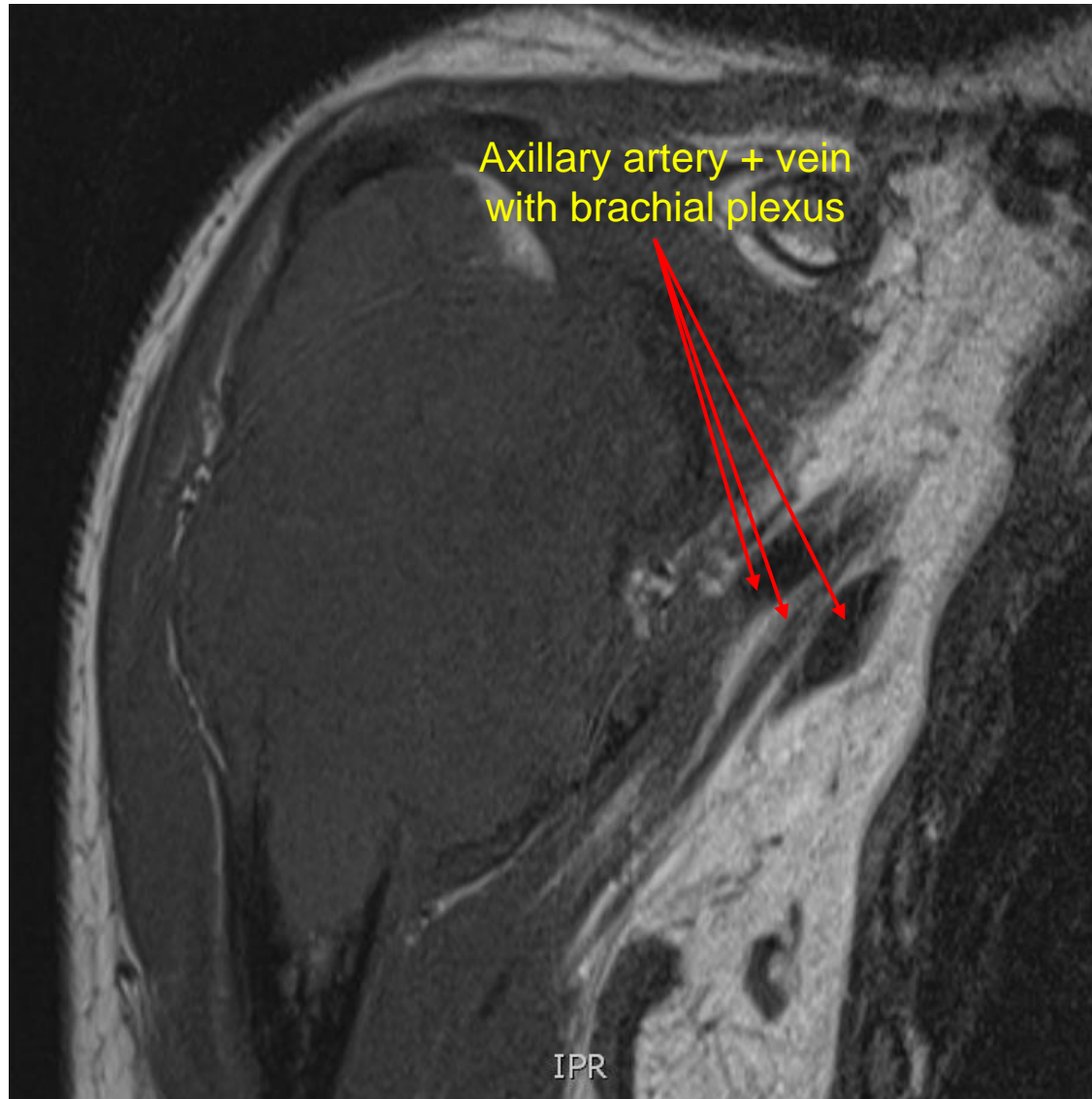
# shoulder; extra-articular; arthrodesis

## MRI : Jan 24th vs. Feb 18th, 2013



# shoulder; extra-articular; arthrodesis

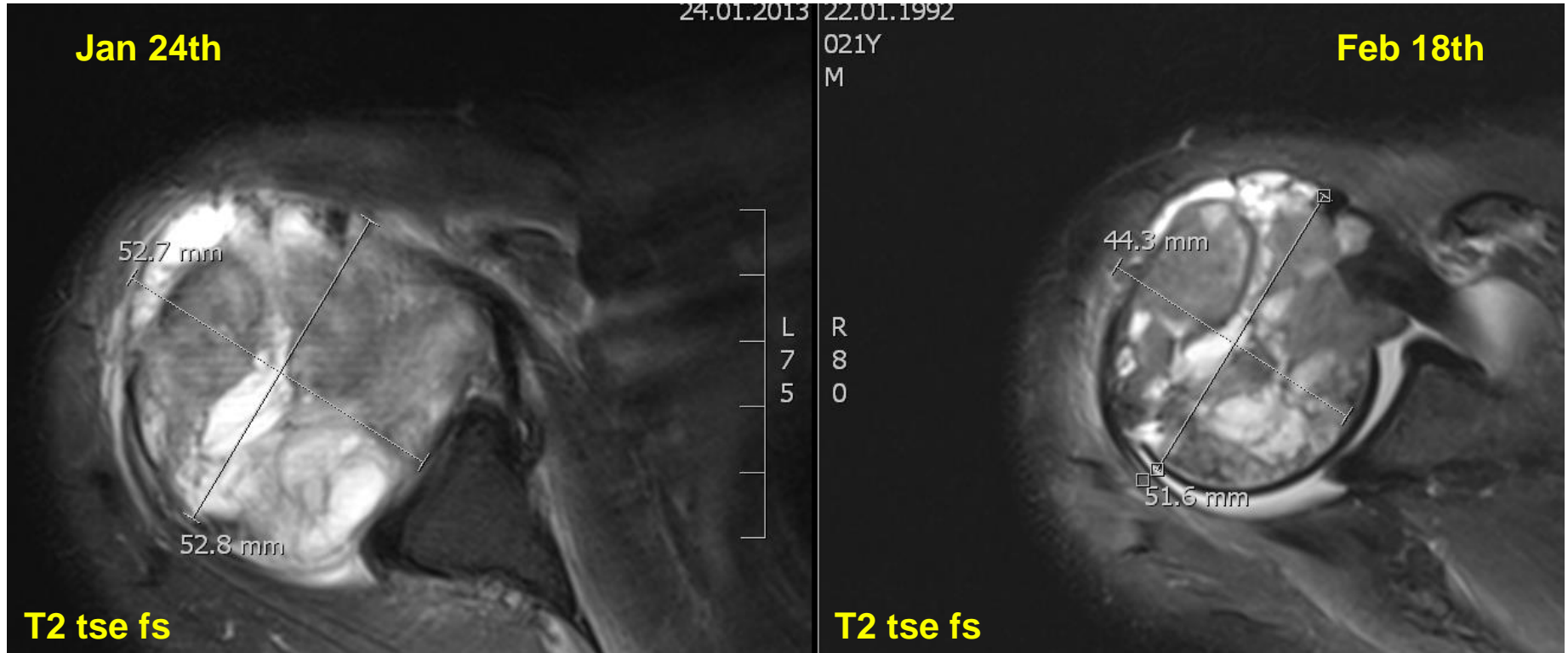
## MRI : Jan 24th vs. Feb 18th, 2013





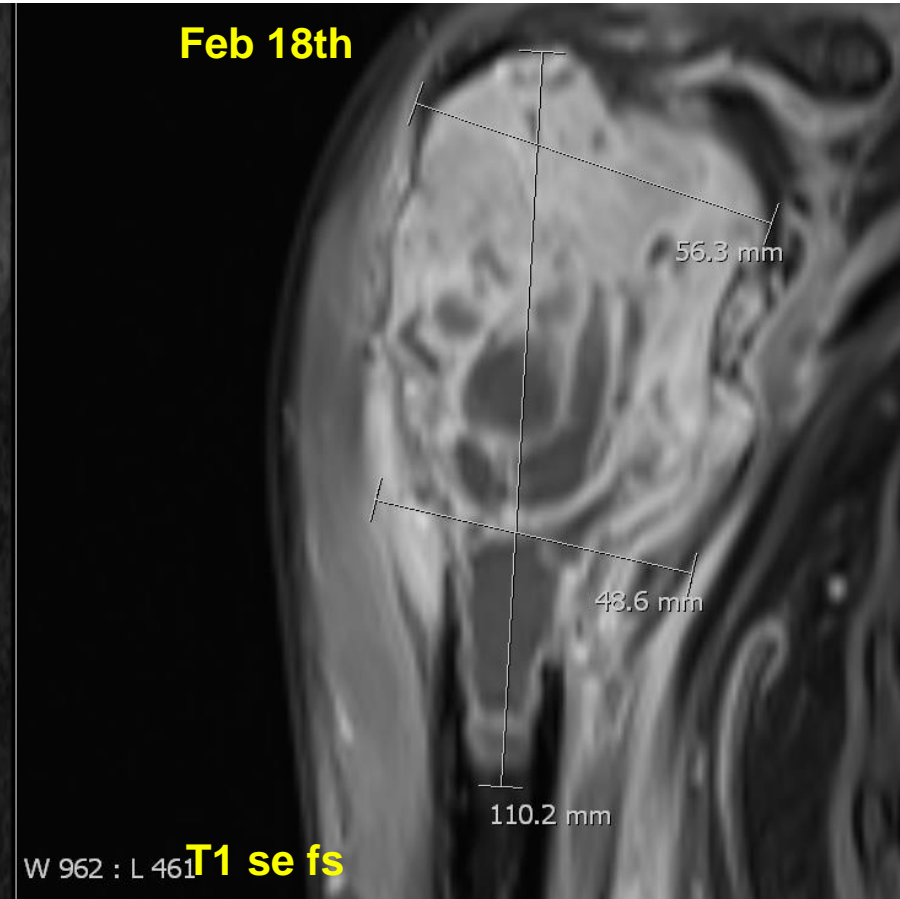
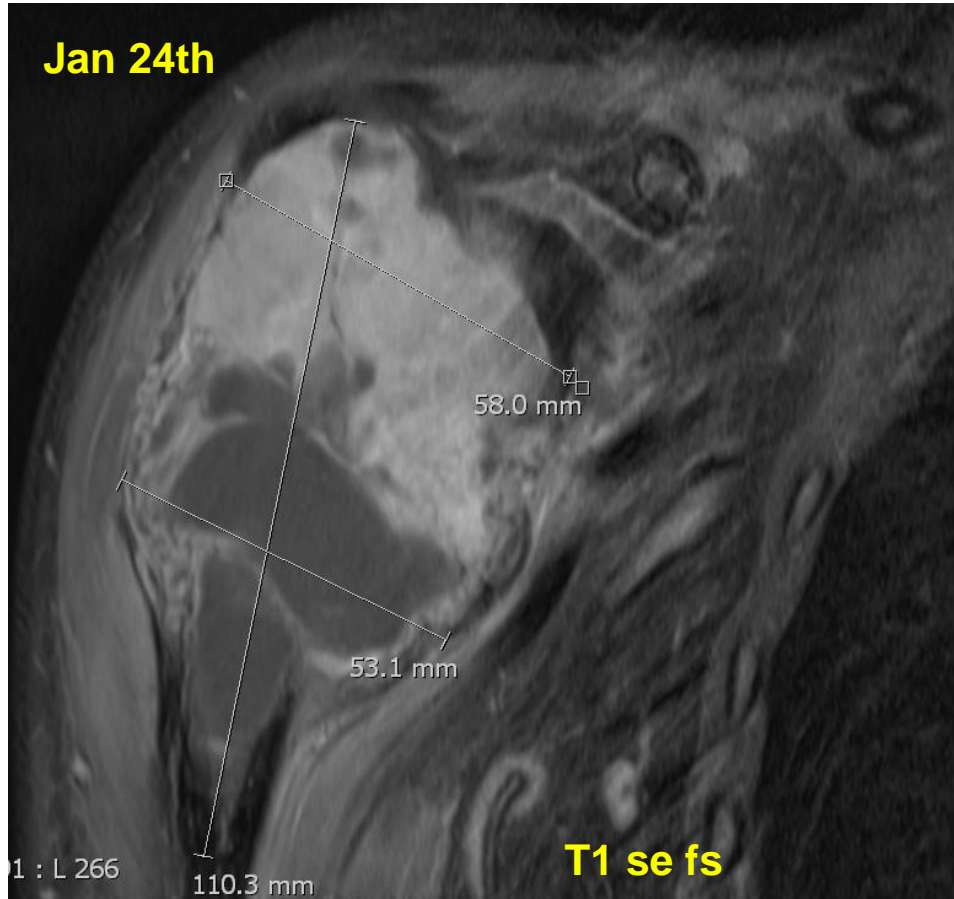
# shoulder; extra-articular; arthrodesis

## MRI : Jan 24th vs. Feb 18th, 2013



# shoulder; extra-articular; arthrodesis

## MRI : Jan 24th vs. Feb 18th, 2013



# shoulder; extra-articular; arthrodesis

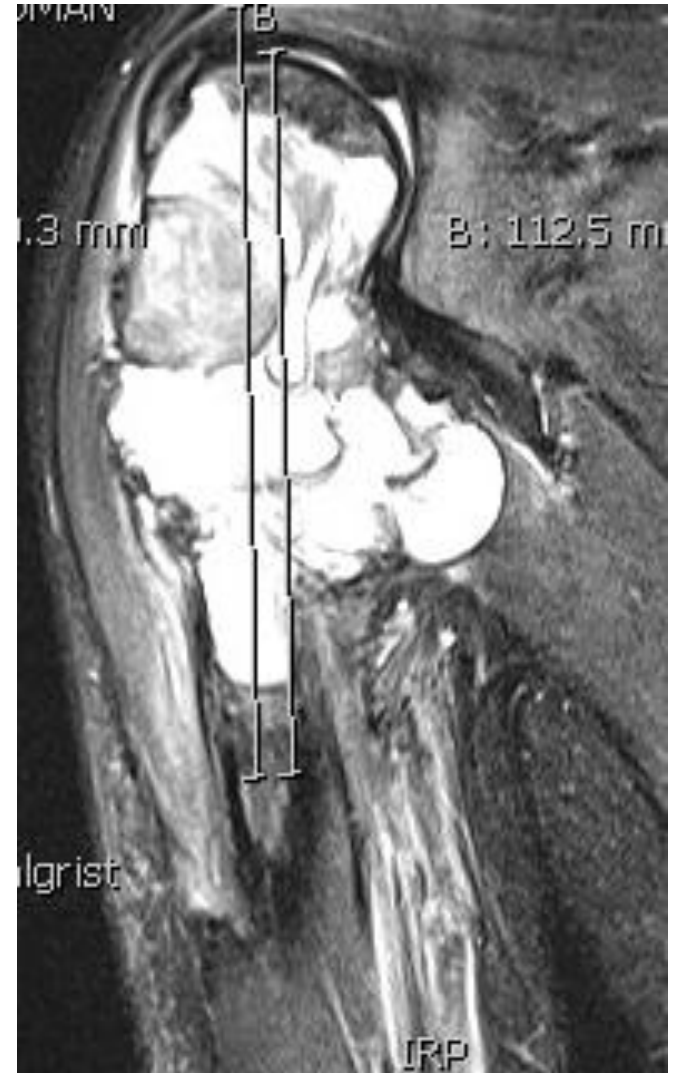
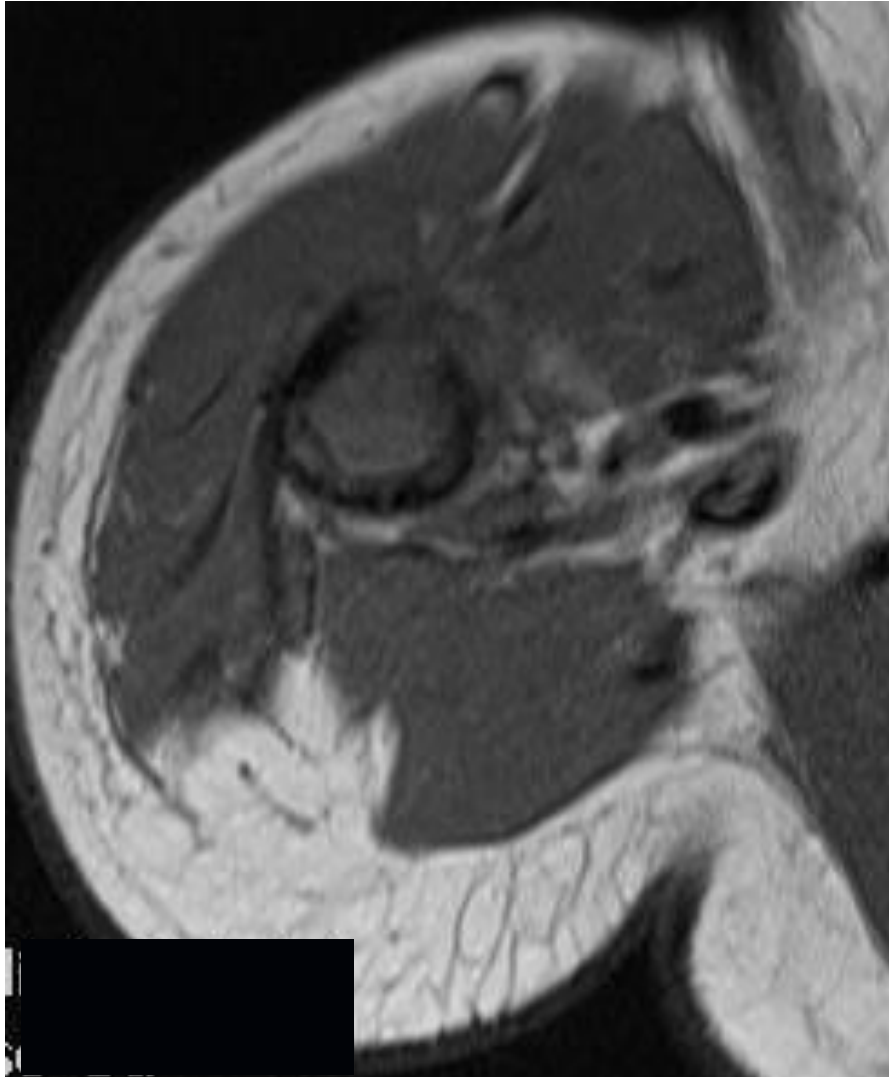## Sarcoma- Board: Feb 28th, 2013

### Therapeutic decisions:

- **Completion of neoadjuvant chemotherapy**
- **Surgery scheduled for March 19th, 2013**

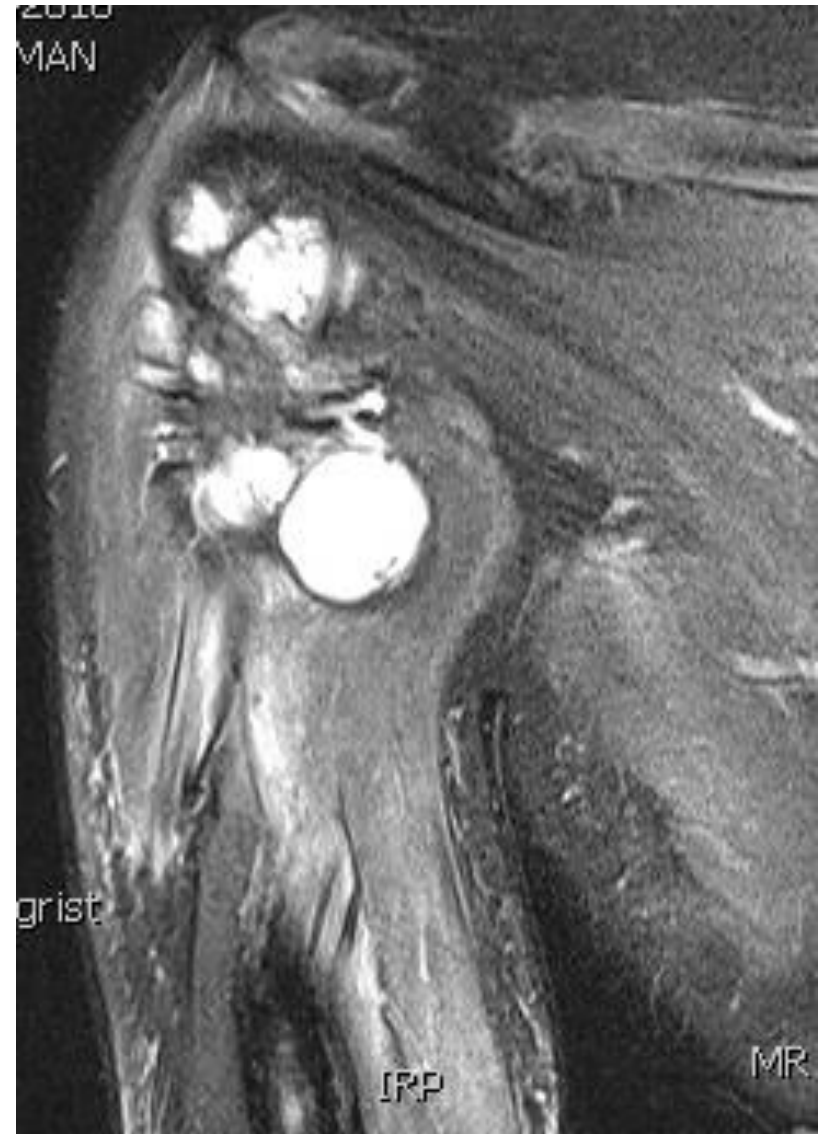
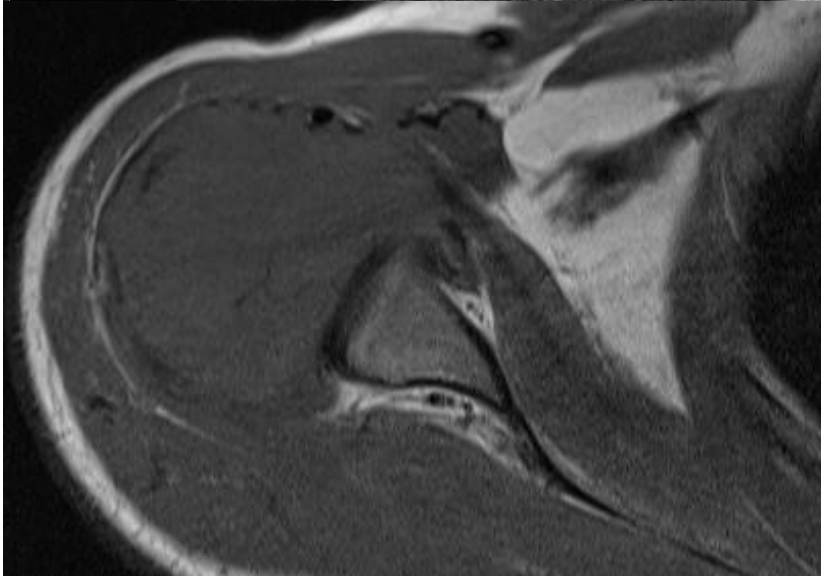
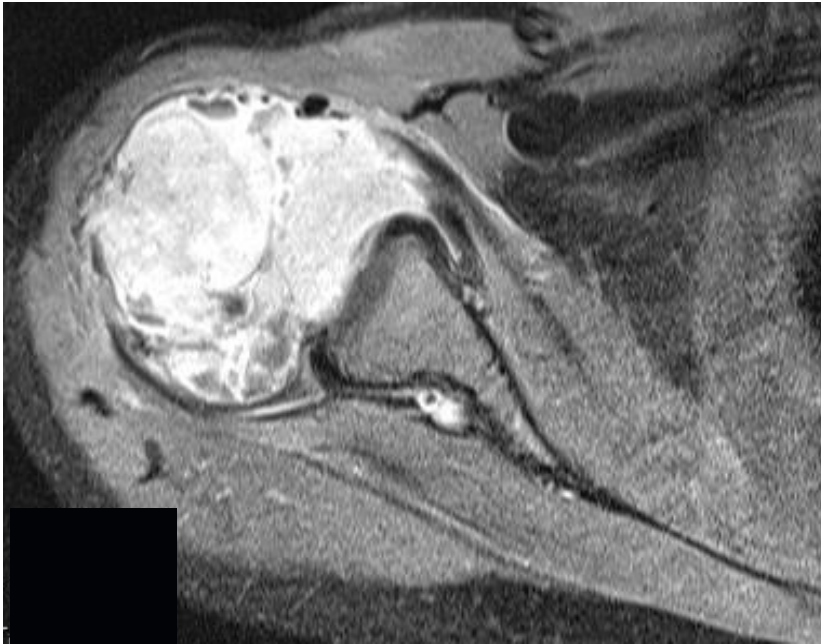
# shoulder; extra-articular; arthrodesis

## MRI: March 18th, 2013

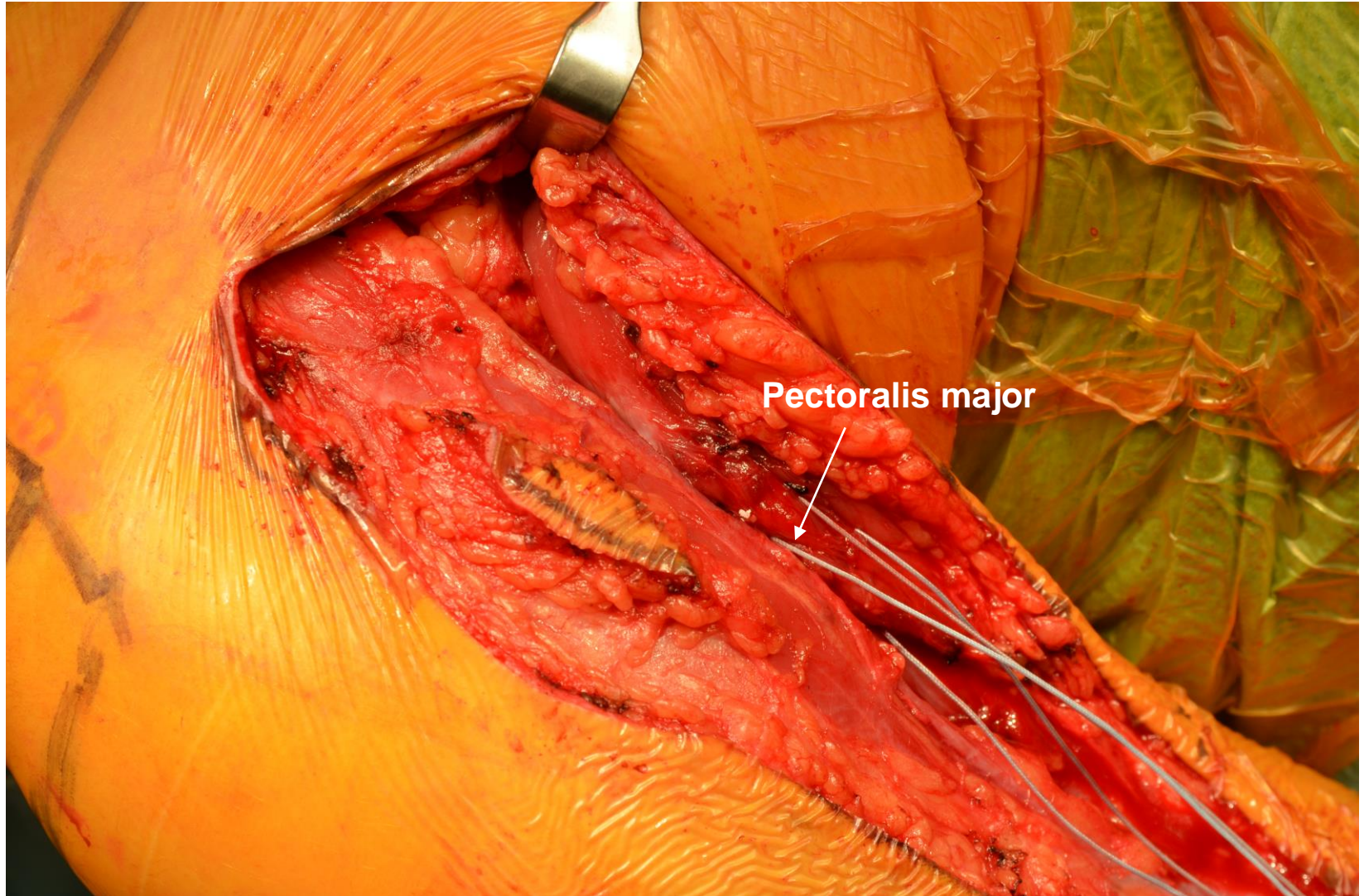


# shoulder; extra-articular; arthrodesis

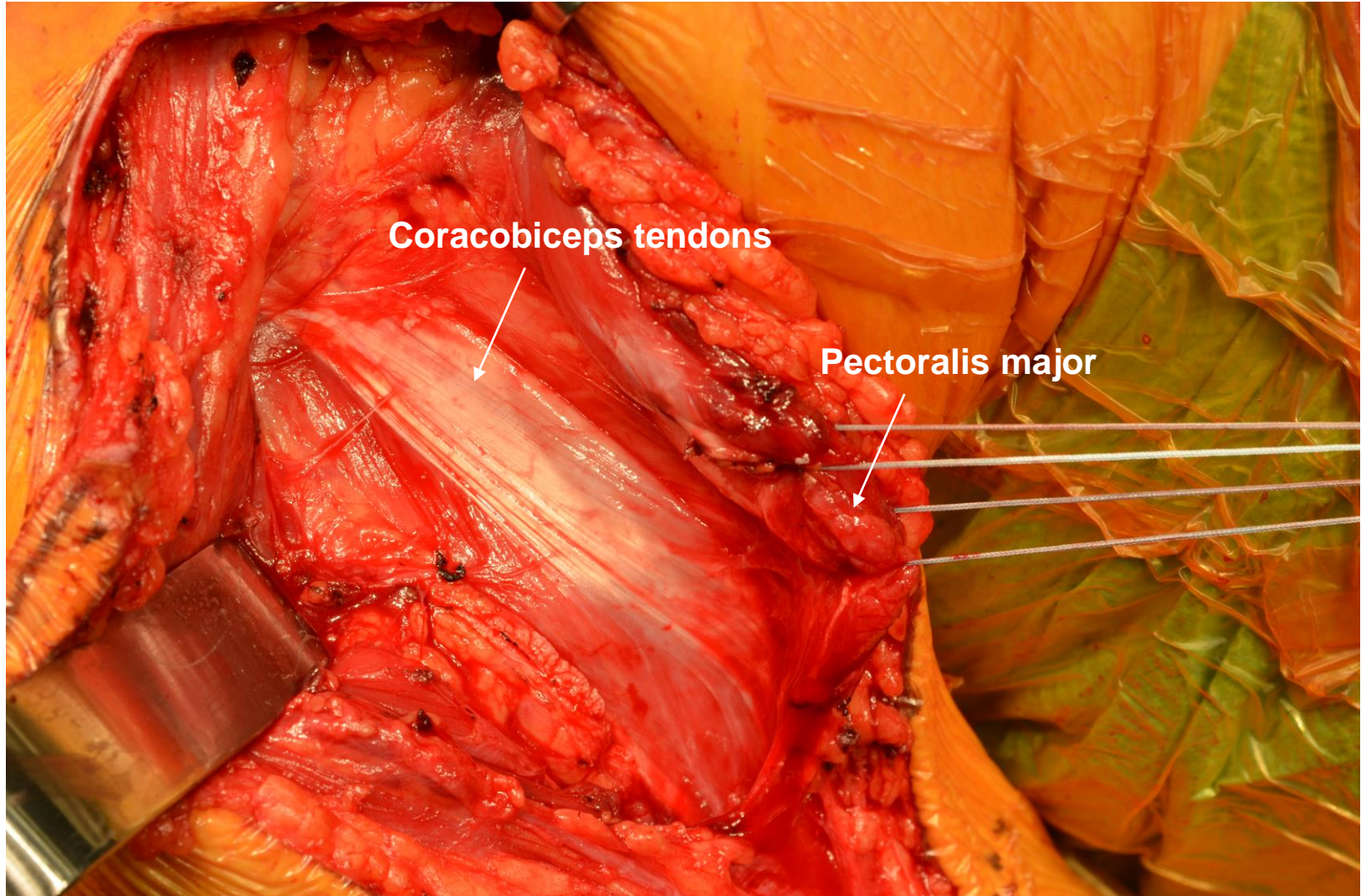
## MRI: March 18th, 2013



# shoulder; extra-articular; arthrodesis Surgery: March 19th, 2013



# shoulder; extra-articular; arthrodesis Surgery: March 19th, 2013



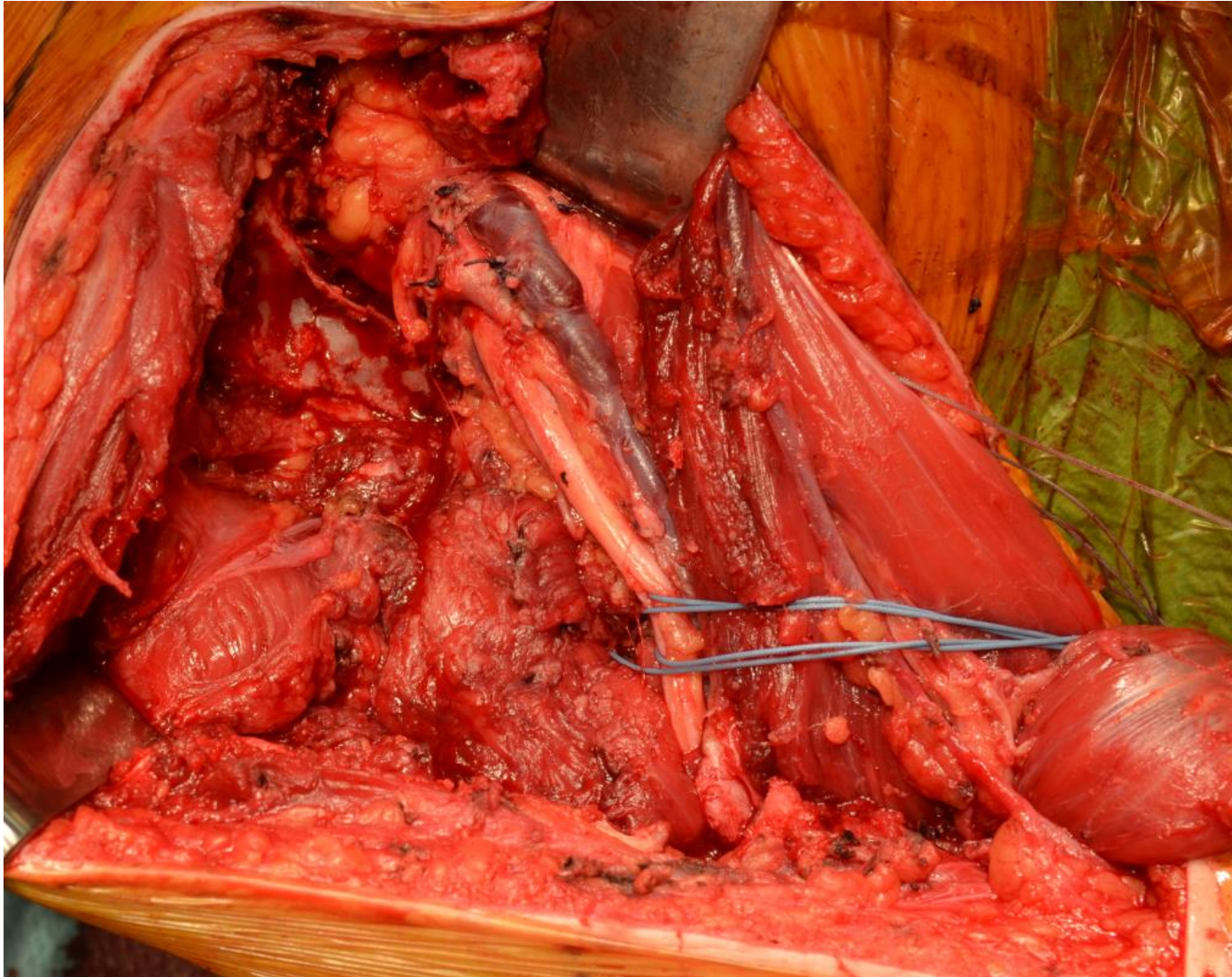
**shoulder; extra-articular; arthrodesis**  
**Surgery: March 19th, 2013**



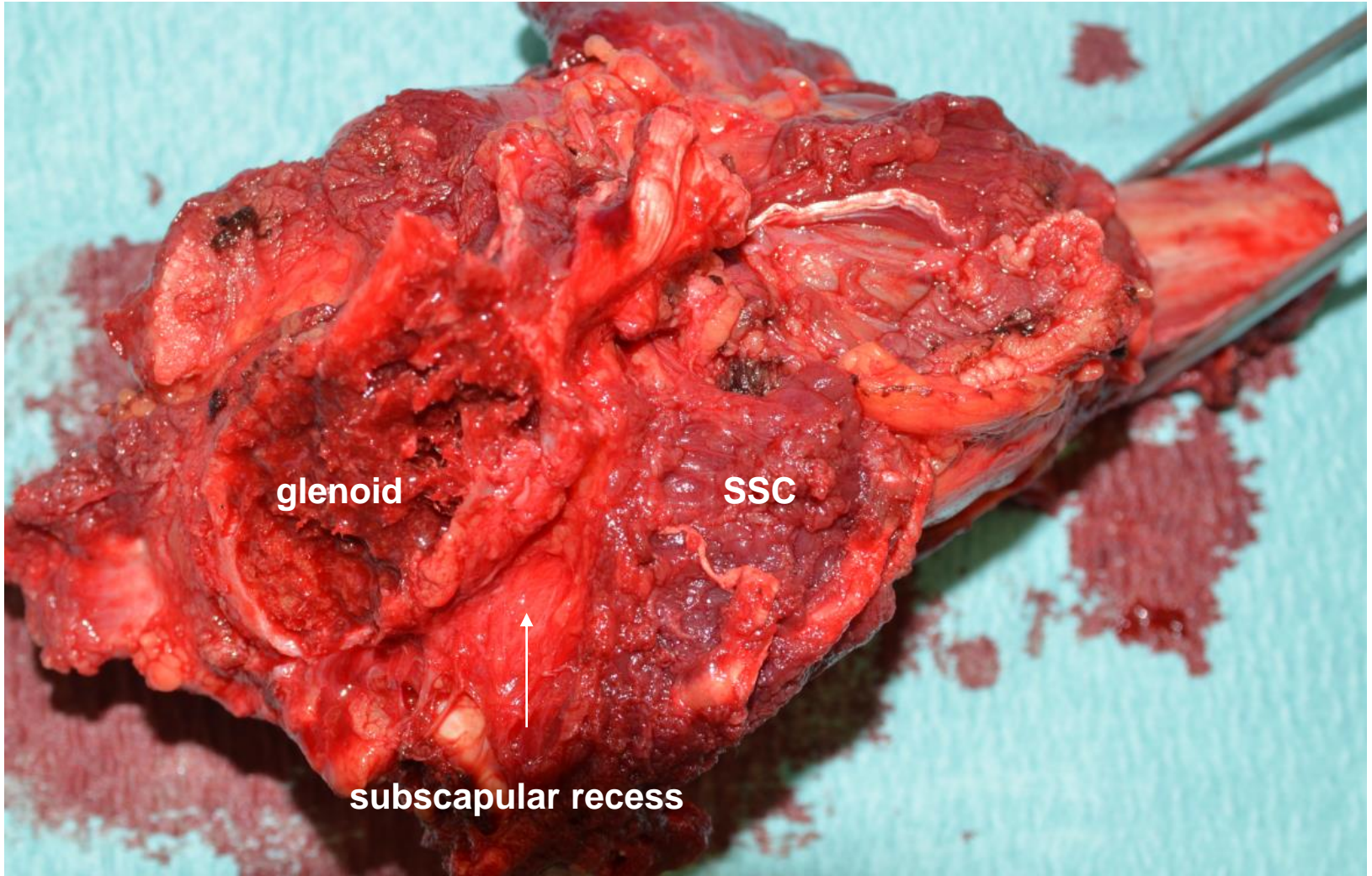
**shoulder; extra-articular; arthrodesis**  
**Surgery: March 19th, 2013**

**shoulder; extra-articular; arthrodesis**  
**Surgery: March 19th, 2013**

# shoulder; extra-articular; arthrodesis Surgery: March 19th, 2013



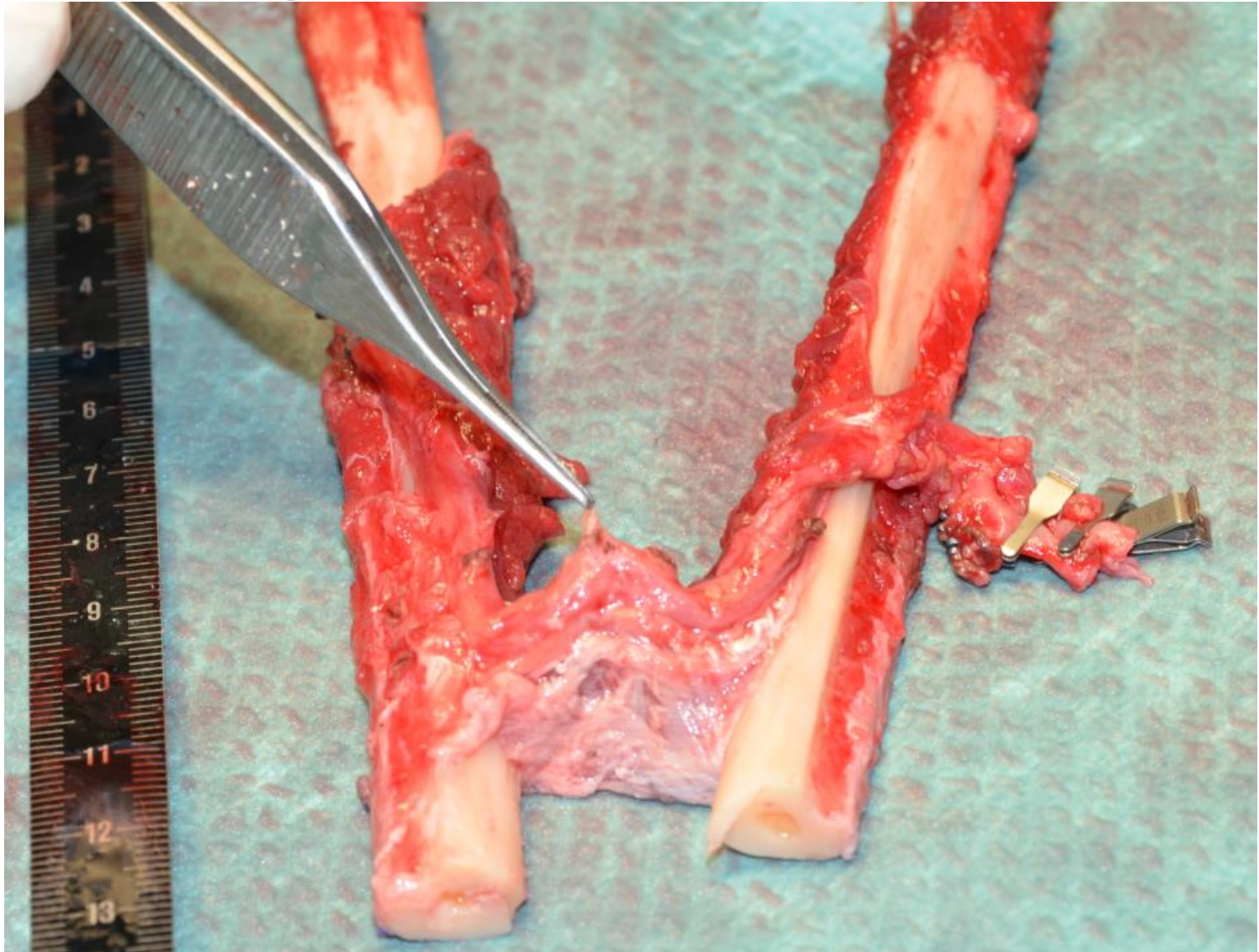
# shoulder; extra-articular; arthrodesis Surgery: March 19th, 2013



**shoulder; extra-articular; arthrodesis**  
**Surgery: March 19th, 2013**

**shoulder; extra-articular; arthrodesis**  
**Surgery: March 19th, 2013**

# shoulder; extra-articular; arthrodesis Surgery: March 19th, 2013

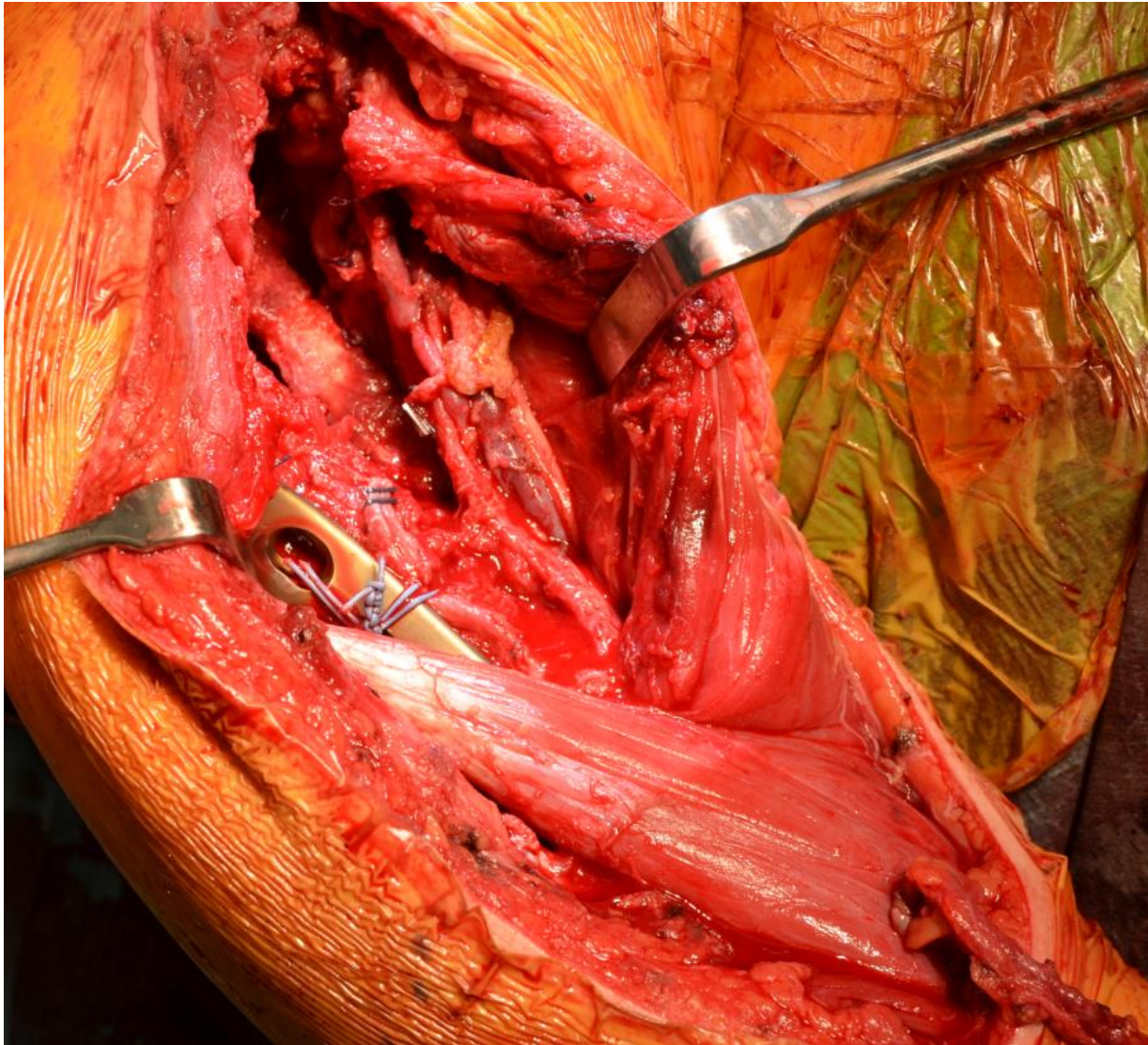


**shoulder; extra-articular; arthrodesis**  
**Surgery: March 19th, 2013**



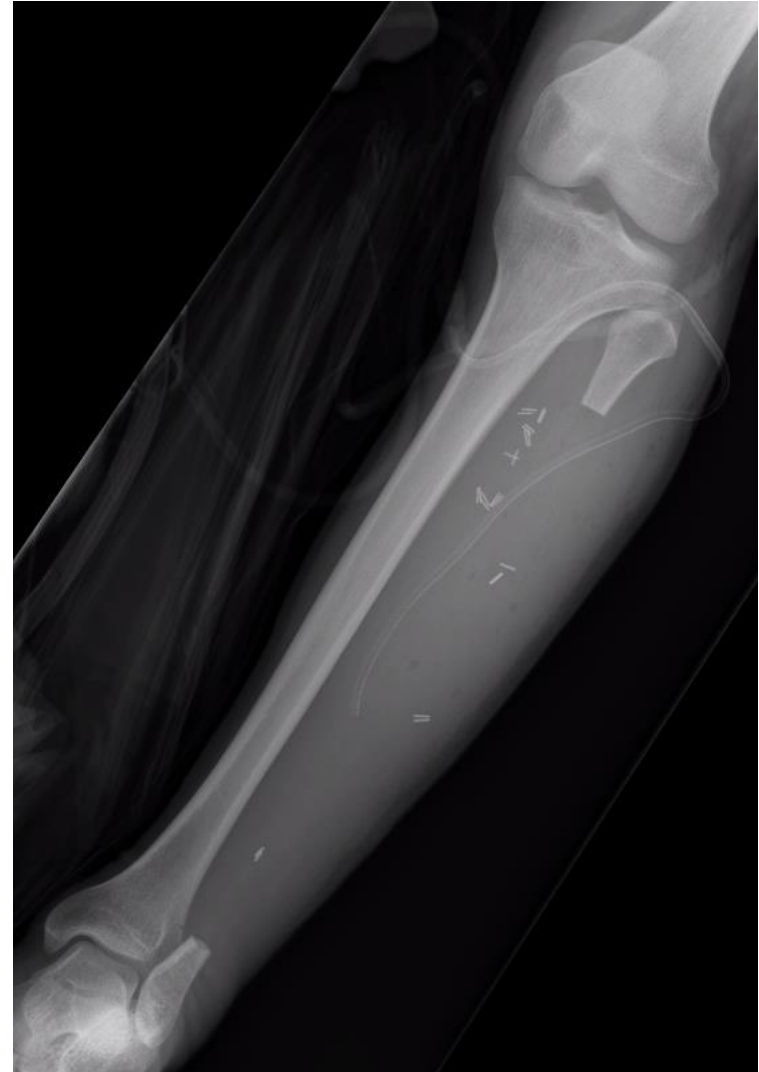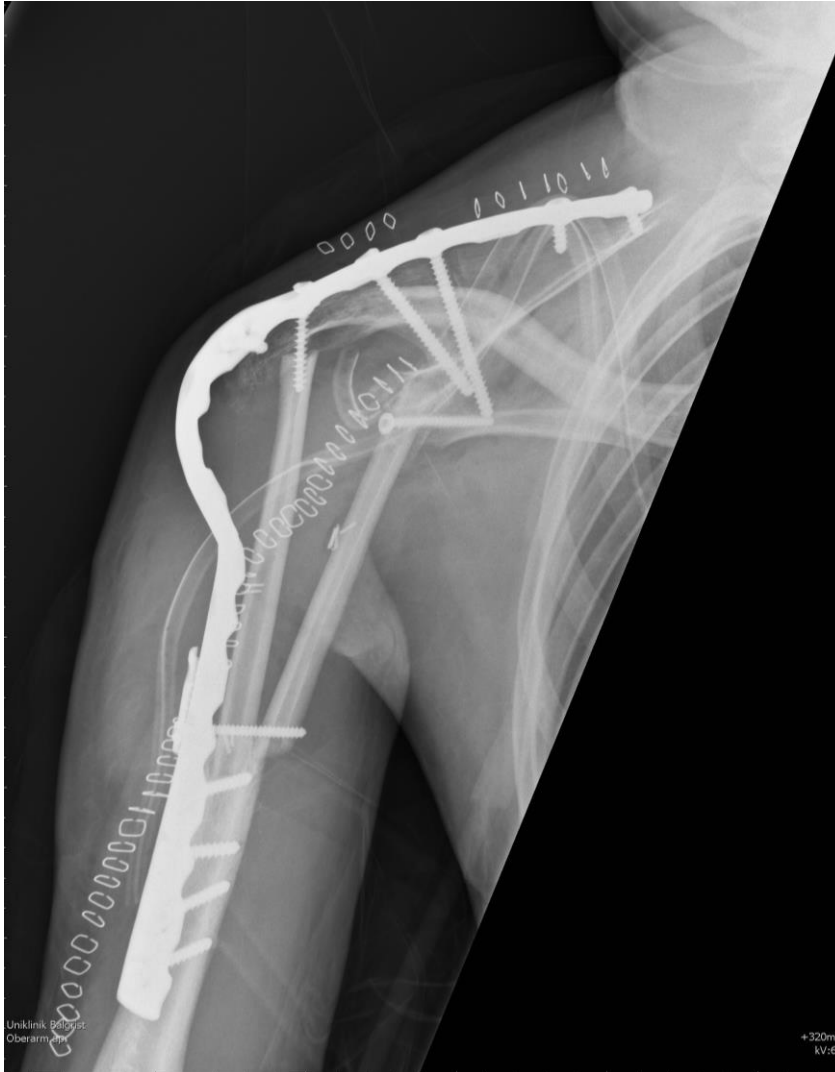**shoulder; extra-articular; arthrodesis**  
**Surgery: March 19th, 2013**

# shoulder; extra-articular; arthrodesis Surgery: March 19th, 2013



# shoulder; extra-articular; arthrodesis

## Postop X-Ray: March 19th, 2013



**shoulder; extra-articular; arthrodesis**

**Result: Surgery: March 19th, 2013**

**shoulder; extra-articular; arthrodesis**

**Result: Surgery: March 19th, 2013**

**shoulder; extra-articular; arthrodesis**

**Result: Surgery: March 19th, 2013**

**shoulder; extra-articular; arthrodesis**  
**Result: Surgery: March 19th, 2013**

**shoulder; extra-articular; arthrodesis**

**Result: Surgery: March 19th, 2013**



**shoulder; extra-articular; arthrodesis**

**Result: Surgery: March 19th, 2013**

# shoulder; extra-articular; arthrodesis

## Result: Surgery: March 19th, 2013

### Definitiver Bericht (inkl. Beurteilung des ossären Resektatrandes)

#### *Diagnose*

Proximales Humerusteilresektat von rechts: Intraossäres Osteosarkom high grade der Metaphyse bei Status nach neoadjuvanter Chemotherapie. 60-70% vitaler Tumoranteil (Grad V nach Salzer-Kuntschik; Non-Responder). Maximaler Tumordurchmesser 8,5 cm. Durchbruch durch den Gelenkknorpel. Durchbruch in das angrenzende Weichteilgewebe: Am medialen, gelenksnahen Präparatrand reicht der Tumor über eine Strecke von 2 mm unmittelbar an den zirkumferentiellen Präparatrand heran. Kein Tumornachweis an den übrigen zirkumferentiellen Präparaträndern und an den intraossären Resektaträndern: Mindestabstand nach dorsal 2 mm, nach lateral 4 mm und nach ventral 7 mm. Tumorfreier Stichkanal. Vgl. Kommentar.

#### *Kommentar*

Die Schnittpräparate zum ossären Resektatrand konnten nach Entkalkung nun ebenfalls untersucht werden, es lässt sich kein Tumor in den ossären (intraossär Humerus und Skapula) nachweisen.

# shoulder; extra-articular; arthrodesis

21 yo farmer

25 September 2013

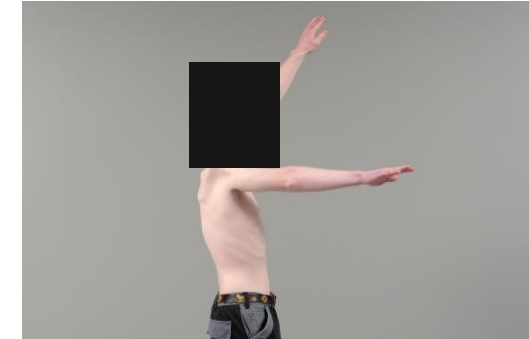
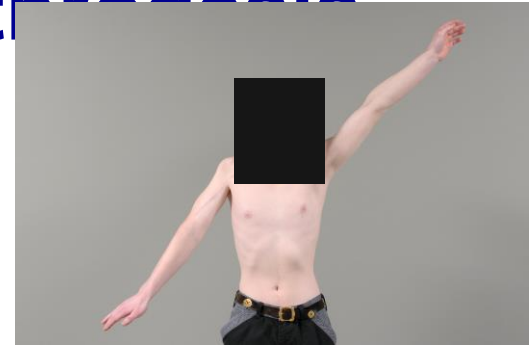



Feb 2013

# shoulder; extra-articular; arthrodesis



21 yo farmer

05 February 2014



# shoulder; extra-articular; arthrodesis

26. Februar 2014



# shoulder; extra-articular; arthrodesis

28 February 2014

## Tragic work accident

### In the field:

patient gets squeezed

between tractor and

cranne